

# Radiological Evaluation of the Proximal Femoral Geometric Features in the Turkish Population

## Türk Toplumunda Proksimal Femurun Geometrik Özelliklerinin Radyolojik Değerlendirilmesi

\* Nihat ACAR  
\*\* Abdullah Meriç ÜNAL

\* Ortopedi ve Travmatoloji A.D.  
Çatalca İlyas Çokay Hastanesi  
İSTANBUL

\*\* Süleyman Demirel Üniversitesi  
Tıp Fakültesi Spor Hekimliği  
Anabilim Dalı ISPARTA

### Öz

**Amaç:** Bu çalışmanın amacı cerrahlar ve implant imalatçıları için bir veri tabanı oluşturmak gayesi ile Türk toplumunda proksimal femur geometrisinin farklı özelliklerini değerlendirmektir. **Gereç ve yöntem:** 40- 80 yaş arasındaki 380 (190 erkek, 190 kadın) hastanın doğru pelvis ön-arka dijital görüntüleri elde edildi. Femur başı çapı, horizontal offset, boyun şaft açısı, femur boynu genişliği, boynu uzunluğu ve femur boynu eksen uzunluğu ölçüldü. **Bulgular:** Her iki cinsiyette de, femur başı çapı ve kalçanın horizontal ofsetinde sağ ve sol kalçalar arasında anlamlı fark saptandı. Femur boyun-şaft açısı, femur boyun genişliği, femur boyun uzunluğu ve femur boyun aks uzunluğu ölçümlerinde ise sağ ve sol kalçalar arasında anlamlı fark saptanmadı. **Sonuç:** Genellikle erkeklerde kadınlara göre daha yüksek değerler saptandı. Proksimal femur cerrahisi ile uğraşan cerrahlar ve implant imalatçıları için bu çalışma bir veri tabanı hizmeti sunabilir.

**Anahtar Kelimeler:** Proksimal femur geometrisi; Türk toplumu; Proksimal femur cerrahisi, Femur boyun açısı

### Abstract

**Objective:** The aim of this study is to assess different features of the proximal femoral geometry of the Turkish population to build a database for surgeons and implant manufacturers. **Methods:** Antero-posterior pelvic radiograms of 380 (190 male, 190 female), 40-80 year old patients were reviewed retrospectively. The femoral head diameter, horizontal offset, neck shaft angle, femoral neck width, femoral neck length and the femoral axis length were measured. **Results:** In males, there was statistically significant difference between right and left hips at femoral head diameters and horizontal offset of hip ( $p=0.005$ ,  $p=0.04$ ). In females, there was statistically significant difference between right and left hip at femoral head diameter but not at horizontal offset ( $p=0.02$ ,  $p=0.09$ ). No significant difference was detected at the measurements of neck-shaft angle, femoral neck width, femoral neck length and femoral neck axis length. **Conclusion:** In male population, when all parameters evaluated, most of the time, in all parameters higher average values found than the female population. This study may offer a data base for surgeons and manufacturers who deal with proximal femoral bone surgery.

**Keywords:** Proximal femoral geometry; Turkish population; proximal femoral surgery, femoral neck angle

### Yazışma Adresi:

Nihat Acar  
Catalca Ilyas Çokay Hospital,  
Orthopaedics and Traumatology  
Department, Catalca,  
Istanbul, Turkey  
zenanacar@gmail.com

## Introduction

Proximal hip surgeries including trauma and hip arthroplasty procedures have been increased tremendously in the last ten years all over the world. More than 250.000 hip fractures occur annually in the United States and this number will double within the next 30 years (1). Proximal femoral fractures most of the time require surgery. For a good proximal femoral surgery, computerized tomography or radiographs can be used for preoperative planning to match the preplanned internal fixation devices (DHS and PFN) and prosthesis with that of the proximal femoral geometry in order to restore the normal hip biomechanics. A large proportion of the implants usually supplied by the manufacturers are in standard sizes. If the used prosthesis or fixation implants do not match the proximal femoral geometry, then improper load distribution will result in great patient discomfort and aseptic loosening (1, 2). As a result of this fact, a consensus has been reached among many surgeons that close adaptation of prosthesis and the internal fixation implants to the proximal femoral bone geometry is necessary to achieve an optimal primary stability and secondary biologic fixation (3, 4). Many studies have been conducted using computerized tomography and radiography on dry bone on the proximal femoral geometry, showed substantial variations in these parameters among populations of different geographic regions (5, 6). Especially in Japanese population smaller values were found(6).

Noble et al. (7) demonstrated the presence of both endosteal and periosteal variation, and the need for multiple stem designs to achieve close fit. Nelson & Megyesi studied sex and ethnic differences in bone architecture and therefore established the need for developing gender-specific implants (8). Females may need more smaller femoral designs.

Different ethnic populations have different femoral configurations. There are also major differences between both genders. Different ethnic populations and different genders all need different types of orthopaedic femoral implant designs. The aim of this study is to provide a data base for surgeons and manufacturers regarding the proximal femoral geometry for the Turkish population by means of digital radiographic evaluation.

## Patients and Methods

This study was approved by the ethical committee at 07/05/2015 with a protocol number of 2070-GOA and decision number 2015/12-34. A retrospective study was

conducted reviewing the true pelvis antero posterior (AP) radiographies obtained within the last 5 years from the radiology department for patients between 40-80 years of age. Out of more than one thousand pelvis AP views, the true AP pelvis views of 380 patients composed of 190 men and 190 women were studied. The inclusion criteria in this study were as follows: True AP views for patients with no hip disorders, no previous hip surgery, no previous hip fracture history and any infectious lesion. Whereas patients without true AP pelvis views, with hip deformity, rheumatoid arthritis, osteoarthritis and osteonecrosis of the femoral head were excluded from this study.

Only true pelvis AP views were included in this study. For a standard pelvis AP view to be obtained, a standard pelvis positioning protocol was followed in our radiology department with the beam of the X-ray directed toward the midline above the symphysis pubis and both lower extremities were in 15° of internal rotation. All radiograms were taken using the same standard radiographic positioning using the same radiographic machine (Philips Medical Systems, Digital Diagnost). All measurements were performed by an expert orthopaedic surgeon on hip surgery.

The proximal femoral geometric parameters assessed were as the following:

**Femoral head diameter (FHD):** Which is the diameter of a complete circle drawn around the femoral head (Fig 1).

**The horizontal offset (HO):** Which is the distance between the hip joint center of rotation and the continuation of the line of the femoral shaft axis (Fig 1).

**The neck-shaft angle (NSA):** Which is an angle formed by the intersection of the neck axis line and the femoral shaft anatomical axis line (Fig 1).

**The femoral neck width (FNW):** Which is the mid-point distance between the superior cortex and the inferior cortex of the femoral neck perpendicular to the femoral neck axis (Fig 2).

**The femoral neck length (FNL):** Which is the distance between the lateral margin of the femoral head and the superior base of the trochanteric region (Fig 2).

**The femoral axis length (FAL):** Which is the straight-line distance between the extremities of the greater trochanter and femoral head in the sagittal plane (Fig 2).

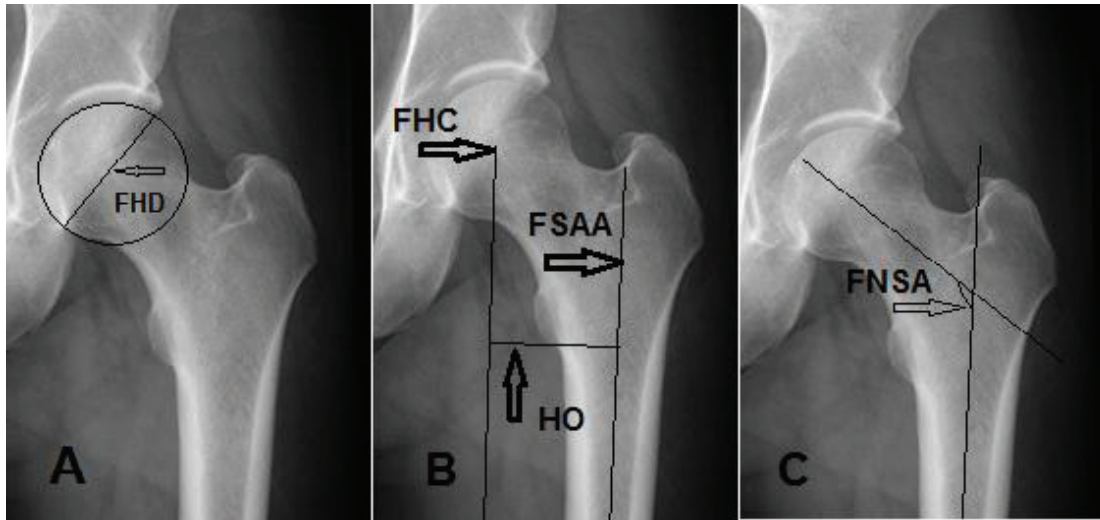


Figure 1: A; Femoral head diameter (FHD), Which is the diameter of a complete circle drawn around the femoral head. B; The horizontal offset (HO), which is the distance between the hip head center (FHC) of rotation and the continuation of the line of the femoral shaft anatomical axis (FSAA). C; the femoral neck-shaft angle (FNSA), which is an angle formed by the intersection of the neck axis line and the femoral shaft anatomical axis line.

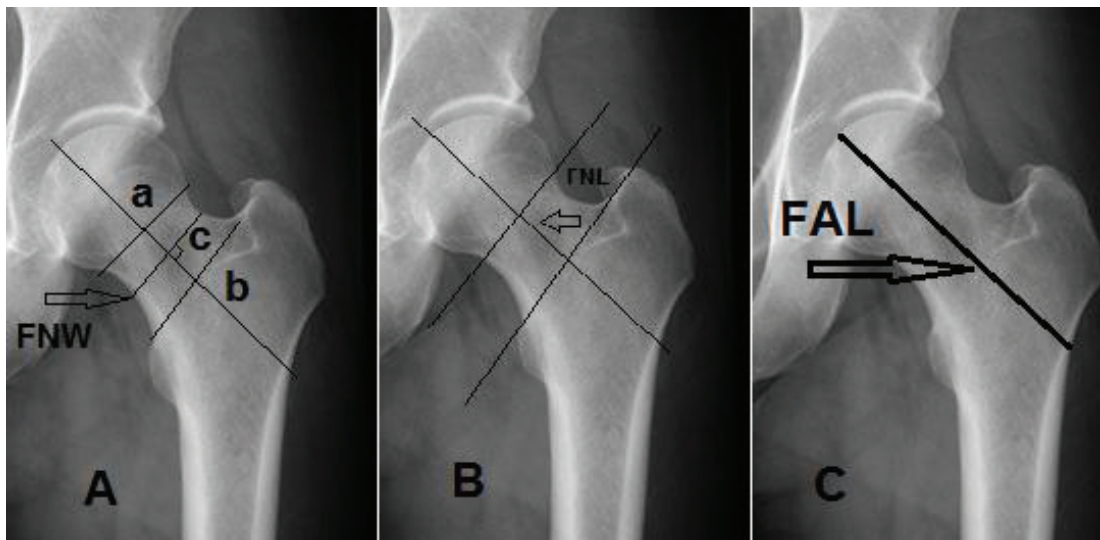


Figure 2 : A; The femoral neck width (FNW), which is the mid-point distance between the superior cortex (a) and the inferior cortex (b) of the femoral neck perpendicular to the femoral neck axis (c). B; The femoral neck length (FNL), which is the distance between the lateral margin of the femoral head and the superior base of the trochanteric region. C; The femoral axis length (FAL), which is the straight-line distance between the extremities of the greater trochanter and femoral head in the sagittal plane.

For the statistical analysis the Unpaired Student T-test was conducted to compare between genders and both right and left proximal femurs' geometric features. Statistical significance level was set at  $p < 0.05$ .

## Results

We compared each genders' right and left proximal femoral geometry measured mean values, then the general proximal femoral geometry mean values of both genders were compared to each other and the mean values of the general right and left proximal femurs in both genders were compared (table 1-4).

Analyzing the data revealed that, the mean values of the femoral head diameter (FHD) of the right and the left hips, statistical significance was detected between both sides ( $p=0.017$ ), whereas in the male population, a statistical significance was also detected between both sides ( $p= 0.005$ ). Mean value of female FHD was smaller than the general mean value of male FHD. A significant

statistical difference was detected between the general FHD values of both genders ( $p = 0.000$ ). The general mean values of right and left FHD in both genders were statistical significant between both sides in general ( $p= 0.001$ ).

In the comparison of horizontal offset (HO) of the right and the left hips in the female population were not statistical significant ( $p=0.097$ ), whereas in the male population a statistical significance was detected between both sides ( $p= 0.046$ ). However the general mean value of female HO was significantly smaller than male group ( $p = 0.000$ ). For the general mean values, statistical significance was detected between both sides in general ( $p= 0.04$ ).

In comparison of the neck shaft angle (NSA) of the right and the left hips no statistical significance was detected between both sides ( $p=0.095$ ), in the male population there was also no statistical significance was detected between both sides ( $p= 0.48$ ). No significant statistical difference was detected between the general NSA of both genders with  $p = 0.075$ .

Table 1

Demonstration of the radiological measurements of different features of the proximal femoral geometry of both sides of both genders in general in the Turkish population.

Parameters	Both sides	Right	Left	P value between right and left
Mean±SD (Min.-Max.)	(average)			
Femoral head diameter (mm)	47.13±3.36 (39.2-57.8)	47.53±3.46 (39.5-57.8)	46.74±3.42 (39.2-56.1)	P=0.001
Horizontal offset (mm)	41.11±5.28 (29.6-62.2)	41.48±5.41 (29.8-62.2)	40.72±5.14 (29.6-61.9)	P=0.04
Neck shaft angle (NSA) (°)	129.71±4.37 (117.5-145.5)	129.85±4.41 (117.5-145.5)	129.57±4.34 (118.0-143.8)	P=0.38
Femoral neck Width (mm)	38.21±4.89 (26.2-49.2)	38.47±4.96 (26.8-49.2)	37.93±4.82 (26.2-49.1)	P=0.11
Femoral neck Length (mm)	34.56±4.74 (24.3-48.3)	34.85±4.73 (25.9-48.3)	34.28±4.74 (24.3-47.0)	P=0.09
Femoral axis Length (mm)	109.71±9.74 (87.1-135.2)	110.37±9.67 (88.6-135.2)	109.03±9.78 (87.1-134.7)	P=0.051

## Radiological Evaluation of the Proximal Femoral Geometric Features in the Turkish Population

**Table 2**

Demonstration of the radiological measurements of different features of the proximal femoral geometry of male Turkish population.

Parameters Mean±SD (Min.-Max.)	Right	Left	P value between right and left
<b>Femoral head diameter (mm)</b>	48.44±3.69 (41.22-57.8)	47.49±3.68 (40.7-56.1)	P=0.005
<b>Horizontal offset (mm)</b>	42.74±5.21 (32.7-62.2)	41.88±5.01 (33.7-61.9)	P=0.046
<b>Neck shaft angle (NSA)(°)</b>	130.30±4.35 (119.3-144.8)	130.32±4.42 (120.3-143.6)	P=0.048
<b>Femoral neck Width (mm)</b>	42.27±3.31 (32.5-49.2)	41.57±3.13 (32.3-49.1)	P=0.015
<b>Femoral neck Length (mm)</b>	36.21±4.21 (27.2-48.2)	35.72±4.32 (26.3-46.9)	P=0.13
<b>Femoral axis Length (mm)</b>	116.26±7.61 (98.5-135.2)	115.10±7.68 (99.3-134.7)	P=0.06

**Table 3**

Demonstration of the radiological measurements of different features of the proximal femoral geometry in both sides in female Turkish population.

Parameters Mean±SD (Min.-Max.)	Right	Left	P value between right and left
<b>Femoral head diameter (mm)</b>	46.61±2.96 (39.5-53.3)	45.99±2.97 (39.2-53.0)	P=0.017
<b>Horizontal offset (mm)</b>	40.22±5.32 (29.8-56.4)	39.55±5.01 (29.6-55.6)	P=0.097
<b>Neck shaft angle (NSA)(°)</b>	129.39±4.42 (117.5-145.5)	128.83±4.12 (118.0-143.8)	P=0.095
<b>Femoral neck Width (mm)</b>	34.68±3.09 (26.8-40.7)	34.29±3.19 (26.2-41.5)	P=0.1
<b>Femoral neck Length (mm)</b>	33.49±4.85 (25.9-48.3)	32.84±4.71 (24.3-47.0)	P=0.08
<b>Femoral axis Length (mm)</b>	104.49±7.75 (88.6-124.3)	102.97±7.67 (87.1-124.9)	P=0.024

Table 4

Demonstration of the radiological measurements of different features of the proximal femoral geometry in both genders in Turkish population.

Parameters	Male in	Female in	P value between male and female
Mean±SD (Min.-Max.)	general	general	
Femoral head diameter (mm)	47.96±3.71 (40.7-57.8)	46.30±2.98 (39.2-53.3)	P=0.000
Horizontal offset (mm)	42.31±5.11 (32.7-62.2)	39.88±5.17 (29.6-56.4)	P=0.000
Neck shaft angle (NSA)(°)	130.31±4.13 (119.3-144.8)	129.11±4.28 (117.5-145.5)	P=0.075
Femoral neck Width (mm)	41.9±3.23 (32.3-49.2)	34.48±3.15 (26.2-41.5)	P=0.001
Femoral neck Length (mm)	35.96±4.27 (26.5-48.2)	33.17±4.78 (24.3-48.3)	P=0.02
Femoral axis Length (mm)	115.68±7.66 (98.5-135.2)	103.73±7.74 (87.1-124.9)	P=0.000

For femoral neck width (FNW) of the right and the left hips in the female population, no statistical significance was detected between both sides ( $p=0.1$ ), in the male population a statistical significance was detected between both sides ( $p=0.015$ ). A significant statistical difference was detected between the general FNW mean values of both genders ( $p=0.001$ ).

For the femoral neck length (FNL) of the right and the left hips in the female population no statistical significance was detected between both sides ( $p=0.08$ ), in the male population no statistical significance was also detected between both sides ( $p=0.13$ ). A significant statistical difference was detected between the general FNL of both genders ( $p=0.02$ ).

In comparison of the femoral axis length (FAL) of the right and the left hips in the female population a statistical significance was detected between both sides ( $p=0.024$ ), in the male population no statistical significance was detected between both sides ( $p=0.06$ ). A significant statistical

difference was detected between the general LFA of both genders ( $p=0.000$ ).

## Discussion

Differences were detected between males and females in comparison of all parameters. This suggests us, there are differences in proximal femoral geometry between genders in Turkish population.

Many studies investigated variant aspects of proximal femoral geometry using direct measurements from cadaveric hips, computed tomographies and direct radiographies (10-12).

However by the introduction of picture archiving and communication systems (PACS) which became widespread and the standard radiological viewing tool in many orthopedic clinics, radiologists and orthopedic surgeons became more able to measure angles and distances even in a more precise manner (12,13). A previous cadaveric study had

been conducted to evaluate the osteometry of the proximal femur regarding the Turkish population (11). However the cadavers sample was small and the data regarding the age and the sex of the involved cadavers were not provided by the researchers. In this study, a large sample of patients 190 female and 190 male patients with ages between 40-80 were evaluated providing measurement of variant aspects of the proximal femur.

Femoral head diameter is an important parameter that should be taken into consideration in total hip arthroplasty. In this study the average of the total femoral head diameter in female population was 46.30mm, whereas it was 47.96mm in the male population. However in the general aspect of both genders the right and left FHD were (47.53mm and 46.74mm) respectively, A statistical significance was detected between both sides  $p=0.001$ , the general FHD in both sides was 47.13mm.

Many studies had focused on the head diameter for different ethnic populations(8,14). Siwach RC et. al. (14) in an anthropometric study demonstrated that the average FHD in European population to be  $43.53\pm 3.4$  mm in general, whereas Nobel PC et al. (8) on an osteometric measurements in Caucasians demonstrated the average FHD to be  $46.1\pm 4.8$  mm.

The total horizontal offset average in the Turkish population is 41.11 mm. It had been demonstrated to be around 40.23mm in the Indian, 47mm in the Swiss, 40.5mm in the French and 38mm in the European population (14, 15-17). The neck shaft angle general average in the Turkish population is  $129.71^\circ$ . It had been demonstrated to be around  $124.42^\circ$  in the Indian,  $122.9^\circ$  in the Swiss,  $129.2^\circ$  in the French and  $128.4^\circ$  in a previous study related to the Turkish population (12, 14, 15, and 16).

The age of 40-80 years were chosen in this study since it had been demonstrated to be the most frequent age vulnerable to proximal femoral surgery (18). Many population studies have demonstrated that with aging process the length of the femoral neck increases whereas the width decreases and they have correlated the increase of risk of fractures to these changes (18, 19). No previous studies have evaluated the width and the length of the femoral neck on large patient sample in the Turkish population. The general average femoral neck width was 38.21mm, whereas the general average femoral neck length was 34.56mm. A Brazilian study demonstrated the average general length of the femoral neck to be 36.54mm and the average general width to be 37.48mm (20).

The average femoral axis length in the Turkish population was 109.71mm, in a study for Mourano et al (21), He found lengths of 92.1 mm for the right side and 92.0 mm for the left side. Another old study conducted by O'Neil et al. (19), measured the length of the femoral axis in female population in 1950 and 1990 and recorded values of 124mm and 136.2mm respectively. Another study for Reid et al. (22), recorded values of 124mm and 130.5mm respectively. This difference can be explained by the different methodologies used by researchers, the pelvic structure was not included in the analysis of the length of the femoral axis. Nor was this done in the study by Mourão and Vasconcellos (21).

However this study, like other studies, has several weakness. Being retrospective, is a weak point in this study. The Radiographs of the majority of patients who were involved in this study were obtained from the same region (the Aegean region), it would be wiser to conduct a multicenter study to compare between different regions in Turkey and to yield a more logical standards of the proximal femoral geometry features. One other limitation of the study is, measurements were performed by single surgeon for one time. More persons and more measurements might be performed.

## Conclusion

The average values of the proximal femoral geometry measurement of multiple variants have been demonstrated in this study. There have been statistically significant values between some male and female variables. Male population most of the time present higher values than the female population. This study may offer a data base for surgeons and manufacturers who deal with proximal femoral bone surgery.

## References

- 1-Pires RE, Prata EF, Gibram AV, Santos LE, Lourenço PR, Belloti JC. Radiographic anatomy of the proximal femur: correlation with the occurrence of fractures. *Acta Ortop Bras* 2012; 20(2):79–83.
- 2- Simmermacher RK, Bosch AM, Van der Werken C. The AO/Asif-proximal femoral nail (PFN): a new device for the treatment of unstable proximal femoral fractures. *Injury* 1999;30(5):327–332.
- 3-Xu H, Zhou Y, Liu Q, Tang Q, Yin J. Femoral morphologic differences in subtypes of high developmental dislocation of the hip. *Clin Orthop Relat Res* 2010;468(12):3371–3376.
- 4-Kay RM, Jaki KA, Skaggs DL. The effect of femoral rotation on the projected femoral neck-shaft angle. *J Pediatr Orthop* 2000;20:736-739.

- 5-Massin P, Geais L, Astoin E, Simondi M, Lavaste F. The anatomic basis for the concept of lateralized femoral stems: a frontal plane radiographic study of the proximal femur. *J Arthroplasty* 2000;15: 93–101.
- 6-Greendale GA, Young JT, Huang MH, Bucur A, Wang Y, Seeman T. Hip axis length in midlife Japanese & Caucasians US residents: No evidence for an ethnic difference. *Osteoporos Int* 2003;14:320-325.
- 7-Crabtree N, Lunt M, Holt G, Kröger H, Burger H, Grazio S et al. Hip geometry, bone mineral distribution and bone strength in European men and women: The EPOS Study. *Bone* 2000;27:151-159.
- 8-Noble PC, Alexander JW, Lindahl LJ, Yew DT, Granberry WM, Tullos HS. The anatomic basis of femoral component design. *Clin Orthop* 1988; 235: 148–165.
- 9-Nelson DA, Megyesi MS. Sex and ethnic differences in bone architecture. *Curr Osteop Rep* 2004;2:65-69.
- 10-Fang D, Cheung KM, Ruan D, Chan FL. Computed tomographic osteometry of the Asian lumbar spine. *J Spinal Disord* 1994; 7: 307- 316.
- 11-Bulent A, Ali O, Omur C, Mazhar T, Mumtaz A. Osteometry of the femora in Turkish individuals: a morphometric study in 114 cadaveric femora as an anatomic basis of femoral component design. *Acta Orthop Traumatol Turc* 2007;41(1):64-68.
- 12- Acar N, Harb A, Albaya A, Kaskin H. The clinical results of a novel method for minimal invasive dynamic hip screw fixation of intertrochanteric fractures compared to the conventional one. *Eur J Trauma Emerg Surg* 2016; 1-9
- 13-Gnudi S, Ripamonti C, Lisi L, Fini M, Giardino R, Giavaresi G. Proximal femur geometry to detect and distinguish femoral neck fractures in postmenopausal women. *Osteoporos Int* 2002;13:69–73.
- 14-Siwach RC, Dahiya S. Anthropometric Study of proximal femur geometry and it's clinical application. *Indian J Orthop* 2003;37:247-251.
- 15-Rawal BR, Ribeiro R, Malhotra R, Bhatnagar N. Anthropometric measurements to design best fit femoral stem for Indian population. *Indian J Orthop* 2012; 46(1):46-53.
- 16-Rubin PJ, Leyuraz PF, Aubaniac JM, Argenson JN, Esteve P, de Roguin B. The morphology of the proximal femur. A three dimensional Radiographic analysis. *J Bone Joint Surg[Br]* 1992;74-B:28-32.
- 17-Husmann O, Rubin PJ, Leyvraz PF, de Roguin B, Argenson JN. Three dimensional morphology of the proximal femur. *J Arthroplasty* 1987;12:444-450.
- 18-Duthie RA, Bruce MF, Hutchison JD. Changing proximal femoral geometry in north east Scotland: an osteometric study. *BMJ* 1998;316:1498.
- 19-O'Neill TW, Grazio S, Spector TD, Silman AJ. Geometric measurements of the proximal femur in UK women: secular increase between the late 1950s and early 1990s. *Osteoporos Int* 1996;6(2):136–140.
- 20- de Farias TH, Borges VQ, de Souza ES, Miki N, Abdala F. Radiographic study on the anatomical characteristics of the proximal femur in Brazilian adults revbras ortop 2015;5 0(1):16–21.
- 21-Mourão AL, Vasconcellos HA. Geometria do fêmur proximal em ossos de brasileiros. *Acta Fisiátrica* 2001;8(3):113–119.
- 22- Reid IR, Chin K, Evans MC, Jones JG. Relation between increase in length of hip axis in older women between 1950s and 1990s and increase in age specific rates of hip fracture. *BMJ* 1994;309:508–520.