

## Abdominal Mass shown by the FDG PET/CT with diagnosis of Burkitt Lymphoma

Gökçe YAVAN<sup>1</sup>, Zehra Pınar KOÇ<sup>2</sup>, Pınar Pelin ÖZCAN<sup>3</sup>

<sup>1</sup>Mersin University, Faculty of Medicine, Department of Nuclear Medicine, Mersin, Turkey, gyavan95@gmail.com

<sup>2</sup>Mersin University, Faculty of Medicine, Department of Nuclear Medicine, Mersin, Turkey, zehrapinarkoc@gmail.com

<sup>3</sup>Mersin University, Faculty of Medicine, Department of Nuclear Medicine, Mersin, Turkey, ppelinozcan@gmail.com

Cite this study: Yavan, G. & Koc, Z. P. (2022). Molecular Oncologic Imaging, 3(1), 25-26.

### Keywords

F18-FDG

PET-CT

Abdomen

### Research Article

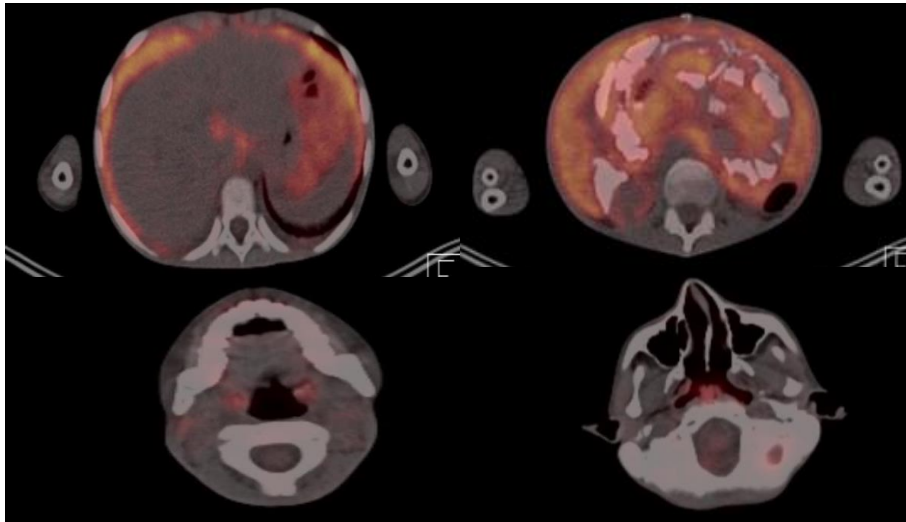
Received: 08.07.2022

Accepted: 15.07.2022

Published: 01.08.2022

### ABSTRACT

Positron emission tomography/computed tomography (PET/CT) with 18F-fluorodeoxyglucose (18F-FDG) is currently a standard imaging examination used in clinical practice, and plays an essential role in preoperative systemic evaluation and tumor staging in various cancer patients. With this method, it is possible to measure or compare metabolic changes in cancer cells. With combined PET/CT, it is possible to determine the correct anatomical location in hypermetabolic tumors with uptake of FDG. In this review, we presented the a case with disseminated abdominal mass diagnosed as Burkitt Lymphoma diagnosed by FDG-PET-CT



**Figure 1.** Nine years old boy with weight loss, abdominal pain, constipation, and night sweats in the last month. CT detected a suspicious intra-abdominal mass. Laparotomy was performed, and a biopsy was taken from the mass. The biopsy confirmed the diagnosis of Burkitt lymphoma. PET/CT examination was performed for staging the disease. After fasting for 12 hours, the patient had a blood glucose level of 67 mg/dL; 3.6 mCi (133 MBq) 18 F-FDG intravenously. After 60 minutes, images were obtained from the calvarium to the feet in the 3D mode for 1 minute per bed. The images obtained were evaluated after attenuation correction with low-dose non-diagnostic CT. An oral contrast agent was given. MIP and axial fusion images showed increased metabolic uptake consistent with lymphoma in the nasopharynx, bilateral tonsils, cervical, and mediastinal lymph nodes, and

lesions consistent with the diffuse abdominal disease in the abdomen. The high grade lymphoma might be rarely presented as abdominal mass (1). However a case series was presented in the literature (2). There was only single case reports similar to the presented case in the literature with severe abdominal and disseminated lymphatic involvement of Burkitts Lymphoma.

#### **Conflict of Interest**

No conflict of interest was declared by the authors.

#### **Author Contributions**

Concept: G.Y.; Design: G.Y.; Supervision: Z.P.K., ; Funding: G.Y., Z.P.K.; Materials: G.Y., Z.P.K.; Data Collection and/or Processing: G.Y.; Analysis and/or Interpretation: G.Y., Z.P.K.; Literature Review: G.Y., Z.P.K.; Writer: G.Y.

#### **REFERENCES**

1. Sachpekidis, C., Exadaktylou, P., Katsampoukas, D., Moravidis, E., & Arsos, G. (2020). <sup>18</sup>F-FDG PET/CT in treatment response evaluation of Burkitt lymphoma: complete remission of a peritoneal super scan. *Hellenic journal of nuclear medicine*, 23(1), 76–78. <https://doi.org/10.1967/s002449912006>
2. Zeng, W., Lechowicz, M. J., Winton, E., Cho, S. M., Galt, J. R., & Halkar, R. (2009). Spectrum of FDG PET/CT findings in Burkitt lymphoma. *Clinical nuclear medicine*, 34(6), 355–358. <https://doi.org/10.1097/RLU.0b013e3181a34552>
3. Wang, X., Chen, Z., Tang, G., & Zhang, X. (2011). A child with Burkitt lymphoma with pleural, peritoneal, mesenteric, omental, and renal involvement: diagnostics by FDG PET/CT. *Clinical nuclear medicine*, 36(7), 612–615. <https://doi.org/10.1097/RLU.0b013e318217af84>



© Author(s) 2021. This work is distributed under <https://creativecommons.org/licenses/by-sa/4.0/>