

Spontaneous Common Bile Duct Perforation Following Serial Stent Placement Due to Benign Stricture ***Benign Striktür Nedeniyle Peşpeşe Stentleme Sonrası Gelişen Spontan Koledok Perforasyonu***

Necdet Fatih Yaşar, Bartu Badak, Adnan Şahin, Mustafa Baspınar, Mustafa Ufuk Uylaş
Eskişehir Osmangazi University General Surgery Clinic, Eskişehir, Türkiye

Abstract: Spontaneous bile duct perforation is a very rare entity in adults. In this report, we present a 75-year-old patient with a history of extraction of bile duct stones and serial stent placement because of chronic pancreatitis related-benign stricture who underwent surgery due to biliary peritonitis. This is the first case of common bile duct perforation following removal of biliary stent. We thought that an elective surgical enterobiliary diversion should have been performed in this patient after detecting the persistence of the stricture on ERCP instead of planning future endoscopic procedures.

Keywords: Choledochus, perforation, stent, stricture, pancreatitis, enterobiliary diversion

Yaşar Fatih N, Badak B, Şahin A, Baspınar M, Uylaş Ufuk M, (2017). *Dual Triggering (Gnrh Agonist And Hcg) In Repeated Total Oocyte Maturation Arrest*, *Osmangazi Journal of Medicine*, 39(1), 74-77, doi:10.20515/otd.288161

Özet: Erişkinlerde safra yollarının spontan perforasyonu çok nadir ortaya çıkan bir durumdur. Bu vaka sunumunda, safra yollarından taş çıkarılması ve kronik pankreatite bağlı gelişen benign striktüre nedeniyle peşpeşe stent takılma öyküsü olan ve safra peritoniti nedeniyle cerrahiye alınan 75 yaşında bir hasta takdim ettik. Safra yollarına takılan stentin çıkarılmasını takiben gelişen ilk koledok perforasyonu vakasıdır. Bu hastada, ERCP'de striktürün devam ettiği görüldükten sonra başka endoskopik prosedürler planlamak yerine elektif cerrahi enterobilier diversiyonun uygulanması gerektiğini düşünmekteyiz.

Anahtar Kelimeler: Koledok, perforasyon, stent, pankreatit, enterobilier diversiyon

Yaşar Fatih N, Badak B, Şahin A, Baspınar M, Uylaş Ufuk M, (2017). *Benign Striktür Nedeniyle Peşpeşe Stentleme Sonrası Gelişen Spontan Koledok Perforasyonu*, *Osmangazi Tıp Dergisi*, 39(1), 74-77, doi:10.20515/otd.288161

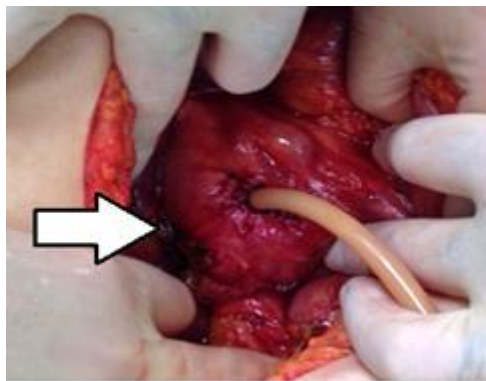
1. Introduction

Endoscopic procedures are widely applied to benign biliary pathologies and biliary stenting have become the preferred choice of treatment for benign common bile duct (CBD) strictures, which provides the highest long term biliary patency rate (1). Here we report a patient who presented with septic shock due to bile peritonitis 6 months after the removal of biliary stent.

2. Case Report

A 75-year-old female patient with a history of cholecystectomy 15 years ago underwent ERCP with stent placement because of obstructive jaundice due to chronic pancreatitis related-benign stricture 2 years ago and bile duct stones were extracted. The plastic stent was exchanged every 3 months for 1 year. After this treatment and removing the last biliary stent, she underwent pancreatic sphincterotomy with stenting 1 month ago for the treatment of chronic pancreatitis. She presented with complain of abdominal pain, fever, deterioration in her general health and mental status in the last 5 days. On the examination, the patient was ill looking, febrile (38.3 °C) with tachycardia (123/min) and hypotensive (80/50 mmHg). There was tenderness and guarding in the whole abdomen. Initial laboratory evaluation

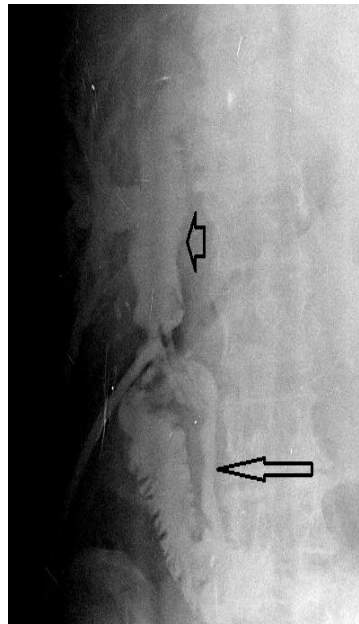
confirmed the shock with the cholestatic syndrome (leukocyte: 32700/mm³, BUN: 73,11mg/dl, creatinin: 2.79mg/dl, total bilirubin: 3.66mg/dl, direct bilirubin: 3.18mg/dl, alkaline phosphatase: 114 U/L, aspartate aminotransferase:131U/L, alanin aminotransferase: 156 U/L). An abdominal ultrasound showed significant dilatations of the intrahepatic bile ducts, CBD (24mm) and right and left hepatic ducts (around 15-20mm) and bile stones in the distal portion of the common bile duct. CT scan revealed dilated bile ducts, choledochus and free intraperitoneal fluid. Abdominal paracentesis revealed bilious fluid. The patient after being expeditiously resuscitated, was taken for urgent exploratory laparotomy. Operative findings revealed gross biliary contamination with about 2 L of bilious fluid in the abdominal cavity. On exploration, a perforation site which was not convenient for T-tube drainage, was noticed on the right posterolateral side of the dilated proximal CBD nearby the stricture and repaired with 4/0 sutures. T-tube drainage of the CBD was performed through a choledochotomy and a thorough peritoneal lavage was done with saline



Resim 1. The repaired perforation site on the dilated common bile duct (arrow) and T-tube placed through the choledochotomy.

The peroperative T-tube cholangiogram revealed benign looking stricture on the distal portion of the common bile duct but no filling

defect and contrast medium freely flowing into duodenum



Resim 2. *The dilated portion of the common bile duct (arrowhead) and the stricture (arrow).*

On the postoperative 3rd day, she was able to be extubated. In spite of medical management and noninvasive respiratory support, respiratory distress syndrome developed 4 days after the extubation and the patient was reintubated and died on the 10th postoperative day because of multiple organ failure.

3. Discussion

Serial stent placement can be used to achieve prolonged ductal patency in chronic pancreatitis related-strictures (2) and is reported to be successful in 58% to 72% of patients (3, 4). The main adverse events with biliary stents are migration and occlusion (5). Cholangitis may also occur when adequate drainage is not achieved and may even cause septic shock and death (6). Duodenal perforation due to stent migration has been described previously as a very unusual complication of biliary stent deployment (7). Park et al has reported a case of retroperitoneal perforation of bile duct as a delayed complication 4 months after a self-expandable metal stent had been placed for palliative management of biliary obstruction in a patient with pancreatic cancer (8). Here we reported spontaneous peritoneal perforation of CBD occurred in a patient 6 months after the removal of the last stent and this is the first case of common bile duct perforation following biliary stent placement.

The etiologic reasons of spontaneous CBD perforations in adults are bile duct stones, biliary diverticulum and acute and chronic pancreatitis (9, 10). We suspect that the previously placed stents had resulted ischemia in nearby tissue and relatively a weak site on the CBD. In turn, after a long period following the removal of the last biliary stent, an unexpected perforation of the common bile duct occurred.

Chronic pancreatitis related-strictures can be treated with serial stent placement successfully. However, the peroperative T-tube cholangiogram showed that the previous procedures were not successful in treatment of the stricture in this patient. The patient had undergone ERCP for stent placement into pancreatic duct for the treatment of chronic pancreatitis. We think that an elective surgical enterobiliary diversion could have been a better and safer option for this patient after detecting the persistence of the stricture on ERCP instead of planning future endoscopic procedures.

4. Conclusion

Surgical enterobiliary diversions still preserve their validity in treatment of persistent benign strictures of ductus choledochus.

Because we could not contact any relative of the patient after the death of the patient, we could not obtain a consent form.

REFERENCES

1. Dumonceau, J. M., Tringali, A., Blero, D., Devière, J., Laugier, R., Heresbach, D., & Costamagna, G. (2012). Biliary stenting: indications, choice of stents and results: European Society of Gastrointestinal Endoscopy (ESGE) clinical guideline. *Endoscopy*, *44*(03), 277-298.
2. Kahl, S., Zimmermann, S., Genz, I., Glasbrenner, B., Pross, M., Schulz, H. U., ... & Malfertheiner, P. (2003). Risk factors for failure of endoscopic stenting of biliary strictures in chronic pancreatitis: a prospective follow-up study. *The American journal of gastroenterology*, *98*(11), 2448-2453.
3. Mahajan, A., Ho, H., Sauer, B., Phillips, M. S., Shami, V. M., Ellen, K., ... & Kahaleh, M. (2009). Temporary placement of fully covered self-expandable metal stents in benign biliary strictures: midterm evaluation (with video). *Gastrointestinal endoscopy*, *70*(2), 303-309.
4. Behm, B., Brock, A., Clarke, B. W., Ellen, K., Northup, P. G., Dumonceau, J. M., & Kahaleh, M. (2009). Partially covered self-expandable metallic stents for benign biliary strictures due to chronic pancreatitis. *Endoscopy*, *41*(06), 547-551.
5. Bagul, A., Pollard, C., & Dennison, A. R. (2010). A review of problems following insertion of biliary stents illustrated by an unusual complication. *The Annals of The Royal College of Surgeons of England*, *92*(4), e27-e31.
6. Pozsár, J., Sahin, P., László, F., Forró, G., & Topa, L. (2004). Medium-term results of endoscopic treatment of common bile duct strictures in chronic calcifying pancreatitis with increasing numbers of stents. *Journal of clinical gastroenterology*, *38*(2), 118-123.
7. Issa, H., Nahawi, M., Bseiso, B., & Al-Salem, A. (2013). Migration of a biliary stent causing duodenal perforation and biliary peritonitis. *World journal of gastrointestinal endoscopy*, *5*(10), 523.
8. Park, S. H., Jeong, S., & Lee, D. H. (2014). Bile duct perforation caused by an uncovered metal stent treated by placement of a covered metal stent in a patient with pancreatic cancer. *Endoscopy*, *46*(S 01), E240-E241.
9. REGE, S. A., LAMBE, S., SETHI, H., GANDHI, A., & ROHONDIA, O. (2002). Spontaneous common bile duct perforation in adult: a case report and review. *International surgery*, *87*(2), 81-82.
10. Yaşar, N. F., Yaşar, B., & Kebapçı, M. (2009). Spontaneous common bile duct perforation due to chronic pancreatitis, presenting as a huge cystic retroperitoneal mass: a case report. *Cases journal*, *2*(1), 1.