

# Histopathologic features of inflammatory fibroid polyps and risk of cancer development: a case series

*İnflamatuar fibroid poliplerin histopatolojik özellikleri ve kanser gelişme riski:*

*bir vaka serisi*

Erdem Çomut, Yeliz Arman Karakaya, Mustafa Çelik, Neşe Çallı Demirkan

Posted date:24.03.2023

Acceptance date:03.05.2023

## Abstract

**Purpose:** Inflammatory fibroid polyp (IFP) is seen in the gastrointestinal tract. In most cases, somatic mutations in PDGFRA gene were observed and the true neoplastic origin of this entity was understood. It is a benign mesenchymal tumor and rarely recurs. The aim of the study was to reveal the histopathologic features of our IFP cases and to investigate the risk of cancer in one case.

**Materials and methods:** We performed a retrospective clinicopathological analysis of patients (n=12) who were reported as IFP between 2012 and 2022. Formalin-fixed, paraffin-embedded and hematoxylin-eosin (H&E)-stained slides of the cases were re-examined by two pathologists microscopically.

**Results:** All patients were adults and ranged in age from 30 to 85. Male to female ratio was 1:2. One polyp was localized in small intestine, one in colon, and the others in stomach. Histologically, there were hyperplastic epithelial changes (7/12), low-grade (3/12), and high-grade dysplasia (1/12) accompanying IFPs. One case was associated with early gastric adenocarcinoma.

**Discussion:** Although IFP appears as a benign mesenchymal tumor, it should be kept in mind that dysplasia and rarely carcinoma may accompany this lesion. Larger case series are needed to elucidate the mechanisms of dysplasia and carcinoma development associated with IFP.

**Key words:** Inflammatory fibroid polyp, gastrointestinal, dysplasia, carcinoma, histopathology.

Çomut E, Arman Karakaya Y, Çelik M, Çallı Demirkan N. Histopathologic features of inflammatory fibroid polyps and risk of cancer development: a case series. Pam Med J 2023;16:476-485.

## Öz

**Amaç:** İnflamatuar fibroid polip (IFP) gastrointestinal sistemde görülür. Çoğu vakada PDGFRA geninde somatik mutasyonlar gözlemlenmiş ve bu antitenin gerçek neoplastik kökeni anlaşılmıştır. Benign mezenkimal bir tümördür ve nadiren tekrarlar. Çalışmanın amacı, IFP olgularımızın histopatolojik özelliklerini ortaya koymak ve kanser riskini araştırmaktır.

**Gereç ve yöntem:** 2012-2022 yılları arasında IFP olarak bildirilen hastaların (n=12) retrospektif klinikopatolojik analizini gerçekleştirdik. Olguların formaline fikse, parafine gömülü ve hematoxilen-eozin (H&E) boyalı preparatları iki patolog tarafından mikroskopik olarak yeniden incelendi.

**Bulgular:** Tüm hastalar yetişkin olup yaşları 30 ile 85 arasında değişmekteydi. Erkek/kadın oranı 1:2 idi. Bir polip ince bağırsakta, biri kolonda ve diğerleri midede lokalizeydi. Histolojik olarak, IFP'lere eşlik eden hiperplastik epitelyal değişiklikler (7/12), düşük dereceli (3/12) ve yüksek dereceli displazi (1/12) görüldü. Bir vakada ise erken gastrik adenokarsinom gelişmişti.

**Sonuç:** IFP benign bir mezenkimal tümör gibi görünsede, bu lezyona displazi ve nadiren karsinomun eşlik edebileceği akılda tutulmalıdır. IFP ile ilişkili displazi ve karsinom gelişim mekanizmalarını aydınlatmak için daha geniş vaka serilerine ihtiyaç vardır.

**Anahtar kelimeler:** İnflamatuar fibroid polip, gastrointestinal, displazi, karsinom, histopatoloji.

Çomut E, Arman Karakaya Y, Çelik M, Çallı Demirkan N. İnflamatuar fibroid poliplerin histopatolojik özellikleri ve kanser gelişme riski: bir vaka serisi. Pam Tıp Derg 2023;16:476-485.

Erdem Çomut, Assist. Prof. Pamukkale University Faculty of Medicine, Department of Pathology, Denizli, Türkiye, e-mail: comuterdem@gmail.com.tr (https://orcid.org/0000-0002-3386-4206) (Corresponding Author)

Yeliz Arman Karakaya, Assoc. Prof. Pamukkale University Faculty of Medicine, Department of Pathology, Denizli, Türkiye, e-mail: yelizkarakaya20@gmail.com (https://orcid.org/0000-0002-6669-9972)

Mustafa Çelik, Assoc. Prof. Pamukkale University Faculty of Medicine, Department of Gastroenterology, Denizli, Türkiye, e-mail: mustafa.dr29@hotmail.com (https://orcid.org/0000-0001-8175-2324)

Neşe Çallı Demirkan, Prof. Pamukkale University Faculty of Medicine, Department of Pathology, Denizli, Türkiye, e-mail: ndemirkan@pau.edu.tr (https://orcid.org/0000-0001-5860-100x)

## Introduction

Inflammatory fibroid polyp (IFP) is a benign mesenchymal tumor that is frequently seen in the gastrointestinal tract (especially in the stomach) and was first described by Vanek in 1949 [1, 2]. IFP was first named 'submucosal granuloma with eosinophilic infiltration' due to its histopathological features [2]. Although IFPs are most commonly observed in the stomach and small intestine, they can also be seen in the distal esophagus, appendix, colon and rarely in the gallbladder [3-5]. There is no clear gender predilection and patients are usually in the 6th and 7th decades [6, 7]. They are often detected as polypoid lesions during endoscopic examination or sometimes on computed tomography (CT) scans of the gastrointestinal tract. On gross examination, they are observed as sessile polyps up to 5 cm in size, sometimes with ulceration on the surface [8, 9]. Histopathology shows spindle and stellate cells (characteristic onion-skin appearance around vascular structures) located in the submucosa and sometimes in the lamina propria, and inflammatory cells rich in eosinophils [10]. Spindle cells do not show distinct pleomorphism or mitotic figures. Immunohistochemically, cells are positive with CD34 and PDGFRA, whereas CD117, DOG1 and S100 are negative [11].

Somatic mutations of the PDGFRA gene have been identified in 55-74% of gastric and intestinal IFPs and affect specifically exons 12, 14 and 18, as in some gastrointestinal stromal tumors (GIST), so IFP should be considered a true benign mesenchymal tumor of the gastrointestinal tract [12, 13]. It is not clear from which cell IFP originates, but in one study, it has been claimed that IFPs and GISTs with PDGFRA mutations originate from an interstitial cell called 'telocyte' [13].

IFPs rarely recur, and its treatment is often performed by endoscopic/surgical excision of the lesion. However, a family with multiple and recurrent IFPs has been described in the literature [14]. Although IFP is generally a benign submucosal neoplasm, some locally aggressive cases with invasion into the muscularis propria and subserosa have been described [15]. To our knowledge, IFP associated with carcinoma described in the literature are a total of 11 cases [7, 16-19].

We present our series of 12 IFP cases (1 localized to small intestine, 1 to colon and the remainder to stomach), including one case associated with early gastric carcinoma.

## Materials and methods

We performed a retrospective clinicopathological analysis of patients (n=12) who were reported as IFP between 2012 and 2022 in our department. Clinical information of the patients (age, sex, endoscopy, surgical procedure, polyp localization, polyp size, etc.) were collected from computerized medical records of the hospital. Follow-up information was obtained by checking routine hospital visits of the patients or by contacting them by phone.

Formalin-fixed, paraffin-embedded and hematoxylin-eosin (H&E) or immunohistochemically - stained slides of 12 cases were re-examined by two pathologists microscopically. On microscopic examination, mucosal ulceration, lesion depth, presence of perivascular onion-skin appearance, lymphoid aggregates, eosinophils, vascular changes, gastric biopsy findings (*Helicobacter pylori* status, intestinal metaplasia, atrophy), architectural changes in the surface epithelium, the presence of dysplasia and intramucosal carcinoma were evaluated. Perivascular onion-skin appearance, submucosal lymphoid aggregates and eosinophils were classified as +, ++ or +++ according to their frequency in each case. Histopathologic classification of IFPs was made based on the study of Kim and Kim [10].

This study was performed in accordance with regulations issued by the Helsinki Declaration; the protocol was approved by the Local Ethical Committee at board meeting No. 06 on April 5, 2022.

## Results

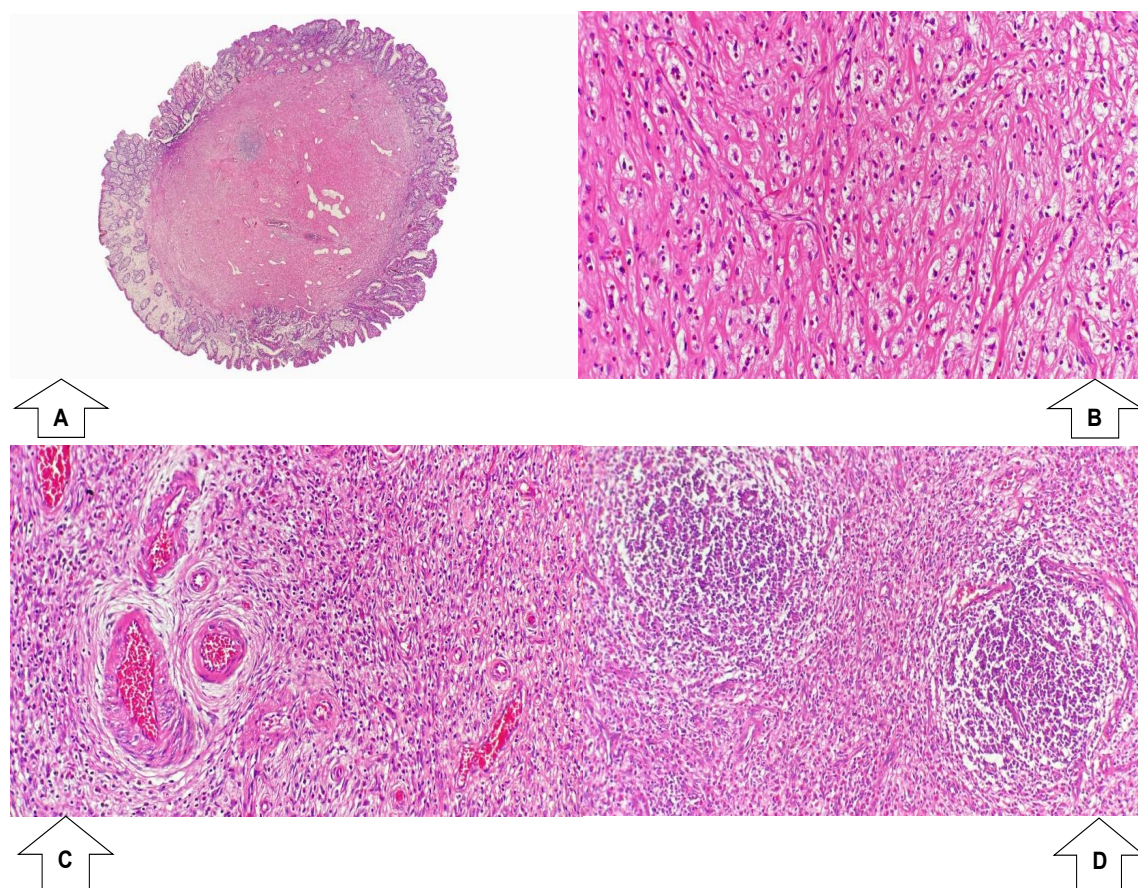
All patients were adults and ranged in age from 30 to 85 (median age 64.2 years). Male to female ratio was 1:2, with female predominance. Polyp size ranged from 4 to 62 mm (median size 21 mm). One polyp was localized in the small intestine, one in the colon, and the others in the stomach. Follow-up times of the cases ranged from 4 to 111 months (with median time 43.5 months). Two of the patients died for unknown reasons. Recurrence was observed in only one

of the cases after 4 years and the patient is still alive (This was our only case with intramucosal carcinoma and its recurrence was reported as 'IFP showing low-grade dysplasia in the surface epithelium').

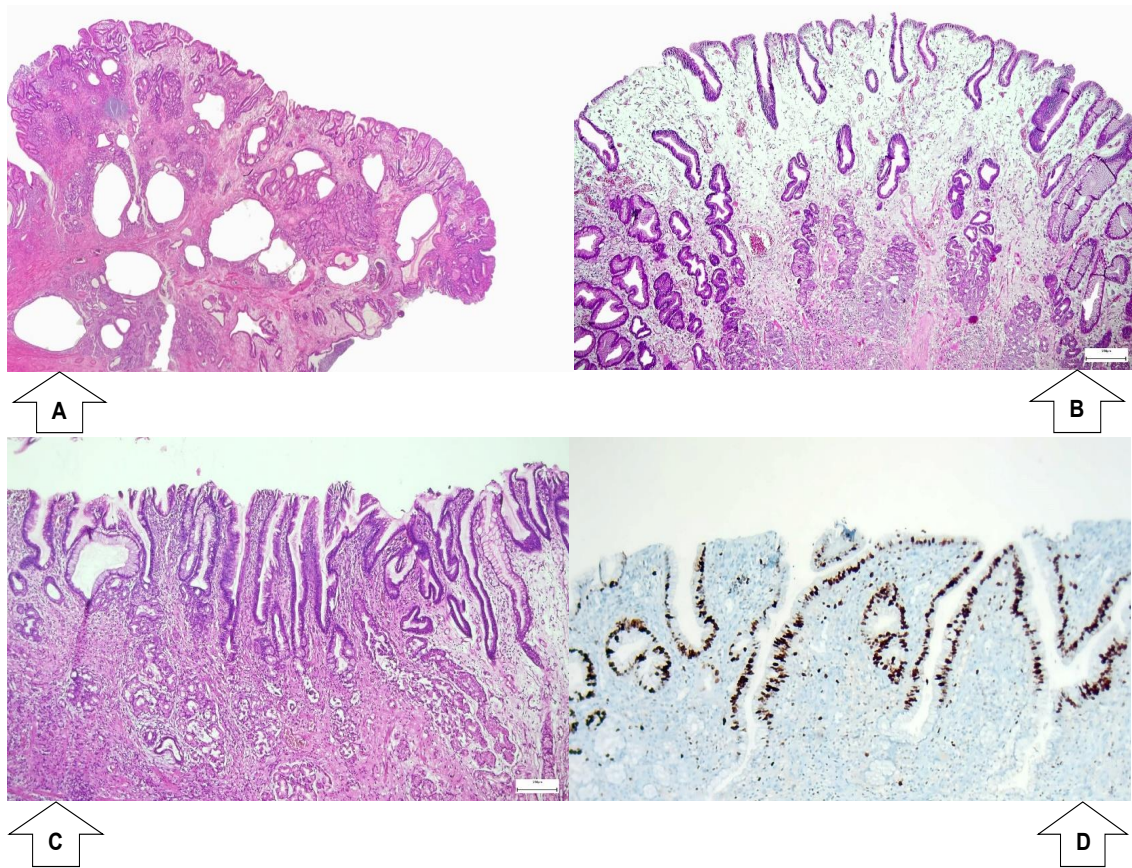
Microscopic examination revealed a mesenchymal lesion consisting mostly of submucosal spindle/stellate cells and variable proportion of eosinophils in fibromyxoid stroma. The characteristic perivascular onion-skin appearance appeared more or less in the majority of cases. Considering the histopathologic classification of Kim and Kim [10], our cases were divided into fibrovascular and sclerotic groups (Figure 1A-

D). Increased mitotic activity or necrosis was not observed. Immunohistochemically, the cells forming the lesion were positive for CD34 and negative for CD117, DOG-1, S100 and Desmin. Hyperplastic changes in the surface epithelium, low-grade dysplasia and increased Ki67 proliferation index in the dysplasia area are shown in Figure 2A-D; IFP-associated intramucosal carcinoma and increased p53 expression in the carcinoma focus are shown in Figure 3A-C.

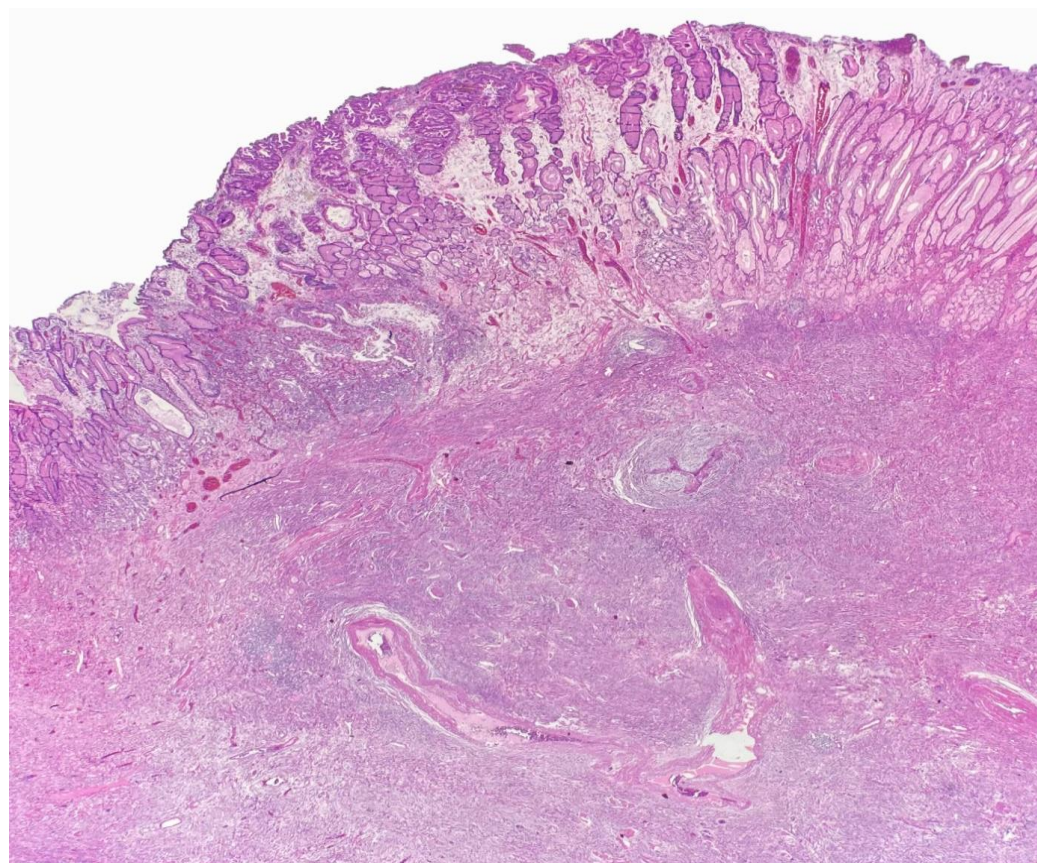
Important clinical and histopathological features of the cases were summarized (Table 1).



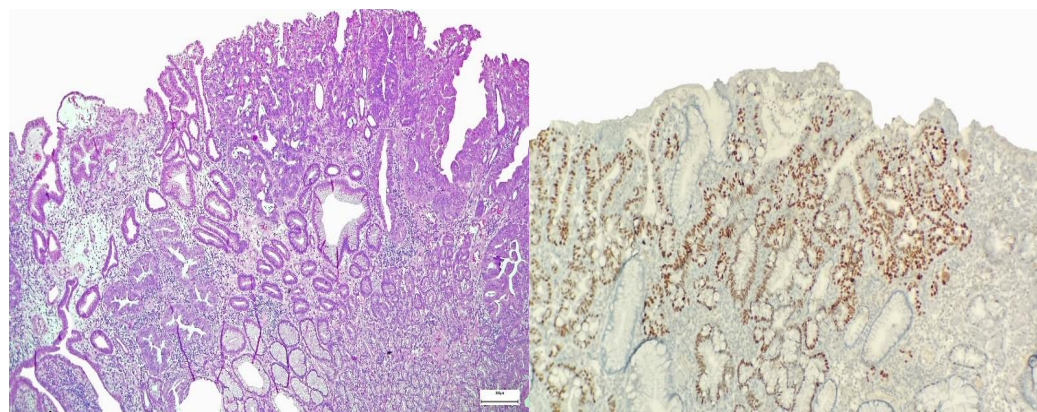
**Figure 1A-D.** In the sclerotic stage, thick collagen bundles and hyalinization are observed, while the number of inflammatory cells is slightly less, H&E, x20 magnification (1A) and x200 magnification (1B). In the fibrovascular stage, fibroblasts with onion-skin appearance around the vessels (1C), numerous inflammatory cells and numerous submucosal lymphoid aggregates (1D) are observed, H&E, x200 magnification



**Figure 2A-D.** Cystic dilatation of the foveolar epithelium and gastric cystic polyposis-like morphology covering inflammatory fibroid polyp, H&E, x20 magnification (2A). Corkscrew-like appearance of the foveolar epithelium covering the inflammatory fibroid polyp, H&E, x40 magnification (2B). Low grade dysplasia of the surface epithelium in a case of gastric inflammatory fibroid polyp, H&E, x100 magnification (2C). Increased Ki-67 proliferation index in low-grade dysplasia focus, immunohistochemistry, x100 magnification (2D)



A



B

C

**Figure 3A-C.** Intramucosal adenocarcinoma on the background of inflammatory fibroid polyp (case no: 5), H&E, x20 magnification (3A). Atypical glands showing crowding, fusion, budding and invasion of the lamina propria (case no: 5), H&E, x100 magnification (3B). Intramucosal adenocarcinoma focus showing nuclear p53 (+) (case no: 5), immunohistochemistry, x100 magnification (3C)

**Table 1.** Clinical and histopathological findings of 12 gastrointestinal inflammatory fibroid polyps

Clinical findings								
No.	Age	Sex	Diameter (mm)	Localization	Surgical method	Colonoscopy	Follow-up (months)	Recurrens
1	68	F	30	Stomach (Antrum)	Partial gastrectomy	N/A	55	-
2	58	M	62	Stomach (Antrum)	Partial gastrectomy	N/A	48	-
3	85	M	20	Stomach (Antrum)	Polypectomy	N/A	57	-
4	46	F	30	Stomach (N/A)	Polypectomy	N/A	111	-
5	67	F	35	Stomach (Antrum)	Polypectomy	N/A	39	+
6	62	M	9	Stomach (Antrum)	Polypectomy	Normal	28, Ex	-
7	72	M	12	Stomach (Antrum)	Polypectomy	Normal	27	-
8	68	F	18	Stomach (Corpus)	Polypectomy	Normal	8	-
9	64	F	22	Stomach (Antrum)	Polypectomy	N/A	4	-
10	69	F	10	Stomach (Corpus)	Polypectomy	N/A	3	-
11	30	F	4	Small intestine	Partial resection	Normal	97	-
12	81	F	30	Colon	Polypectomy	Polyp (IFP)	51, Ex	-

**Table 1.** Clinical and histopathological findings of 12 gastrointestinal inflammatory fibroid polyps (continued)

Histopathological findings												
No.	Depth	Mucosal ulceration	Changes in surface epithelium	Presence of hyperplastic polyp in the stomach	Gastric biopsy findings	Dysplasia	Intramucosal carcinoma	Perivascular onion-skin	Submucosal lymphoid aggregates	Histopathological pattern	Eosinophils	Vascular changes
1	SM	-	-	-	Normal	-	-	++	+++	Fibrovascular	+++	Normal
2	SM + Mu	Focal	Cystic dilatation, corkscrew-like appearance	-	HP	Low grade	-	++	++	Fibrovascular	+++	Intimal thickening
3	SM + Mu	-	-	-	N/A	-	-	++	+	Fibrovascular	+++	Normal
4	SM + Mu	+	Cystic dilatation, corkscrew-like appearance	-	N/A	-	-	+	-	Sclerotic	++	Normal
5	SM + lower 1/2 Mu	-	Cystic dilatation, corkscrew-like appearance	+	CA, IM	Low and high grade	3 mm diameter focus	+	++	Mixed (fibrovascular and sclerotic)	+++	Intimal thickening
6	SM	-	-	+	Normal	-	-	+	++	Fibrovascular	+++	N/A
7	SM + lower 1/2 Mu	-	Mild hyperplastic changes	+	Normal	-	-	+	++	Fibrovascular	+++	Normal
8	SM + Mu	Focal	Mild hyperplastic changes	-	N/A	Low grade	-	+	+	Sclerotic	-	Normal
9	SM + lower 1/2 Mu	-	Cystic dilatation, corkscrew-like appearance	-	CA, IM	-	-	+++	++	Fibrovascular	+++	Intimal thickening
10	SM	-	-	-	N/A	-	-	+	+	Fibrovascular	++	Normal
11	SM, MP	-	-	-	N/A	-	-	-	-	Sclerotic	+	Intimal thickening
12	SM + Mu	Focal	Mild hyperplastic changes	-	N/A	-	-	+	-	Sclerotic	++	Normal

## Discussion

In terms of patient age, our study was consistent with the literature (median age 64.2 years) [7]. Although some studies have reported that IFP is more commonly seen in males [7], our study showed female predominance (M:F=1:2). There are various hypotheses that IFP develops with an allergic or infectious etiology [20]. It was reported that IFP showed some morphological changes after eradication of *Helicobacter pylori* [21]. *Helicobacter Pylori* was present in only one of our ten gastric IFP cases. Considering that IFP can be seen throughout the entire gastrointestinal tract in addition to the stomach, the role of *Helicobacter pylori* in the etiology is controversial.

PDGFRA-mutant syndrome is by definition at least two IFPs and/or GISTs in an individual or a family [22]. Three families with multiple IFPs without mutation data were identified previously in the literature [14, 23]. Although we do not have molecular data, there were multiple IFPs with recurrence in one of our cases. We could not reach the family data of this case.

Two cases of IFP with local aggressive behavior and extension to the muscularis propria were reported [15, 24]. However, except for these two cases, gastric IFPs showing extension to muscularis propria and subserosa were previously described in the literature [10]. In our study, 11 out of 12 IFPs were located in mucosa and/or submucosa; only small intestinal IFP showed invasion of muscularis propria.

In 1988, Kim and Kim [10] classified gastrointestinal IFPs into 4 groups (nodular, fibrovascular, sclerotic and edematous) based on histology and size. According to this study investigating the evolutionary change of IFP, the mean lesion size of the sclerotic or edematous group was higher compared to the other groups. Our cases were histologically classified into two groups as fibrovascular and sclerotic, while 1 case showed mixed (fibrovascular and sclerotic) features. Our study differed from that of Kim and Kim [10] because we did not have any cases in the nodular or edematous stage and the mean lesion size of the fibrovascular group was higher than that of the sclerotic group (25.8 and 20.5 mm, respectively).

Hirasaki et al. [25] reported that gastric cystica polyposa morphology accompanying gastric IFP was observed in the superficial mucosa in one case. In a study by Mori et al. [16], gastric adenoma was reported to accompany 2 gastric IFP cases. We also focused on surface epithelial changes accompanying our IFPs. Histologically, there were hyperplastic epithelial changes (7/12), low-grade dysplasia (3/12), and high-grade dysplasia (1/12) accompanying IFPs. Although we do not have enough data at the moment, it may be possible to explain this association with different mechanisms: 1) Dysplasia may develop due to changes in the surface epithelium secondary to IFP. 2) Both entities may develop independently and coincidentally accompany each other. 3) A common trigger for both entities, such as *Helicobacter pylori* or chronic atrophic gastritis, can lead to their simultaneous occurrence.

Mori et al. [16] analyzed 50 gastric IFP cases and reported early gastric adenocarcinoma accompanying IFP in 4 cases, localized in the antrum and showing mucosal or both mucosal and submucosal involvement. In another study, Mori et al. [17] reported early gastric adenocarcinoma accompanying 2 non-polypoid IFP cases with down-growth pattern. We do not know the follow-up period of these patients, as we can only access the summary of both studies. Mucientes et al. [7] published a case of gastric IFP with early gastric adenocarcinoma in 2012. There was a 1 cm polypoid lesion located in the distal antrum and histomorphological examination revealed intestinal type carcinoma invading the mucosa and superficial submucosa. There was no recurrence or metastasis in the patient with a 108-month follow-up period. In our study, there was only 1 case of early gastric adenocarcinoma associated with IFP. Histopathologic examination of this 35 mm polyp in the antrum revealed a 3 mm diameter carcinoma focus confined to the mucosa. After a 39-month follow-up period, the patient showed recurrent IFP in the antrum. This recurrent polyp was 10 mm in diameter and accompanied by diffuse low-grade dysplasia of the surface epithelium, but no invasive carcinoma was observed. The patient had no distant metastasis.



There were a total of 11 cases of adenocarcinoma accompanying IFP in the literature to date. While 4 of these cases were reported as isolated case reports, the rate of adenocarcinoma accompanying IFP was found to be 8% (4/50) in the study by Mori et al. [16] and 7% (3/42) by Kolodziejczyk et al. [19]. In our study, cancer was associated with only one of our 12 IFP cases. Since our case with the second largest lesion size (35 mm) was associated with carcinoma, we hypothesize that the likelihood of cancer in IFP may increase with increasing lesion size. In addition, in our patient with the largest lesion size (62 mm), although no cancer was observed, low-grade dysplasia in the surface epithelium attracted our attention. However, we could not find information about the lesion sizes of cancerous cases in the largest case series in the literature including gastric cancer cases accompanying IFP [16, 19].

In conclusion, although gastrointestinal IFP appears as a benign mesenchymal tumor, it should be kept in mind that dysplasia and rarely carcinoma may accompany this lesion. Larger case series are needed to elucidate the mechanisms of dysplasia and carcinoma development associated with IFP.

**Conflict of interest:** No conflict of interest was declared by the authors.

## References

- Garpis N, Damaskos C, Garpis A, et al. Inflammatory fibroid polyp of the gastrointestinal tract: A systematic review for a benign tumor. *In Vivo (Brooklyn)* 2021;35:81-93. <https://doi.org/10.21873/INVIVO.12235>
- Vanek J. Gastric submucosal granuloma with eosinophilic infiltration. *Am J Pathol* 1949;25:397-411.
- Sy AM, Vo D, Friedel D, Grendell J, Hanna I. Incidental finding of inflammatory fibroid polyp of the appendix in a patient with acute appendicitis. *Turkish J Gastroenterol* 2020;31:831-834. <https://doi.org/10.5152/TJG.2020.19730>
- Calderon MG, Caivano VC, Bagnaresi S, et al. A unique case of inflammatory fibroid polyp in the duodenum of a female adolescent. Case report and literature review. *Med (United States)* 2017;96:6131. <https://doi.org/10.1097/MD.00000000000006131>
- Martini M, Santoro L, Familiari P, Costamagna G, Ricci R. Inflammatory fibroid polyp of the gallbladder bearing a: platelet-derived growth factor receptor alpha mutation. *Arch Pathol Lab Med* 2013;137:721-724. <https://doi.org/10.5858/arpa.2012-0218-CR>
- De Petris G, Leung ST. Pseudoneoplasms of the gastrointestinal tract. *Arch Pathol Lab Med* 2010;134:878-92. <https://doi.org/10.5858/134.3.378>
- Mucientes P, Mucientes F, Klaassen R. Inflammatory fibroid polyp associated with early gastric carcinoma: a case report. *Ann Diagn Pathol* 2012;16:148-151. <https://doi.org/10.1016/j.anndiagpath.2011.01.001>
- Daum O, Hes O, Vanecek T, et al. Vanek's tumor (Inflammatory Fibroid Polyp). Report of 18 cases and comparison with three cases of original vanek's series. *Ann Diagn Pathol* 2003;7:337-347. <https://doi.org/10.1016/j.anndiagpath.2003.09.003>
- Wang J, Tian X, Ning BF, et al. Clinical characteristics and prognosis of inflammatory fibroid polyp in the gastrointestinal tract: A series of nine cases and a literature review. *J Dig Dis* 2020;21:737-740. <https://doi.org/10.1111/1751-2980.12947>
- Kim YI, Kim WH. Inflammatory fibroid polyps of gastrointestinal tract. Evolution of histologic patterns. *Am J Clin Pathol* 1988;89:721-727. <https://doi.org/10.1093/ajcp/89.6.721>
- Huss S, Wardelmann E, Goltz D, et al. Activating PDGFRA mutations in inflammatory fibroid polyps occur in exons 12, 14 and 18 and are associated with tumour localization. *Histopathology* 2012;61:59-68. <https://doi.org/10.1111/j.1365-2559.2012.04203.x>
- Schildhaus HU, Merkelbach Bruse S, Binot E, Büttner R, Wardelmann E. Inflammatorischer fibroider Polyp. *Pathologe* 2010;31:109-114. <https://doi.org/10.1007/s00292-009-1254-9>
- Ricci R, Martini M, Cenci T, et al. PDGFRA-mutant syndrome. *Mod Pathol* 2015;28:954-964. <https://doi.org/10.1038/modpathol.2015.56>
- Anthony PP, Morris DS, Vowles KDJ. Multiple and recurrent inflammatory fibroid polyps in three generations of a Devon family: a new syndrome. *Gut* 1984;25:854-862. <https://doi.org/10.1136/gut.25.8.854>
- Harima H, Kimura T, Hamabe K, et al. Invasive inflammatory fibroid polyp of the stomach: A case report and literature review. *BMC Gastroenterol* 2018;18:74. <https://doi.org/10.1186/s12876-018-0808-9>
- Mori M, Tamura S, Enjoji M, Sugimachi K. Concomitant presence of inflammatory fibroid polyp and carcinoma or adenoma in the stomach. *Arch Pathol Lab Med* 1988;112:829-832.
- Mori M, Kakeji Y, Adachi Y, Korenaga D, Sugimachi K. Non-polypoid inflammatory fibroid polyps concomitant with early carcinoma in the stomach. *Eur J Surg Oncol* 1992;18:632-635.
- Hirasaki S, Endo H, Nishina T, Masumoto T, Tanimizu M, Hyodo I. Gastric cancer concomitant with inflammatory fibroid polyp treated with endoscopic mucosal resection using an insulation-tip diathermic knife. *Intern Med* 2003;42:259-262. <https://doi.org/10.2169/internalmedicine.42.259>

19. Kolodziejczyk P, Yao T, Tsuneyoshi M. Inflammatory fibroid polyp of the stomach: a special reference to an immunohistochemical profile of 42 cases. *Am J Surg Pathol* 1993;17:1159-1168. <https://doi.org/10.1097/00000478-199311000-00009>
20. Shimer GR, Helwig EB. Inflammatory fibroid polyps of the intestine. *Am J Clin Pathol* 1984;81:708-714. <https://doi.org/10.1093/ajcp/81.6.708>
21. Hirasaki S, Matsubara M, Ikeda F, Taniguchi H, Suzuki S. Gastric inflammatory fibroid polyp treated with *Helicobacter pylori* eradication therapy. *Intern Med* 2007;46:855-858. <https://doi.org/10.2169/internalmedicine.46.6445>
22. Guérit E, Arts F, Dachy G, Boulouadnine B, Demoulin JB. PDGF receptor mutations in human diseases. *Cell Mol Life Sci* 2021;78:3867-3881. <https://doi.org/10.1007/s00018-020-03753-y>
23. Allibone RO, Nanson JK, Anthony PP. Multiple and recurrent inflammatory fibroid polyps in a Devon family ('Devon polyposis syndrome'): an update. *Gut* 1992;33:1004-1005. <https://doi.org/10.1136/gut.33.7.1004>
24. Lee JH, Yoo JS, Jung HY, et al. A case of invasion of muscularis propria of gastric inflammatory fibroid polyp. *Korean J Helicobacter Up Gastrointest Res* 2015;15:254-257. <https://doi.org/10.7704/kjhugr.2015.15.4.254>
25. Hirasaki S, Tanimizu M, Tsubouchi E, Nasu J, Masumoto T. Gastritis cystica polyposa concomitant with gastric inflammatory fibroid polyp occurring in an unoperated stomach. *Intern Med* 2005;44:46-49. <https://doi.org/10.2169/internalmedicine.44.46>

**Ethics committee approval:** Pamukkale University Non-Interventional Clinical Research Ethics Committee Permission has been obtained from the Board (permission date: 05.04.2022, file number: E-60116787-020-193101).

#### **Authors' contributions to the article**

E.C. and N.C.D. constructed the main idea and hypothesis of the study. Y.A.K. developed the theory and arranged/edited the material and method section. M.C. has done the evaluation of the data in the Results section. Discussion section of the article written by E.C. and N.C.D. reviewed, corrected and approved. In addition, all authors discussed the entire study and approved the final version.