

Long Term Results of Arterial Revascularization with Omniflow II® Biosynthetic Grafts: A Single Center Experience

 Baran Şimşek¹,  Davut Azboy²,  Zeki Temiztürk³

¹ Department of Cardiovascular Surgery, Medicana International Hospital, Istanbul, Türkiye

² Department of Cardiovascular Surgery, Elazig Fethi Sekin State Hospital, Elazig, Türkiye

³ Department of Cardiovascular Surgery, University of Health Sciences Cam and Sakura State Hospital, Istanbul, Türkiye

Abstract

Aim: The aim of this study is to analyze the long-term outcomes of above-knee femoro-popliteal bypass procedures with Omniflow® II biosynthetic grafts. Primary patency and graft related complications were the end points of the study.

Methods: Between January 2012 and January 2021, a total of 50 patients (42 males, 8 females) were revascularized using an in-situ Omniflow® II graft. Demographic, clinical, operative and postoperative characteristics of the patients were analyzed retrospectively.

Results: Mean age was 63.8±10.1 (range 40-82) years. Fifty above-knee femoropopliteal bypass procedures were performed. Four patients (8%) were operated on due to a previous vascular graft infection where 8 (16%) were operated on due to a previous occlusion. Primary patency rate was 88%. Early graft thrombosis occurred in 2 (4%) patients where late graft stenosis unrelated to the anastomotic sites was encountered in 1 (2%) patient. An endarterectomy on either the proximal or distal site of the anastomosis were performed in 12 (24%) patients. Mean follow-up was 32.9±20.8 (range 12-90) months. Three (6%) patients died due to a COVID-19 infection. No graft infection nor mortality related to arterial bypass procedures was encountered.

Conclusion: The Omniflow® II biosynthetic graft provides superior results in treatment of above-knee femoro-popliteal bypass procedures with high patency rates and low incidence of graft infection and aneurysm formation.

Keywords: Biosynthetic graft, vascular grafting, revascularization, peripheral arterial disease

1. Introduction

Patients with peripheral arterial disease (PAD) have a poor circulation due to decreased arterial perfusion. The arterial blood flow to the distal extremity is restricted most frequently by systemic atherosclerosis. Its prevalence is 3-10% between 40-59 years and 15-20% over 70 years¹. The most significant risk factors for PAD are diabetes mellitus (DM), hypertension (HT), hyperlipidemia (HL), chronic kidney disease (CKD), and smoking². In addition, there is an increased rate of myocardial infarction, ischemic stroke, and cardiovascular death in patients with PAD³.

There is a remarkable elevated risk of adverse limb events like ischemic ulceration and gangrene unless treated. Revascularization deemed mandatory, particularly in patients with more advanced symptoms and presentations. Duplex ultrasonography, computed tomography angiography (CTA), magnetic resonance angiography or conventional peripheral angiography should be performed to diagnose and define the anatomy before revascularization. Though endovascular approaches have extended the invasive treatment modalities in peripheral arterial occlusive disease, surgical interventions must be considered especially for long occlusive disease, aneurysm formation, vascular graft infection and failure of endovascular treatment.

Despite the fact that superiority of the autogenous grafts are well-known, prosthetic grafts should be the selected conduit type in a variety of patients especially when autogenous grafts are not accessible, available or suitable⁴. Since 1983, the Omniflow® vascular grafts have been in clinical practice and advances in technology throughout this time period led to the current Omniflow® II vascular graft (OVG)⁵⁻⁷. Omniflow® II (Bio Nova International, Victoria, Australia) is created by using cross linked ovine collagen and an endoskeleton made of polyester mesh which

* Corresponding Author: Baran Şimşek,
e-mail: simsekbaran@yahoo.com

Received: 03.04.2023, Accepted: 01.06.2023, Available Online Date:
31.08.2023

Cite this article as: Simsek B, Azboy D, Temiztürk Z. Long term results of arterial revascularization with Omniflow® II biosynthetic grafts: a single center experience. *J Cukurova Anesth Surg.* 2023; 6(2): 210-4. doi: 10.36516/jocass.1276127
Copyright © 2023 This is an open access article distributed under the terms of the Creative Commons Attribution-Non Commercial-No Derivatives License 4.0 (CC-BY-NC-ND), where it is permissible to download and share the work provided it is properly cited. The work cannot be changed in any way or used commercially without permission from the journal.

suggests superior long-term patency and low degeneration rates with a decreased vulnerability to infection^{8,9}.

The aim of the present study was to analyze the experience and long-term outcomes of patients with above-knee femoropopliteal bypass procedures with OVG.

2. Materials and methods

50 patients who underwent peripheral arterial revascularization with an OVG between January 2012 and January 2021 were identified from our vascular database. This was a retrospective and single-center study which was approved by the local Ethics Committee (protocol no: 18.03.2021-2021/04-05) and was conducted in accordance with the Declaration of Helsinki (as revised in 2013). Informed consents were obtained from the participants of the study. Parametric data is presented as mean and standard deviation, non-parametric data is presented as interquartile range, where applicable.

2.1. Patients and data

This study retrospectively reviewed the medical records of 50 patients (42 males, 8 females) with a mean age of 63.8 ± 10.1 years (range 40-82) who had undergone above-knee femoro-popliteal bypass surgery. The conduit preference was Omniflow® II (Bio Nova International, Victoria, Australia) when autogenous grafts were not accessible, available or suitable. Patients who had undergone a re-do surgery with OVG due to either previously infected grafts or occluded grafts were also included in the study. Patients' demographic, clinical, perioperative and postoperative follow-up data including complications were assessed in a retrospective design. Data included age, gender, history of DM, coronary artery disease, carotid artery disease, HT, HL, CKD, smoking, chronic obstructive pulmonary disease (COPD) and follow-up time. The baseline characteristics of the patients are demonstrated in Table 1. Symptomatic and descriptive classification of the patients were assessed according to the Rutherford Classification and Global Limb Anatomic Staging System (GLASS), where patients with previous infected grafts were graded with wound, ischemia, foot infection (WIFI) composite scores which are demonstrated in Table 2¹⁰⁻¹². CTA and/or conventional peripheral angiography was performed to define the anatomy and decide the right surgical strategy before revascularization.

2.2. Surgical technique

Surgery was performed either under general or spinal anesthesia. A 6-mm OVG was preferred in above-knee femoropopliteal bypass procedures (Image 1-2). The OVG was rinsed following the manufacturer's implantation protocol. After intravenous administration of 5000 units of heparin and confirming an activated clotting time >200 seconds, anastomoses were constructed in an end to side fashion both in distal and proximal sites. Heparin was not reversed with protamine. During the first 24 hours, 1 mg/kg intravenous heparin infusion was administered. Thereafter, the treatment switched to therapeutic subcutaneous low molecular weight heparin (LMWH) with warfarin and Aspirin up to discharge. After reaching an International Normalized Ratio (INR) >2 , LMWH treatment was quitted at the end of the first year of surgery where Aspirin was administered life-long. In the presence of contraindications to oral anti-coagulation, long-term anti-platelet medication was administered.

In cases of 4 infected previously expanded polytetrafluoroethylene (ePTFE) bypass grafts which were occurred lately after initial bypass, all grafts were removed with infected tissue debridement. Revascularization was performed with OVG by using fresh anastomotic sites through uninfected tissue planes.

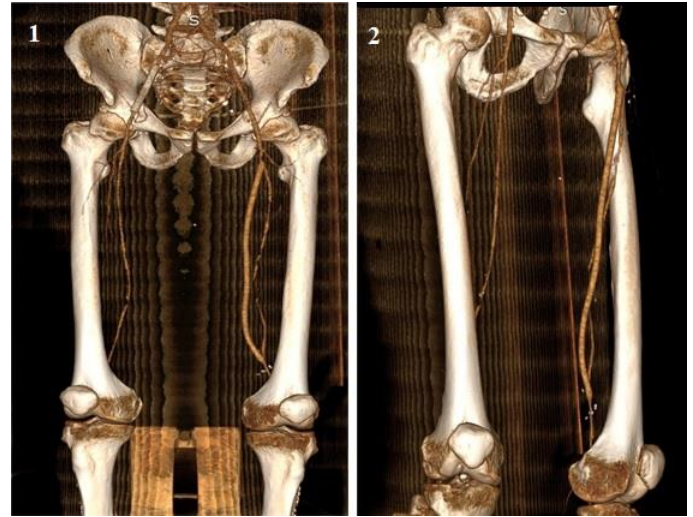


Image 1-2

- 1 Postoperative third year control computerized tomographic angiographic evaluation of a 6-mm Omniflow® II biosynthetic vascular graft in above-knee femoropopliteal position
- 2 Postoperative fourth year control computerized tomographic angiographic evaluation

In cases of 4 infected previously expanded polytetrafluoroethylene (ePTFE) bypass grafts which were occurred lately after initial bypass, all grafts were removed with infected tissue debridement. Revascularization was performed with OVG by using fresh anastomotic sites through uninfected tissue planes. Depending on the patient's condition, preoperative broad spectrum antimicrobial treatment was administered with a postoperative adaptation due to identification of the causative microorganisms. The duration and type of the antimicrobial treatment was determined within an infectious disease specialist consultation.

Primary patency is described as the period from the bypass procedure till any necessary intervention needed to reestablish or maintain patency. Bypass patency was evaluated by physical examination and duplex ultrasonography at first, third and sixth months and yearly afterwards in the outpatient clinic. The control CTA evaluations were performed in the first year of surgery and yearly afterwards as long as our patients remain symptom-free.

3. Results

A total of 50 patients (42 males, 8 females), with a mean age of 63.8 ± 10.1 years (range 40-82) were identified. Fifty OVGs were implanted in the above-knee femoropopliteal position. The indication for initial biosynthetic graft implantation was occlusive disease in 46 (92%) patients. Four patients (8%) were operated on due to a previous ePTFE graft infection which were implanted in other centers. The causative microorganisms were coagulase-negative Staphylococci in 3 patients and Staphylococcus aureus in 1 patient. Preoperative broad spectrum antimicrobial treatment was administered with a postoperative adaptation due to identification of the causative microorganisms. The duration of the anti-infective treatment after discharge was determined individually according to the recommendation of the infectious diseases specialist. No clinical evidence of graft re-infection encountered in the follow-up period.

Table 1
The baseline characteristics

Variable	n	%	Mean±SD
Total number of patients	50	100	
Age (years)			63.8±10.1 (range 40-82)
Male sex	42	84	
Hypertension	17	34	
Diabetes mellitus	30	60	
Smoking history	34	68	
Hyperlipidemia	35	70	
Coronary artery disease	25	50	
Carotid artery disease	3	6	
Chronic kidney disease	2	4	
COPD	6	12	
Follow-up (months)			32.9±20.8 (range 12-90)

COPD: Chronic obstructive pulmonary disease, SD: standard deviation

Table 2
Symptomatical and descriptive classification of the patients

	n	%
Rutherford stage		
Stage 1	1	2
Stage 2	8	16
Stage 3	18	36
Stage 4	22	44
Stage 5	1	2
GLASS score		
Stage 1	9	18
Stage 2	29	58
Stage 3	12	24
Wifl score		
1	8	16
2	40	80
3	1	2
4	1	2

GLASS: Global Limb Anatomic Staging System, Wifl: Wound Ischemia Foot Infection

Eight patients (16%) were operated on due to a previously occluded ePTFE grafts in above-knee femoropopliteal position without any acute ischemic status. An endarterectomy on either the proximal or distal site of the anastomosis were performed in 12 (24%) patients.

There was either perioperative morbidity or mortality among the patient group. Delayed wound healing was encountered in 4 (8%) patients. None of the patients needed surgical revision due to bleeding or hematomas. Early postoperative graft occlusion within 30 days occurred in 2 (4%) above-knee femoropopliteal bypass patients which was managed by successful surgical thrombectomy. Late graft stenosis unrelated to the anastomotic sites was encountered in 1 (2%) femoropopliteal bypass patient, which was managed by a resection and replacement within a new OVG 44 months after the initial bypass procedure. Three (6%) patients died due to a COVID-19 infection. There was neither aneurysmal dilation nor graft aneurysm formation detected at anastomotic sites. No graft infection nor mortality related to arterial bypass procedures was encountered. The overall primary patency rate was 88%. Mean follow-up was 32.9±20.8 (range 12-90) months.

4. Discussion

The OVG which was designed to overcome the drawbacks of synthetic and biological conduits, has been off the shelf for about 30 years but there have been few studies published on complication and long term patency rates^{4,9,13}. The graft was created by inserting polyester scaffolded silicone mandrels into sheep to produce a wound healing counteraction that integrates the polyester mesh. This tissue-engineered product which is cross-linked with glutaraldehyde led to a non-antigenic vascular conduit. In contrast with other approaches, the incorporated polyester mesh contributes structural stability for the vascular wall and the blood flow surface which was assumed to be smooth and non-thrombogenic⁵. Anticoagulant and antiplatelet medications have been reported to improve bypass graft patency. It should be kept in mind when implanting the OVG, a higher anticoagulation management in the early postoperative period might be considered¹⁴. Discontinuation of oral anticoagulation might be a potential reason for acute graft failure. Nevertheless, till today we have more detailed information about the above-knee femoropopliteal bypass graft patency with the OVG rather than crural position^{9,15}. Primary and secondary patency rates were 48% and 71% with the composite bypasses with autologous vein and OVG as the proximal part of such bypasses in below-knee anatomic positions^{8,16}. Another reason to prefer the OVG is the polyester mesh which provides more resistance to external compression in order to prevent potential kinking. Toktas et al. reported 98% patency rate at third year, 95% at fourth year and 78% at fifth year follow-up in the above knee femoro-popliteal bypass groups with OVG¹³. Yet the OVG was used as a carotid patch and also reported for hemodialysis access with promising results^{17,18}.

Despite the fact that the preferred graft to revascularize the lower limbs is the autologous saphenous vein, in up to 45% it may not be accessible, available or suitable due to previous coronary or lower limb bypass procedures, varicose veins of the lower limbs, previous surgery for varicose veins or mismatches in diameter and length^{19,20}. In these kind of situations, alternative graft usage should be considered. Although ePTFE has been the most preferred prosthesis, the systematic review and meta-analysis by Wilasrusmee et al. revealed that there is a 54% higher graft patency in biological grafts compared to ePTFE in femoropopliteal bypass procedures and vascular access grafts²¹.

Vascular graft infection is a rare but dreaded complication with significant morbidity and mortality which is associated with the use

of prosthetic grafts, postoperative hematoma, superficial wound infection, lymphocele, lymphorrhea and medical comorbidities²². Prosthetic vascular grafts are mostly infected in the perioperative stage. Accomplishing asepsis is essential in terms of avoiding vascular graft infection. Though, the graft might be infected despite excellent asepsis techniques. Autologous veins are suggested as the first choice graft material in terms of infection²³. Autogenous veins are the most common grafts which are used for in situ revascularization for infected vascular grafts; however it may be unavailable or unsuitable. Once the graft infection develops, the most suitable treatment is removing the infected graft. The OVG seems to be promising for peripheral arterial reconstruction in case of infection. Results from clinical practice have proven a good infection resistance^{4,9,24}. On the other hand, there have been concerns about its resistance to bacterial colonization regarding animal studies²⁵. There is strong evidence that redo surgery is related to increased risk of prosthetic vascular graft infection^{24,26,27,28}. We replaced 4 infected ePTFE grafts in the above-knee femoropopliteal position with an OVG with no reinfections in a 5-years follow-up period. We propose that the OVG may be a good choice to replace an infected graft material.

An aneurysm is a vascular condition which can be defined as localised dilation due to weakness. Infection, intraoperative damage, improper sterilization or storage, expansion of the polyester mesh, trauma, anastomotic failures are the main reasons of aneurysm formation. The possibility of late aneurysmal degeneration has always been a debate in biological grafts as all biologic materials are subject to probable biodegradation with consequent aneurysm formation^{4,29}. Nevertheless, the anatomic position of the graft in the extremity, the patient's systemic diseases, such as autoimmune diseases, hypertension and dyslipidemia may also contribute to aneurysmal dilation. Aneurysmal degeneration may impair graft patency by leading to thrombosis as well as local symptoms³⁰. In case of thrombus formation, early replacement might be kept in mind to avoid possible embolization. Such different rates were reported for aneurysm formation following bypass procedures with OVG. Koch et al. reported only 1.1% in 267 cases where Van de Laar et al. reported 8% in 25 patients^{9,31}. We detected no graft aneurysm formation in the follow-up period. Patients should be followed-up regularly with duplex ultrasound and physical examination not to overlook a degenerative aneurysm.

4.1. Study Limitations

The small number of patients might be a limitation. Thus, further prospective studies in order to compare the results with different types of synthetic vascular graft materials in terms of infection may help to provide further insight with regard to patency rates, incidence of graft infection and aneurysm formation. The retrospective nature of the study is another limitation.

5. Conclusions

The Omniflow® II biosynthetic vascular graft provides encouraging results in treatment of above-knee femoro-popliteal bypass procedures with high patency rates and low incidence of graft infection and aneurysm formation. Peripheral vascular reconstruction with the Omniflow® II biosynthetic vascular grafts appears to be feasible, safe and acceptable for revascularization when autogenous vein grafts are not accessible, available or suitable.

Acknowledgements

None.

Statement of ethics

This was a retrospective and single-center study which was approved by the Firat University local Ethics Committee (protocol no: 18.03.2021-2021/04-05) and was conducted in accordance with the Declaration of Helsinki (as revised in 2013).

Conflict of interest statement

The authors declare that they have no financial conflict of interest with regard to the content of this report.

Funding source

The authors received no financial support for the research, authorship, and/or publication of this article.

Author contributions

BS: Design, writing the article, literature review, critical review, DA: Idea/concept, data collection, analysis and interpretation, ZT Data collection, control/supervision, analysis and interpretation

All authors read and approved the final manuscript.

References

- Shvedov A, Ivchenko A, Ivchenko O, et al. Clinical assessment of xenograft combined with knitted TiNi-based mesh implant in femoropopliteal bypass surgery: a Case Report. *KnE Materials Science*. 2017; 2(1): 410-7. <https://doi.org/10.18502/kms.v2i1.827>
- Firnhaber JM, Powell CS. Lower extremity peripheral artery disease: Diagnosis and treatment. *Am Fam Physician*. 2019; 99(6): 362-9.
- Bevan GH, White Solaru KT. Evidence-based medical management of peripheral artery disease. *Arterioscler Thromb Vasc Biol*. 2020; 40(3): 541-53. <https://doi.org/10.1161/ATVBAHA.119.312142>
- Neufang A, Duenschede F, Espinola-Klein C, et al. Contemporary results with the biosynthetic glutaraldehyde denaturated ovine collagen graft (Omniflow II) in femoropopliteal position. *J Vasc Surg*. 2020; 71(5): 1630-43. <https://doi.org/10.1016/j.jvs.2019.08.234>
- Ramshaw JAM, Werkmeister JA, Edwards GA. Tissue-Polymer Composite Vascular Prostheses. *Encyclopedic Handbook of Biomaterials and Bioengineering*, vol 2. New York: Marcel Dekker, 1995.
- Edwards G, Roberts G. Development of an ovine collagen-based composite biosynthetic vascular prosthesis. *Clin Mater*. 1992; 9: 211-23. [https://doi.org/10.1016/0267-6605\(92\)90102-Y](https://doi.org/10.1016/0267-6605(92)90102-Y)
- Raithel D, Noppeney T, Kasprzak P. Long term results of peripheral reconstruction with an ovine collagen prosthesis. *J Cardiovasc Surg*. 1989; 30: 91-2.
- Koch G, Gutsch S, Pascher O, et al. Femoropopliteal vascular replacement: vein, ePTFE or ovine collagen? *Zentralbl Chir*. 1996; 121(9): 761-7.
- Koch G, Gutsch S, Pascher O, et al. Analysis of 274 omniflow vascular prosthesis implanted over an eight-year period. *Aust NZJ Surg*. 1997; 67(9): 637-9. <https://doi.org/10.1111/j.1445-2197.1997.tb04614.x>
- Braun R, Lin M. Acute limb ischemia: A case report and literature review. *J Emerg Med*. 2015; 49(6): 1011-7. <https://doi.org/10.1016/j.jemermed.2015.03.008>
- Wijnand JGJ, Zarkowsky D, Wu B, et al. The Global Limb Anatomic Staging System (GLASS) for CLTI: Improving inter-observer agreement. *J Clin Med*. 2021;10(16): 3454. <https://doi.org/10.3390/jcm10163454>
- Blanchette V, Fernando ME, Shin L, et al. Evolution of Wifl: Expansion of Wifl notation after intervention. *Int J Low Extrem Wounds*. 2022;15347346221122860. <https://doi.org/10.1177/15347346221122860>
- Toktaş F, Çayır MÇ, Özsin KK, et al. Long-term outcomes of Omniflow II biosynthetic vascular graft in lower extremity arterial revascularization. *Türk Gogus Kalp Damar Cerrahisi Dergisi*. 2018; 26(3): 407-13. <https://doi.org/10.5606/tgkdc.dergisi.2018.15689>
- Keschenau PR, Gombert A, Barbati ME, et al. Xenogeneic materials for the surgical treatment of aortic infections. *J Thorac Dis*. 2021; 13(5): 3021-32. <https://doi.org/10.21037/jtd-20-3481>

15. Yoshida H, Sasajima T, Goh K, et al. Early results of a reinforced biosynthetic ovine collagen vascular prosthesis for small arterial reconstruction. *Surg Today*. 1996; 26: 262-6.
<https://doi.org/10.1007/BF00311585>
16. Mamode N, Scott RN. Graft type for femoro-popliteal bypass surgery. *Cochrane Database Syst Rev*. 2000;2:CD001487.
<https://doi.org/10.1002/14651858.CD001487>
17. Pratesi C, Pulli R, Michelagnoli S. Early and late results of biosynthetic ovine carotid angioplasty. *Int Angiol*. 1993; 12: 47-53.
18. Palumbo R, Niscola P, Calabria S, et al. Long-term favorable results by arteriovenous graft with Omniflow II prosthesis for hemodialysis. *Nephron Clin Prac*. 2009; 113: c76-80
<https://doi.org/10.1159/000228538>
19. Moreira C, Leung A, Farber A, et al. Alternative conduit for infrageniculate bypass in patients with critical limb ischemia. *J Vasc Surg*. 2016; 64: 131-9.e
<https://doi.org/10.1016/j.jvs.2016.01.042>
20. Ziza V, Canaud L, Gandet T, et al. Outcomes of cold-stored venous allograft for below-knee bypasses in patients with critical limb ischemia. *J Vasc Surg*. 2015; 62(4): 974-83.
<https://doi.org/10.1016/j.jvs.2015.04.437>
21. Wilasrusmee C, Siribumrungwong B, Horsiramanont S, et al. Clinical results of biological prosthesis: A systematic review and meta-analysis of comparative studies. *Ann Med Surg (Lond)* 2017; 15: 26-33.
<https://doi.org/10.1016/j.amsu.2017.01.018>
22. Kim Y, DeCarlo C, Jessula S, et al. Risk factors and consequences of graft infection after femoro-popliteal bypass: A 25-year experience. *J Vasc Surg*. 2022; 76(1): 248-54.
<https://doi.org/10.1016/j.jvs.2022.02.045>
23. Chakfe N, Diener H, Lejay A, et al. Editor's choice-European Society for Vascular Surgery (ESVS) 2020 Clinical practice Guidelines on the management of vascular graft and endograft infections. *Eur J Vasc Endovasc Surg*. 2020; 59: 339-84.
<https://doi.org/10.1016/j.eivs.2019.10.016>
24. Wiltberger G, Matia I, Schmelzle M, et al. Mid-and long-term results after replacement of infected peripheral vascular prosthetic grafts with iosynthetic collagen prosthesis. *J Cardiovasc Surg (Torino)*. 2014; 55: 693-8.
25. Wozniak W, Kozinska A, Ciostek P, et al. Susceptibility of vascular implants to colonization in vitro by *Staphylococcus aureus*, *Staphylococcus epidermidis*, *Enterococcus faecalis* and *Pseudomonas aeruginosa*. *Pol J Microbiol* 2017; 66(1): 125-9.
<https://doi.org/10.5604/17331331.1235002>
26. Töpel I, Stigler T, Ayx I, et al. Biosynthetic grafts to replace infected prosthetic vascular bypasses: a single-center experience. *Surgical infections*. 2017; 18(1): 202-5.
<https://doi.org/10.1089/sur.2016.203>
27. Etkin Y, Rao A, Jackson BM, et al. Infections of prosthetic grafts and patches used for infrainguinal arterial reconstructions. *Ann Vasc Surg*. 2019; 57: 152-9.
<https://doi.org/10.1016/j.avsg.2018.09.015>
28. Rossi PJ, Skelly CL, Meyerson SL, et al. Redo infrainguinal bypass: factors predicting patency and limb salvage. *Ann Vasc Surg*. 2003; 17(5): 492-502.
<https://doi.org/10.1007/s10016-003-0040-z>
29. Yamamoto S, Hoshina K, Kimura H, et al. Clinical analysis of non-anastomotic aneurysms of implanted prosthetic grafts. *Surg Today*. 2014; 44(10): 1855-62.
<https://doi.org/10.1007/s00595-014-0888-2>
30. Werkmeister JA, White JF, Edwards GA, et al. Early performance appraisal of the Omniflow II vascular prosthesis as an indicator of long-term function. *J Long Term Eff Med Implants*. 1995; 5: 1-10.
31. Van de Laar BC, van Heusden HC, Pasker-de Jong PC, et al. Omniflow II biosynthetic grafts versus expanded polytetrafluoroethylene grafts for infrainguinal bypass surgery. A single-center retrospective analysis. *Vascular*. 2022; 30(4): 749-58.
<https://doi.org/10.1177/17085381211029815>