

THE TIME OF ERUPTION OF THE THIRD MOLARS IN THE CHALCOLITHIC AND COPPER AGE INHABITANTS OF ANATOLIA

Prof. Dr. MUZAFFER ŞENYÜREK

Chairman of the Division of Palaeoanthropology, University of Ankara

In a previous study on the order of eruption of the permanent teeth in the Chalcolithic and Copper Age population of Anatolia, I had also discussed the time of eruption of the third molars.¹ In this study, from the completion of the eruption of the wisdom teeth in 16 out of 17 individuals of 20-22 years of age, I had reached the conclusion that in the majority of the Chalcolithic and Copper Age population of Anatolia the wisdom teeth had appeared before the age of twenty.² Since the publication of this paper, I have been working on the human skeletons found at Yazılıkaya (Midas City).³ As I observed that in two youths (Nos. V and C-2), found at Yazılıkaya and belonging to the Copper Age, the wisdom teeth had appeared, I have considered it worthwhile to restudy this subject.

Skeleton No. V: The morphology of the fragments of os coxae preserved shows that a male individual is being dealt with here. In the skull the basilar suture is not closed. The sagittal, coronal and lambdoid sutures are completely open on both the ectocranial and endocranial surfaces of the skull. The proximal conjoint epiphysis

¹ Şenyürek, M. Order of eruption of the permanent teeth in the Chalcolithic and Copper Age inhabitants of Anatolia. *Belleten*, vol. XX, no. 77, 1956, pp. 1-28.

² *Ibid.*, p. 21.

³ A mandible from Yazılıkaya, found in the tunnel and in earth containing late Phrygian potsherds, gives us information on the order of eruption of other teeth. In this mandible, while the second permanent molars are erupted on both sides, the right and left second premolars are still unerupted. In addition in the mandible No. Aa, belonging to the Copper Age, the first permanent molar is found just below the alveolar margin, while the central permanent incisors are still deeply buried below the first milk incisors.

On this occasion I wish to express my thanks to the Archaeological Expedition to Midas City and to Docent Dr. Halet Çambel for having sent these skeletons to me for study.

and the medial epicondyle of the humerus, the proximal epiphysis of radius,⁴ the distal epiphysis of a metacarpal bone and the proximal epiphysis in a phalanx prima of the hand have not yet joined the diaphysis. The epiphyses on the head, the greater trochanter and the lesser trochanter of the femur are also open.⁵ In scapula, a rough area observed on top of the glenoid cavity shows that the subcoracoid element has not yet fused. In os coxae, although the epiphysis on the iliac crest is missing, it is clearly seen that it had not closed. The epiphysis covering the sciatic tuberosity has developed, but, with the exception of a small section of its margin on the right side, has not yet fused. The epiphysis forming the top of the olecranon in ulna is mostly closed.⁶ Only a crack observed on the posterior side shows that this epiphysis has not yet completed its union. According to Flecker's figures for the closure of epiphyses in males, this skeleton belongs to an individual of about 16 years of age.⁷

In this skeleton a portion of the right maxilla and a large part of the mandible are preserved. As the part of right maxilla behind the second premolar is broken and as second and third molars have not been preserved, it is not known whether the upper third molar had erupted or not. The part of the mandible behind the left second premolar is broken and missing, but its right half is fully preserved. In this lower jaw the first right incisor, the second left incisor, right and left canines, right and left first and second premolars, and the right first, second and third molars have been retained *in situ* (see fig. 1). The first left incisor and the second right incisor have been lost after death. However, the left first molar, which has fallen after death, has been preserved.

The right lower third molar is erupted. This tooth appears to have erupted a short time before death. As the distal part of the left half of the lower jaw is missing, it is not known whether the third molar of the left side had erupted or not.

⁴ The distal part of radius is missing.

⁵ The lower extremity of femur is lost.

⁶ The distal section of ulna is missing.

⁷ See Flecker, H. Time of appearance and fusion of ossification centers as observed by roentgenographic methods. *The American Journal of Roentgenology and Radium Therapy*, vol. 47, no. 1, 1942, pp. 97-159.

Skeleton No. C-2: The morphology of the cranial and postcranial bones shows that this skeleton belongs to a male individual. In the skull pars bregmatica and the partially preserved pars verticis of the sagittal suture and the preserved pars bregmatica and pars complicata of the coronal suture are completely open on both the external and internal sides. The occipital bone of this skull is missing.

The distal epiphysis of the femur, as well as the proximal and distal epiphyses of the tibia have not yet united with the diaphysis.⁸ The epiphyses on the tuberosities of the right and left calcaneus have been closed to a large extent. This epiphysis is only open in the upper part. The proximal epiphysis of the left first metatarsal bone is also to a very large extent fused. Only a short crack at the upper-inner corner denotes that the union has not been completed. According to Flecker's figures for males, this skeleton belongs to an individual of approximately 17 years of age.⁹

Twenty-four isolated permanent teeth of this individual are in hand. Among the permanent upper molars only the left wisdom tooth is lacking. Of the permanent lower molars right and left first molars and the right second molar have been preserved. In the three-rooted right upper third molar, the roots have completed half of their development. The condition of its roots shows that an important part of the crown of this tooth had protruded out of its alveolus. Furthermore, a small contact facet is observed on the distal surface of the right upper second molar, approximately half way between the enamel margin and the chewing surface. This contact facet also shows that an important part of the right upper third molar had erupted. There is also a small contact facet at about the middle of the distal surface of the left upper second molar. This contact facet shows that an important portion of the missing left upper wisdom tooth also had erupted. A small contact facet is seen just below the chewing surface on the distal surface of the right lower second permanent molar. This contact facet is evidence that at least the largest part of the now missing right lower wisdom tooth had erupted. The closer proximity of the contact facet to the chewing surface in the right lower second molar than those found in the upper second

⁸ The proximal extremities of the right and left femurs are missing.

⁹ See Flecker, 1942.

molars, indicates that the right lower wisdom tooth had appeared earlier or erupted faster than the upper third molars. As the left lower second molar is missing, I am not able to say anything about the state of eruption of the left lower wisdom tooth.

In my previous study I had stated that amongst the skeletons from the Chalcolithic and Copper Ages of Anatolia, in 16 of 17 crania belonging to individuals of 20-22 years of age the wisdom teeth had erupted.¹⁰ The condition existent in these skeletons of 20-22 years of age and in the Yazılıkaya skulls Nos. V and C-2, again belonging to the Copper Age, shows that in at least a great majority of the Chalcolithic and Copper Age populations of Anatolia the third molars had erupted before the age of twenty.

It is known that in the Mesolithic Afalou people of Northwest Africa the wisdom teeth also had erupted very early.¹¹ The wisdom teeth had also erupted early in at least a part of the Mesolithic inhabitants of the Island of Tévéc, in Western Europe.¹² Thus it is seen that in Afalou and Tévéc peoples and in the Chalcolithic and Copper Age inhabitants of Anatolia the third molars had appeared relatively early.

Suk has determined that in a very great majority of the recent Zulus of South Africa the wisdom teeth erupt before the age of twenty.¹³

¹⁰ Şenyürek, 1956, p. 21. In the one skeleton mentioned (Kumtepe No. 2) the left lower third molar has not formed (for details see Şenyürek, 1956, p. 5).

¹¹ See Arambourg, C., Boule, M., Vallois, H. and Verneau, R. Les grottes paléolithiques des Beni-Segoual (Algérie). Archives de l'Institut de Paléontologie Humaine, Mémoire 13, Paris, p. 146.

¹² See Péquart, Marthe and Saint-Just, Boule, M. and Vallois, H. Tévéc, station-nécropole mésolithique du Morbihan. Archives de l'Institut de Paléontologie Humaine, Mémoire 18, Paris, p. 138; Şenyürek, M. A review of the order of eruption of the permanent teeth in fossil hominids. Belleten, vol. XIX, no. 76, 1955, p. 434.

¹³ See Suk, V. Eruption and decay of permanent teeth in Whites and Negroes, with comparative remarks on other races. American Journal of Physical Anthropology, vol. II, no. 4, 1919, pp. 360-362.

Regarding the eruption of wisdom teeth in modern Filipinos, Bean (Bean, R. B. The stature and the eruption of the permanent teeth of American, German-American and Filipino children. Deductions from the measurements and examination of 1445 Public School children in Ann Arbor, Michigan, and 776 in Manila, P. I. The American Journal of Anatomy, vol. 17, 1914-1915, p. 132) states: "*The third molars begin to appear in the Filipinos at the age of 13, and from 61 per cent to 83 per cent of the third molars have erupted in the Filipinos at the age of 20 and over.*"

On the other hand, it is known that in an important portion of the recent Whites the eruption of the third molars is retarded till after the age of twenty.¹⁴

In this connection I consider it useful to refer briefly to a research I have been carrying out on the time of eruption of the wisdom teeth in the modern Turks. I have up-to-date investigated the state of eruption of the wisdom teeth in 239 students of both sexes, in the Faculty of Language, History and Geography of the University of Ankara. The results obtained so far are shown in the appended table.

This table shows that from the age of 17 upwards the percentage of students with no permanent teeth erupted diminishes, while the percentage of those with all four wisdom teeth erupted, or erupting, increases. Again from this table it is seen that in 36.7—55.5 per cent of the students under 20 and in 23 per cent of those between the ages of 20 - 22, none of the wisdom teeth have appeared. The investigation I am doing on this subject is not yet finished and will be published in detail after it is completed. Still, even the present small series indicates that in an important part of modern Turks the wisdom teeth erupt after the age of twenty.

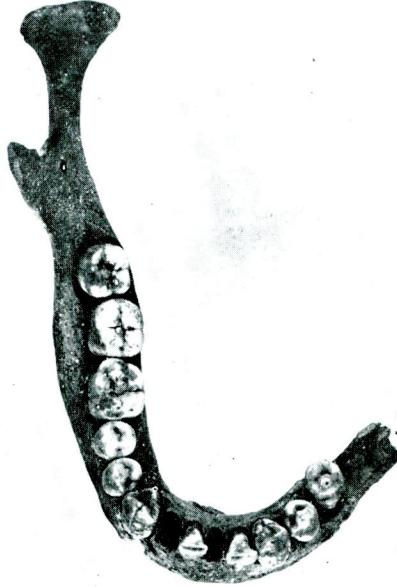
The fact that the wisdom teeth appeared relatively early in Afalou and Téviéc peoples and in the Chalcolithic and Copper Age inhabitants of Anatolia while in an important portion of recent Whites they erupt after the age of twenty, shows that during the last 4000 years a retardation has occurred in the eruption of the wisdom teeth in the White stock.

¹⁴ For the eruption time of the wisdom teeth in recent Whites see: Broca, P. *Instructions craniologiques et craniométriques*. Mémoires de la Société d'Anthropologie de Paris, vol. II, Series 2, 1875, p. 131; Broca, P. *Instructions relatives à l'étude anthropologique du système dentaire*. Bulletins de la Société d'Anthropologie de Paris, 1879, pp. 136-138; Magitot, in *Bulletins de la Société d'Anthropologie de Paris*, 1879, p. 156; Bean, 1914-1915, p. 132; Suk, 1919, pp. 369-370; Hellman, M. *Our third molar teeth, their eruption, presence and absence*. Dental Cosmos, vol. 78, 1936, pp. 750-762.

T A B L E

The Eruption of the wisdom teeth in modern Turks
(Figures in parentheses are the percentages)

Age	Number of individuals studied	None of the third molars erupted	1-3 third molars erupted or erupting	4 third molars erupted or erupting
17	9	5 (55.55)	3 (33.33)	1 (11.11)
18	22	11 (50.00)	8 (36.36)	3 (13.63)
19	49	18 (36.73)	17 (34.68)	14 (28.57)
20 - 21 - 22	87	20 (22.98)	30 (34.48)	37 (42.52)
23 - 24 - 25	43	6 (13.95)	13 (30.23)	24 (55.81)
26 - X	29	2 (6.89)	11 (37.93)	16 (55.17)



Res. 1. V numaralı Yazılıkaya alt çenesinin yukarıdan görünüşü.
Fig. 1. The mandible No. V from Yazılıkaya seen from above.

