









WILLIAMS BEUREN SYNDROME, A SHORT COMMUNICATION OF A PECULIAR CASE

Michele Callea¹ , Mehmet Sinan Dogan² , Silvia Vierucci¹ , Marwa Abd El Salam³ , Roberta D'Avenia¹ 
, Francisco Cammarata Scalisi⁴ , Pamela Armi¹ , Elena Benedetti¹ 

1. Pediatric Dentistry and Special Dental Care Unit, Meyer Children's Hospital, Florence, Italy.
2. Department of Pediatric Dentistry, Harran University, Şanlıurfa, Türkiye.
3. Pediatric Dentistry Unit, Nile oh Hope Hospital, Alexandria, Egypt.
4. Regional Hospital of Antofagasta, Antofagasta, Chile.

*Corresponding author: Callea M, MSc. PhD, Department of Pediatric Dentistry, Special Dental Care Unit, Meyer Children's Hospital, Florence, Italy.,
E-mail : michele.callea@meyer.it mcallea@gmail.com
DOI:10.61139/ijdor.1282877

Abstract

Williams-Beuren syndrome (WBS) is a rare congenital disorder that includes cardiovascular problems, mental retardation, distinctive facial features and dental anomalies. This case report the treatment of a tooth fracture after dental trauma in a 13-year-old male with WBS syndrome. Intraoral clinical examination revealed anterior interdental space and enamel hypoplasia in incisors. Dental treatment included: The fracture tooth fragment was restored after basic behavioral orientation.

Case Report (HRU Int J Dent Oral Res 2023; 3(2): 108-111

Keywords: Williams-Beuren syndrome, tooth fracture, tooth anomalies.

Introduction

Williams-Beuren syndrome (WBS), is a rare congenital disorder involving cardiovascular problems, mental retardation, distinctive facial features and tooth anomalies. Williams-Beuren syndrome is caused by hemizygous deletion of 1.5 to 1.8 Mb on chromosome 7q11.23, which contains approximately 28 genes. (1-7) The prevalence of WBS is estimated to be one in every 7,500 live births. The disorder occurs equally in both sexes. There is no ethnic or racial discrimination.(8)

Intraoral findings of this syndrome include malocclusion, micrognathism, hypodontia, enamel

hypoplasia, microdontia, short roots, diastema, pulp stones and conical teeth.(8,9)

In addition, poor fine motor skills in these patients cause difficulties in maintaining dental hygiene and increase the risk of dental caries. It is recommended to have dental check-ups up to the age of 1 or within 6 months after the first tooth erupts. Dental cleaning is recommended every 4 months. Caregivers should be instructed to assist with brushing and flossing.(10) The main complications in the dental treatment of the patients with WBS are heart disease and behavioral disorder. Cardiovascular diseases occur in 80% of WBS individuals.(11) For these reasons, WS-specific sedation and anesthesia recommendations

should be followed if dental procedures require anesthesia. (10)

Case Reports

We report on a case of a 13-year-old young male affected by WBS who had a fracture of 1.1. In order to make the restoration of the central incisor the rubber dam has been applied with a good compliance. (Figure 1-3); He had no cardiopathies, no tooth agenesis, a good compliance.

Table 1 summarized all clinical features related to WBS along with inheritance pattern (1-7)

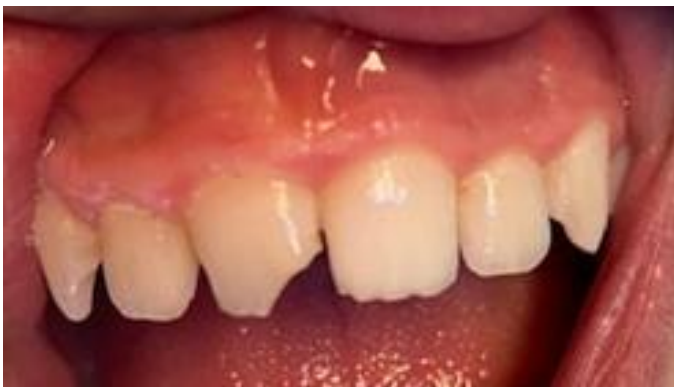

Figure 1: Fracture of 1.1

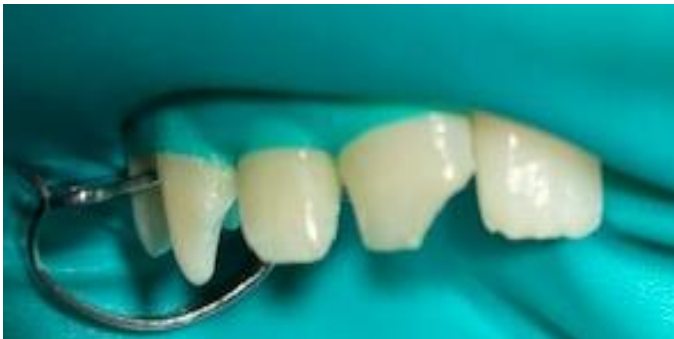

Figure 2: Tooth isolated with rubberdam

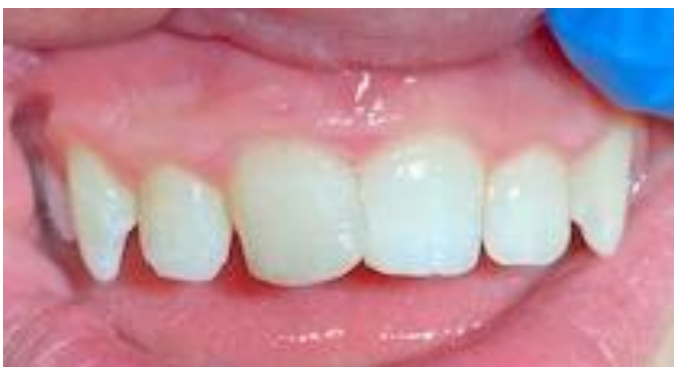

Figure 3: Tooth aesthetically reconstructed by final result after polishing

Discussion

Williams syndrome pose challenges for several reason such as behavioral management foreseen fur such patients along with the anesthesiologic issues. The peculiarities of these cases are represented by the incoming event of the traumatic dental injury and the behavioral management of an entity usually difficult to treat due to scarce collaboration. (1-7)

S. Axelsson et al. reported in a study conducted on patients with WS, they found hypodontia, diastema, microdontia, and conical incisor anomalies.(12) This patient had some of these features, such as anterior open bite, tongue thrust, excessive interdental space, and hypoplasia. In this patient, a crown fracture occurred in the maxillary incisor as a result of dental trauma due to poor motor skills.

Patients with WBS syndrome may also have visual impairment, sensorineural hearing loss, hyperacusis, photophobia and hoarseness. Anterior open bite, tongue thrust, excessive interdental space, enamels hypomineralization in incisors, hypoplasia and caries lesions can be seen in intraoral clinical examination. Anxiety can be seen due to aversion to sounds and photophobia during dental treatment. Dental fear can be reduced with modulating sessions. Oral hygiene education and use of 0.05% sodium fluoride mouthwash are important.(13) This patient had a conical tooth anomaly in the upper incisors.

Conclusion

We report on a rare case of WBS syndrome highlighting with a sequence of imagines the trauma management and treatment choice of such a rare entity.

Table 1: summarize clinical features of Williams Beuren syndromes along with molecular basis and inheritance pattern

-	INHERITANCE
-	-Autosomal dominant
-	GROWTH
-	<i>Height</i>
-	-Short stature
-	<i>Weight</i>
-	- Abnormal weight gain

- <i>Other</i>
- - Intrauterine growth retardation (IUGR)
- HEAD & NECK
- <i>Face</i>
- - Medial eyebrow flare
- - Flat midface
- - Periorbital fullness (puffy eyes)
- - Epicanthal folds
- - Long philtrum
- <i>Ears</i>
- - Sensorineural hearing loss, mild to moderate
- - Hyperacusis
- - Phonophobia
- - Abnormal brain auditory evoked responses (BAER)
- - Decreased or absent ipsilateral acoustic reflex response to maximum stimulation
- <i>Eyes</i>
- - Stellate pattern of iris
- - Strabismus
- - Altered visual acuity
- <i>Nose</i>
- - Depressed nasal bridge
- - Anteverted nares
- <i>Mouth</i>
- - Thick lips
- <i>Teeth</i>
- - Hypodontia
- - Microdontia
- CARDIOVASCULAR
- <i>Heart</i>
- - Supravalvular aortic stenosis
- - Valvular aortic stenosis
- - Bicuspid aortic valve
- - Mitral valve prolapse
- - Mitral regurgitation
- - Coronary artery stenosis
- - Pulmonary valve stenosis
- - Atrial septal defect
- - Ventricular septal defect
- <i>Vascular</i>
- - Peripheral pulmonary artery stenosis
- - Systemic hypertension
- RESPIRATORY
- <i>Larynx</i>
- - Vocal cord paralysis
- CHEST
- <i>Ribs Sternum Clavicles & Scapulae</i>

- - Pectus excavatum
- ABDOMEN
- <i>External Features</i>
- - Inguinal hernia
- <i>Gastrointestinal</i>
- - Chronic constipation
- - Diverticulosis
- - Colic
- - Difficulty feeding
- - Gastroesophageal reflux
- - Textured-food intolerance
- GENITOURINARY
- <i>Kidneys</i>
- - Small kidneys
- - Solitary kidney
- - Pelvic kidney
- - Nephrocalcinosis
- - Renal insufficiency
- - Renal artery stenosis
- <i>Ureters</i>
- - Vesicoureteral reflux
- <i>Bladder</i>
- - Bladder diverticula
- - Urethral stenosis
- - Recurrent urinary tract infections
- - Voiding frequency/urgency
- - Enuresis
- - Delayed toilet training
- SKELETAL
- - Joint contractures
- - Joint laxity
- - Osteopenia
- - Osteoporosis
- <i>Spine</i>
- - Kyphoscoliosis
- <i>Limbs</i>
- - Joint limitation
- <i>Feet</i>
- - Hallux valgus
- SKIN, NAILS, & HAIR
- <i>Skin</i>

- -Decreased skin stiffness
- -Easier stretching
- -Soft skin
- -Increased wrinkles
- -Abnormal scarring
- - Less pressure required to lift skin
- - Longer retraction time after stretching
- - Decreased viscoelasticity
- - Premature aging, mild
- <i>Nails</i>
- - Hypoplastic nails
- <i>Hair</i>
- - Premature graying
- NEUROLOGIC
- <i>Central Nervous System</i>
- - Mental retardation (average IQ 56)
- - Relative sparing of language
- - Poor visual-motor integration (Range 41-80)
- - Poor visual-spatial construction
- - Hypersensitivity to sound
- - Hypotonia
- - Hyperreflexia (particularly in lower extremities, more prevalent in adolescents and adults)
- - Poor balance
- - Poor coordination
- - Type I Chiari malformation
- <i>Behavioral Psychiatric Manifestations</i>
- - Attention deficit disorder
- - Friendly personality
- - Gregarious
- - Cocktail party personality
- - Strong attraction to music
- - Anxiety
- - Phobias
- - Obsessive-compulsive traits
- VOICE
- - Harsh, brassy, or hoarse voice
- ENDOCRINE FEATURES
- - Hypercalcemia
- - Glucose intolerance
- - Diabetes mellitus
- - Early-onset puberty (menarche about 2 years

early)
- Hypothyroidism, subclinical
- LABORATORY ABNORMALITIES
- - Hemizygous deletion at 7q11.23
- MISCELLANEOUS
- - Incidence 1 in 8,000 live births
- - Main aspects of phenotype attributed to defects in GTF2IRD1 (604318) and GTF2I (601679)
- MOLECULAR BASIS
- - Contiguous gene syndrome resulting from hemizygous deletion 1.5 - 1.8 Mb on 7q11.2

References

1. Ferreira SB, Viana MM, Maia NG, Leão LL, Machado RA, Coletta RD, de Aguiar MJ, Martelli-Júnior H. Oral findings in Williams-Beuren syndrome. *Med Oral Patol Oral Cir Bucal*. 2018;23(1):e1-e6
2. Matsuno S, Tsuji M, Hikita R, Matsumoto T, Baba Y, Moriyama K. Clinical study of dentocraniofacial characteristics in patients with Williams syndrome. *Congenit Anom (Kyoto)*. 2019;59(5):162-168.
3. Cogulu D, Hazan F, Dindaroglu FC. Orofacial Findings and Dental Management of Williams Syndrome. *Genet Couns*. 2015;26(4):437-42.
4. Hertzberg J, Nakisbendi L, Needleman HL, Pober B. Williams syndrome--oral presentation of 45 cases. *Pediatr Dent*. 1994;16(4):262-7.
5. Castro T, de Paula Martins Santos C, de Oliveira Lira Ortega A, Gallottini M. Oral characteristics and medical considerations in the dental treatment of individuals with Williams syndrome. *Spec Care Dentist*. 2019;39(2):108-113.
6. Axelsson S, Bjørnland T, Kjaer I, Heiberg A, Storhaug K. Dental characteristics in Williams syndrome: a clinical and radiographic evaluation. *Acta Odontol Scand*. 2003;61(3):129-36.
7. Axelsson S. Variability of the cranial and dental phenotype in Williams syndrome. *Swed Dent J Suppl*. 2005;(170):3-67.
8. Çitir M, Zengin AZ. Multiple Unerupted and Supernumerary Teeth in a Patient with Williams-Beuren Syndrome: An Unusual Case. *Turkiye Klinikleri. Dishekimligi Bilimleri Dergisi*, 2019;25(3): 371-374.
9. Hertzberg J, Nakisbendi L, Needleman HL, Pober B. Williams syndrome--oral presentation of 45 cases. *Pediatr Dent*. 1994;16(4):262-267
10. Morris CA, Braddock SR, AAP COUNCIL ON GENETICS. Health Care Supervision for Children With Williams Syndrome. *Pediatrics*. 2020;145(2):e20193761
11. Andrade NS, Santos C, Castro T, Gallottini M. Medical considerations in dental treatment of patients with Williams-Beuren syndrome: report of four clinical cases. *Clin Lab Res Dentistry*. 2015; 21: 7.
12. Stefan Axelsson, Tore Bjørnland, Inger Kjær, Arvid Heiberg, Kari Storhaug (2003) Dental characteristics in Williams syndrome: a clinical and radiographic evaluation, *Acta Odontologica Scandinavica*, 2003;61(3): 129-136.
13. Torres CP, Valadares G, Martins MI, Borsatto MC, Díaz-Serrano KV, de Queiroz AM. Oral findings and dental treatment in a child with Williams-Beuren syndrome. *Braz Dent J*. 2015;26(3):312-6.