

## A Case of Congenital Rectourethral Fistula, Urethral Dilatation and Segmental Urethral Agenesis Encountered in a Calf\*\*

Sadık YAYLA\*<sup>1</sup>, Engin KILIÇ<sup>1</sup>, Vedat BARAN<sup>1</sup>, Hasan ÖZEN<sup>2</sup>

<sup>1</sup>Kafkas University, Faculty of Veterinary, Department of Surgery, Kars, Turkey.

<sup>2</sup>Kafkas University, Faculty of Veterinary, Department of Pathology, Kars, Turkey.

Geliş Tarihi: 19.11.2015

Kabul Tarihi: 08.02.2016

**Abstract:** The purpose of this case presentation is to describe multiple urogenital system anomalies in a calf. The case was a month old male Simmental calf that was brought to the clinic with a problem of progressive congenital swelling between the perianal and scrotal area. Clinical examination revealed that the swelling was quite large and tight in tendency. A rectourethral fistula was identified during examination of anus by speculum. Ultrasonographic examination of swelling was composed of a luminal structure. Upon puncture of the structure, a blurry liquid content with a foul smell came out. Surgery was performed under intrathecal anesthesia. The mass was clearly distinguishable from surrounding tissue starting from arcus ischiadicus to postscrotal level and it was also very tight. Mass totally removed to include a part intact penile tissue in the proximal and distal, and it was made to uretostomi in proksimal. Nothing was performed on rectourethral fistula. A week long temporary catheter was used for urethra. At the end of the surgery it was observed that urine was continuously coming out of catheter. In macroscopic assessment of the mass, urethra was opening out to the mass in proximal, while there was no urethral opening in distal. Histopathological examination revealed that the urethral structure was composed of single layer of epithelial cells. In conclusion, this case of rectourethral fistula along with mega urethral dilatation and segmental urethral agenesis was found to be worth of description to contribute to the literature.

**Keywords:** Congenital rectourethral fistula, urethral dilatation, segmental urethral agenesis, calf

### Bir Buzağıda Karşılaşılan Doğmasal Rektouretral Fistül, Üretral Dilatasyon ve Segmental Üretral Ajenezi

**Özet:** Bu sunum ile bir buzağıda karşılaşılan çoklu ürogenital sistem anomalisinin bildirilmesi amaçlandı. Olgumuzu perianal bölgeden skrotal bölgeye kadar uzanan, doğuştan beri var olduğu ve gittikçe büyüdüğü belirtilen bir şişkinlik şikâyeti ile kliniğimize getirilen 1 aylık, simmental ırkı bir buzağı oluşturdu. Klinik muayenede şişkinliğin oldukça geniş ve gergin bir yapıda olduğu belirlendi. Anüsün spekulumla muayenesinde rektouretral bir fistülün varlığı belirlendi. Ultrasonografik muayenede şişkinliğin lumenli bir yapıdan oluştuğu saptandı. Punksiyonda ise bulanık ve oldukça pis kokulu bir sıvı görüldü. İntratekal anestezi altında operasyonla kitleye ulaşıldı ve kitlenin arcus ischiadicustan postscrotal düzeye kadar balon şeklinde çevre dokulardan rahatlıkla ayırt edilebildiği ve oldukça gergin bir yapıda olduğu belirlendi. Kitle proksimalde ve distalde bir kısım sağlam penis dokusunu da içerecek şekilde total olarak uzaklaştırıldı ve proksimal noktada üretostomi yapıldı. Rektouretral fistüle ise herhangi bir müdahalede bulunulmadı. Üretraya bir hafta süre ile geçici bir katater uygulandı. Operasyon bitiminde idrarın kataterden sürekli aktığı gözlemlendi. Kitlenin makroskobik olarak değerlendirilmesinde proksimalde üretranın kitleye açıldığı, distalde ise üretral açıklığın olmadığı tespit edildi. Histopatolojik incelemede ise tek katlı epitel hücrelerden oluşan üretra yapısında olduğu anlaşıldı. Sonuç olarak, rektouretral fistül ile birlikte mega düzeydeki üretral dilatasyon ve segmental üretral agenezisi saptanan ve oldukça ilgi çekici olan bu vakanın literatüre katkı sağlayacak nitelikte olduğu düşüncesindeyiz.

**Anahtar Kelimeler:** Doğmasal rektouretral fistül, üretral dilatasyon, segmental üretral ajenezi, buzağı

### Introduction

Anomalies of the digestive system and urogenital system are seen in many species of domestic animals. Among these anomalies, atresia ani, rectovaginal fistula and colon agenesis are quite common, while rectourethral fistula, agenesis and ectopia are rarely seen. It has been stated by various authors that multiple congenital anomalies may also

occur concomitantly in an animal (Ozturk et al., 2002; Kilic et al., 2005; Kilic et al., 2006; Sindak et al., 2010; Durmus and Cinar, 2011). While the cause of most congenital anomalies cannot be determined definitively, it is thought to be linked to genetic factors such as mutations and chromosomal defects, viral and bacterial infections, intoxication, nutrition during the intrauterine period, the rectal palpation

done in the early stages of pregnancy, and environmental factors (Kilic et al., 2005; Kilic et al., 2006; Durmus and Cinar, 2011). This case presentation reports multiple anomalies of the urogenital system consisting of rectourethral fistula, urethral dilatation and segmental urethral agenesis encountered in a calf and also describes the results of treatment.

### Case Presentation

A male one-month-old Simmental calf that was referred to the surgery clinic of Veterinary Faculty, Kafkas University had a history of congenital swelling between perianal and scrotal area. The history of calf included a small bulging in the perianal region at birth, which continued growing in volume and reached the scrotal region within one month (Figure 1). Moreover, the urination and defecation together or separately were succeeded from the anus. After the physical and ultrasonographic examination (Figure 2-3), the mass was exposed during the operation carried out under intrathecal anesthesia [20 mg (4 ml) of hyperbaric bupivacaine HCl (Marcaine Spinal Heavy 0.5 per cent, Astra Zeneca) injected into the lumbosacral intervertebral space (L6-S1)] following sedation (0.2 mg/kg of xylazine HCl, Rompun, Bayer S/A, intramuscularly). The mass was removed (Figure 4), including a section of healthy penis tissue proximally and distally, and an urethrostomy was performed in the region of the ischial arch. Although no procedure was performed on the rectourethral fistula, a temporary catheter obtained from serum infusion set was applied to the urethra and was left there for a week. For postoperative care of the calf, a suitable antibiotic agent (10,000 IU benzilpenicillin prokain, 10 mg dihidrostreptomycin sulphate, Reptopen S, CEVA-DIF) kg/WA for seven days after the operation and daily nursing procedure was also done. Clinical examination of the bulging structure revealed a localization extending from the perianal region to the scrotal region. At palpation, a fluctuant content and tight structure was noted. In examination of the preputium, phimosis was as well detected. Examination of the anus using a speculum revealed a rectourethral fistula (Figure 2). In ultrasonographic examination, the bulging structure was recognized to contain a lumen (Figure 3), and upon puncture, cloudy liquid with quite an unpleasant smell was seen to discharge. It was determined that the balloon-shaped mass was extending from the ischial arch to the postscrotal region, and was easily

distinguishable from the surrounding tissue. It was also connected to the penis tissue. At the end of the surgery, a continuous flow of urine from the catheter was observed. As the catheter was removed a week later, no urine flow from the anus was observed. Therefore, successful urination from urethra was seen to be accomplished as a result of the surgery (Figure 5).

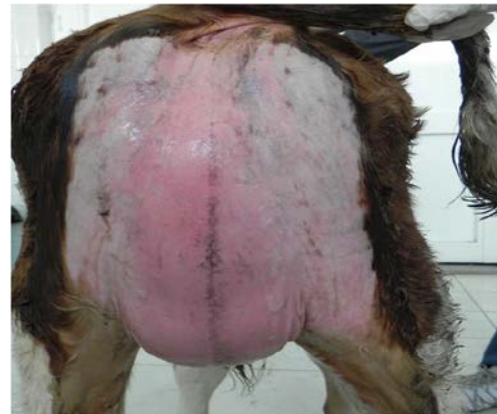

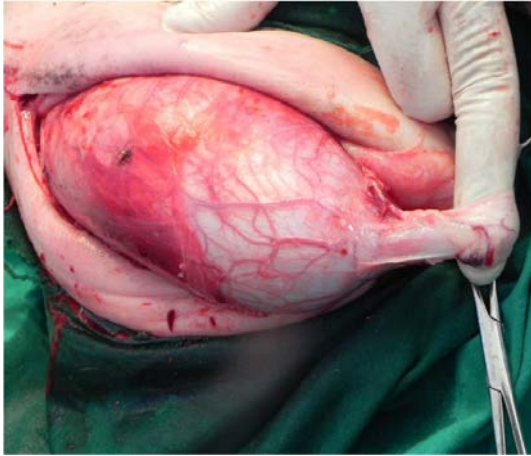
Figure 1. Out view of the the calf: swelling between perianal and scrotal area.

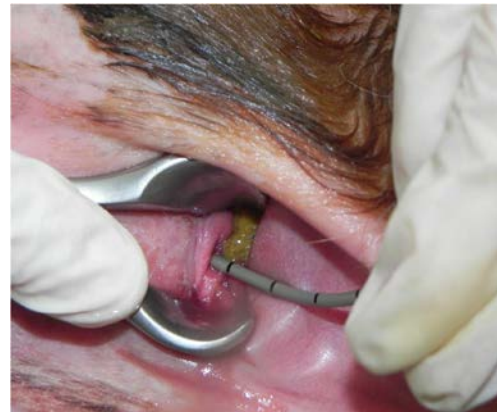

Figure 2. Determination of the rectourethral fistula.

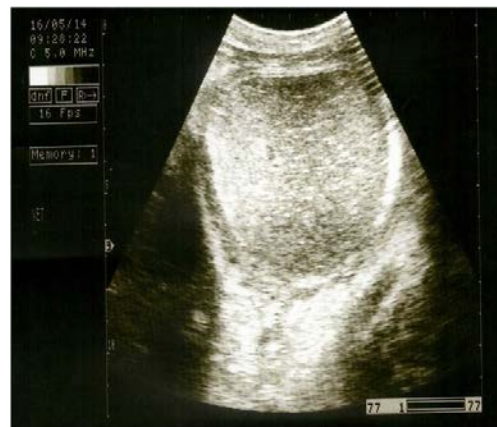

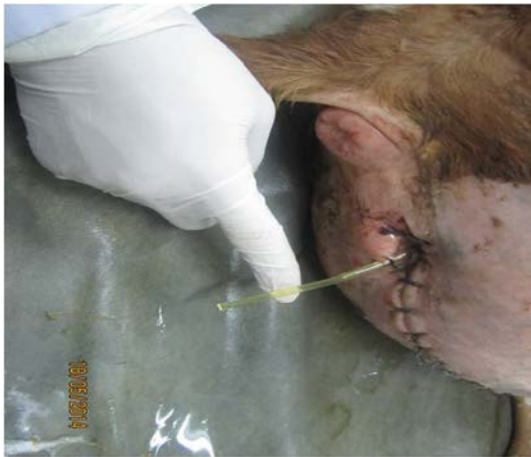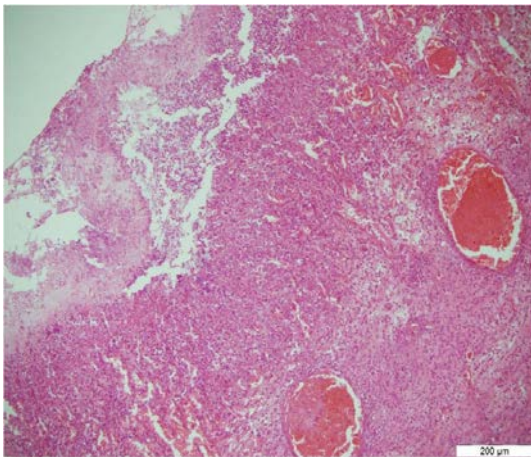
Figure 3. Note the dilated urethra in ultrasonography.



**Figure 4.** View of the mega-level dilated urethra during intraoperation.



**Figure 5.** Postoperative view of the calf.



**Figure 6.** Microscopic view of section taken from the urethra; severe degradation of the lamina epithelialis due to infection and intense neutrophil leukocyte infiltration.

Macroscopic assessment of the mass revealed that proximally the urethra opened up to the mass and distally there was no urethral opening. Tissue samples collected from the bulging structure during the surgery was fixed in 10% neutral buffered formalin and then embedded in paraffin. Sections cut from the paraffin blocks were routinely stained with hematoxylin and eosin for microscopic evaluation. It was recognized that the inner lining of the mass had a urethral structure composed of a single layer of epithelial cells. However, due to the inflammatory reaction, severe degradation and heavy infiltration of neutrophilic leukocytes were detected in the lamina epithelialis (Figure 6). At the end of the evaluations, a rectourethral fistula and in addition to mega urethral dilatation, distal segmental urethral agenesis was detected in the present case.

### Discussion

It has been noted that just as in other species of domestic animals, anomalies of the urogenital system such as urethral stenosis, dilatation, diverticulum, atresia; epispadias and hypospadias; and penis aplasia, hypoplasia and preputial aplasia, as well as atresia ani and rectovaginal fistula can occur in calves as well (Ozturk et al., 2002; Kilic et al., 2005; Kilic et al., 2006; Bademkiran et al., 2009; Krishna et al., 2009; Sindak et al., 2010; Durmus and Cinar 2011; Shakoor et al., 2012). At the end of the evaluation of the current case, a rectourethral fistula, mega urethral dilatation and distal segmental urethral agenesis was detected. It was speculated that despite the fact that the calf could urinate and defecate from the anus, urethral dilatation was caused due to the accumulation of urine mixed with feces in the dilated urethra and the inability of the content to be emptied due to distal urethral agenesis. The purpose of treating gastrointestinal and urogenital anomalies is usually to enable to animal to live until it is ready to be butchered (Ozturk et al., 2002; Kilic et al., 2005; Kilic et al., 2006). Continuous follow up of the case showed the animal kept on living without any complications.

In conclusion, the present case was considered interesting and worth of presenting due to the extent and localization of the structure, and diagnosis and the treatment processes followed. We hope that the case would contribute to literature and practice where such anomalies are present.

## References

- Bademkiran S, Icen H, Kurt D, 2009: Congenital recto vaginal fistula with atresia ani in a heifer: A case report, *YYU Journal of Veterinary Faculty*, 20 (1), 61-64.
- Durmus AS, Cinar HN, 2011: A case of rectovaginal fistula, atresia ani and perosomus elumbus in a calf. *FU Sag Bil Vet Derg*, 25 (1), 43-47.
- Kilic E, Ozturk S, Aksoy O, Ozaydin I, Ozba B, Dag-Erginsoy S, 2005: Preputial aplasia, uretral diverticulum and distal uretral atrazia in kids. *Kafkas Univ Vet Fak Derg*, 11 (1), 73-76.
- Kilic E, Ozaydin I, Aksoy O, Yayla S, Sozmen M, 2006: Multiple urogenital system anomalies in three calves. *Kafkas Univ Vet Fak Derg*, 12 (2), 193-197.
- Krishna H, Prasad VD, Rao M, 2009: Agenesis of vulva and terminal urethra with atresia ani et recti in a buffalo calf. *Buffalo Bulletin*, 28 (4), 165-167.
- Ozturk S, Kilic E, Aranci A, Uygunturk A, 2002: A case of aplasia penis, anorchidism and uretral dilatation in a Montafon calf. *Kafkas Univ Vet Fak Derg*, 8 (1), 63-65.
- Shakoor A, Muhammad SA, Younus M, Kashif M, 2012: Surgical repair of congenital recto-vaginal fistula with atresia ani in a cow calf. *Pak Vet J*, 32(2), 298-300.
- Sindak N, Sahin T, Biricik HS, 2010: Urethral dilatation, ectopic testis, hypoplasia penis, and phimosis in a kilis goat kid. *Kafkas Univ Vet Fak Derg*, 16 (1), 147-150.

\*\* Presented as a poster at the 14<sup>th</sup> National Congress of Veterinary Surgery (23-26 October, 2014, Antalya)

\* **Corresponding Author:** Sadık YAYLA  
Kafkas University, Faculty of Veterinary Medicine,  
Department of Surgery, Kars, Turkey.  
e-mail: sadikyayla@gmail.com