

## A different treatment approach for Bovine papillomavirus in an Arabian horse

Yakup Sinan Orta<sup>1</sup>, Mehmet Kale<sup>1</sup>, Sibel Hasircioglu<sup>1</sup>, Yakup Yildirim<sup>1</sup>, Ozlem Ozmen<sup>2</sup>, Kamil Atli<sup>1</sup>

<sup>1</sup>Department of Virology, Faculty of Veterinary Medicine, Burdur Mehmet Akif Ersoy University, Burdur, Türkiye

<sup>2</sup>Department of Pathology, Faculty of Veterinary Medicine, Burdur Mehmet Akif Ersoy University, Burdur, Türkiye

### Key Words:

arabian horse  
Bovine papillomavirus  
diagnosis  
PCR  
treatment

Received : 26.04.2023  
Accepted : 24.07.2023  
Published Online : 31.08.2023  
Article Code : 1288345

### Correspondence:

YS. ORTA  
(y.sinanorta@gmail.com)

### ORCID

YS. ORTA : 0000-0002-6918-4819  
M. KALE : 0000-0003-4156-1077  
S. HASIRCIOGLU : 0000-0002-5436-0795  
Y. YILDIRIM : 0000-0003-4299-4712  
O. OZMEN : 0000-0002-1835-1082  
K. ATLI : 0000-0002-2266-4372

### ABSTRACT

A wart lesion was observed near the anus of a female Arabian horse housed in a private equine facility in Bucak District of Burdur Province. During the histopathological examination of the mass, equine sarcoid was revealed. Polymerase chain reaction (PCR) revealed the presence of bovine papillomavirus (BPV) type 10 and type 12 viral genomes in the tissue. It was observed that the combined treatment approach of PAPILEND™ cream + Zylexis™ + Alquer mold™ premix powder was beneficial in treating the sarcoid associated with BPV type 10 and type 12 on the anal region. No recurrence of the lesion was observed during the 6-month follow-up period. In conclusion, it is recommended to diagnose the presence of BPV in horses with warts and to investigate the efficacy of this combined treatment approach in larger populations.

### INTRODUCTION

Bovine papillomavirus (BPV) types 1, 2 and 13 (BPV-1, -2, -13) are known to cause sarcoids in horses and potentially infect other species (Chambers et al., 2003). Although the routes of BPV transmission in the ungulate population are not fully known, possible routes include direct or indirect skin contact, contaminated materials, environmental conditions, airborne flies, and vertical transmission. In horses, BPV lesions are commonly found all around the body, particularly in the paragenital region, thorax-abdomen, and head regions (Torontegui & Reid, 1994). While various treatment approaches for wart lesions caused by BPV have been extensively studied in ruminant animals, there are limited studies focusing on BPV-related warts in horses. Therefore, more research is needed in this area. In this study, the detection of the presence of BPV and the treatment of the tumor in an Arabian horse with an equine sarcoid case are reported using molecular methods, histopathological and immunohistochemical techniques.

### CASE

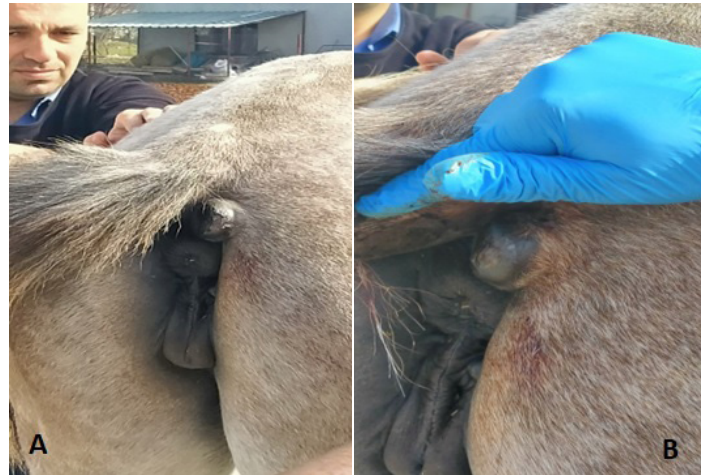In a private equestrian facility in Bucak District of Burdur Province, 3-year-old female Arabian horses, previously used for racing but later sold due to leg nerve injuries, developed wart lesions on the anal wall (Figure 1). After capturing and restraining the animals, a 5g sample of the wart lesion was collected under appropriate conditions. A portion of the sample was fixed in 10% formalin solution for histopathological

and immunohistochemical examinations, while the remaining part was transported to the laboratory in a sterile container under cold chain conditions. This study was approved by the Local Ethics Committee for Animal Care of the Burdur Mehmet Akif Ersoy University (11/04/2023- decision number: E-93773921-770-264906).

The tumor mass was used for histopathological and immunohistochemical examination. The mass fixed in 10% formalin solution, processed routinely and embedded in paraffin. Sections of 5µm thickness were cut using a microtome and stained with Hematoxylin-eosin (HE) examined under a light microscope. For immunohistochemical examination, the sections were mounted on polylysine slides and stained using the streptavidin biotin peroxidase method. The anti-HPV antibody [BPV-1/1H8 + CAMVIR] (ab2417) was used for the detection of the papillomavirus. The Mouse and Rabbit Specific HRP/DAB (ABC) Detection IHC kit (ab64264) and DAB chromogen were used as secondary kits. After counterstaining with Harris Hematoxylin, the prepared slides were covered with a cover slip and examined under a microscope.

Extraction (Qiagen) was performed from the mass, and the sample was analyzed using the conventional polymerase chain reaction (PCR) method with BPV type-specific primers (BPV type 1-type 14).

For treatment, PAPILEND™ cream was applied once a day to the wart area for 10 days. Zylexis™ was administered

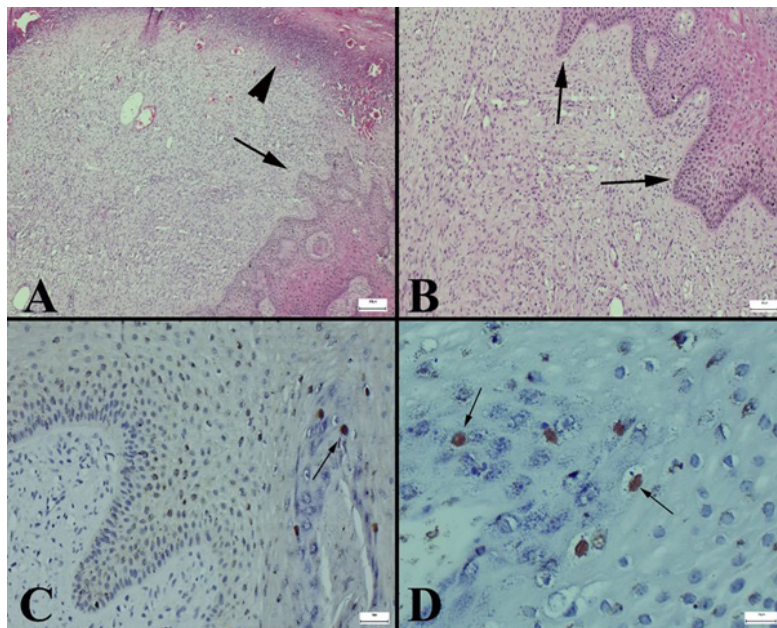


**Figure 1.** A) Gross appearance of the tumor localized near the anus of an Arabian horse.  
B) Close-up view.

intramuscularly at a dose of 2 ml on days 0, 3, and 9 to activate the immune system. Additionally, 150 grams of Alquer mold™ premix powder was added to the animal's daily feed for 10 days.

The histopathological examination of the mass revealed a prominent dermal proliferation of spindle-shaped fibroblasts

exhibited a perpendicular orientation towards the basement membrane. Ulceration and inflammatory cell infiltration were observed on the surface of the mass. Increased vascularity and hyperemic vessels were also noted. In the immunohistochemical examination, positive reactions with papillomavirus were detected in some epithelial cells in the epidermis (Figure 2).

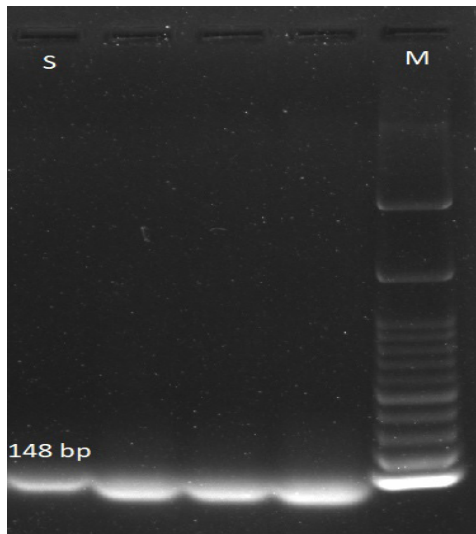


**Figure 2.** A) Histopathological appearance of the fibromatous type equine sarcoid, showing ulcer and inflammatory reaction on top of the mass (arrowhead) and rete peg (arrow). HE, Scale bar = 200µm. B) Higher magnification of rete pegs (arrows). HE, Scale bar = 100µm. C) Positive reaction for papilloma virus (arrows), Streptavidin Biotin Peroxidase method. Scale bar = 50µm. D) Higher magnification of papilloma virus positive epidermal cells (arrows), Streptavidin Biotin Peroxidase method. Scale bar = 100µm.


arranged in a fascicular or interlacing pattern. The epidermis showed widespread hyperplasia, hyperkeratosis, and rete peg formation. Notably, fibroblasts at the dermo-epidermal junc-

The PCR method using BPV type-specific primers (BPV type 1-type 14) applied to the tissue sample confirmed the presence of viral genomes belonging to BPV type 10 (Figure

3) and type 12 (Figure 4). The results were negative for the other types.



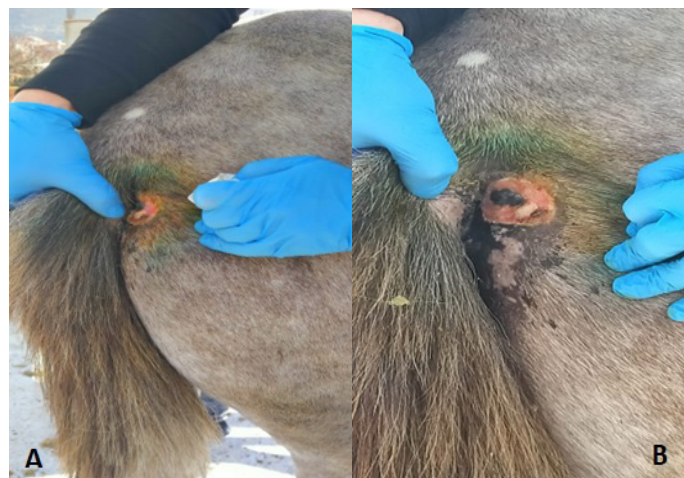**Figure 3.** Detection of BPV type 10 by PCR.



**Figure 4.** Detection of BPV type 12 by PCR.

As a result of the combined treatment with PAPILEND™ cream + Zylexis™ + Alquer mold™ premix powder, regression and healing of the wart area in the anal region were observed (Figure 5). No recurrence of the lesion was observed during the 6-month follow-up period.

recreation in a private riding facility located in an area nearby dairy cattle, is presented. The grazing areas of the horse and the cattle were intertwined, and close contact between the animals was observed. Experimental studies have shown the development of sarcoid-like lesions in horses following inoc-



**Figure 5.** A) Regression of the wart lesion in the anal region of the Arabian horse.  
B) Close-up view

## DISCUSSION

Sarcoids, which are thought to be caused by BPV types of the Deltapapillomavirus genus commonly in horses, are characterized by localized lesions with intense fibroblastic proliferation and epidermal hyperplasia/dysplasia (Nasir & Brandt, 2013). In this case, for the first time, BPV types 10 and 12, which belong to the Xipapillomavirus genus, were detected in a wart that developed in the anal region of a horse. BPV types 10 and 12 genes found in the mass that have generally been detected in cattle mammary, body, and oral lesions in previous studies (Sökel and Kale, 2022; Özmen and Kale, 2023). In this

ulation with BPV, while another study reported no formation of warts (Reid et al., 1994). Therefore, definitive statements cannot be made regarding the transmission of BPV from one horse to another or from cattle to horses. However, BPV DNA has been detected in horses' sarcoid mass and it has been suggested that flies (*Musca autumnalis*) carrying BPV DNA can act as vectors for BPV transmission (Kemp-Symonds, 2000). BPV generally spreads through direct or indirect contact, entering the skin through abrasions and lesions (Özmen and Kale, 2023). Therefore, in the case we examined, we suspect that inter-species transmission of BPV occurred through direct contact or via flies. Histopathological examinations of

equine sarcoids have identified fibroblastic and nodular types as the most common ones (Gebre et al., 2018; Kareem & Salman, 2019). Kareem & Salman (2019) determined that sarcoid prevalence is highest in males between the ages of 3-7. In this case, a fibroblastic-type sarcoid was diagnosed through histopathological examination of the wart in a 3-year-old female riding horse. BPV antigens were detected immunohistochemically in the epidermal cells. It has been found that sarcoids in horses occur most frequently in the head-neck region (51%), trunk and genital region (32.3%), and leg and shoulder areas (16.1%) (Gebre et al., 2018). The localized development of tumors in horses can lead to functional disorders depending on the affected area. As a result, animals may experience issues such as weakness, sensitivity, bleeding, blindness, difficulty in defecation and urination, locomotion problems, difficulties in parturition, feeding, and chewing (Gebre et al., 2018). Currently, there is no standardized method for the treatment of equine sarcoids. However, various treatment methods such as surgical procedures (conventional excision and CO<sub>2</sub> laser excision), cryotherapy, hyperthermia, radiotherapy, chemotherapy, immunotherapy, topical immunomodulation, and antiviral agents are used (Taylor & Haldorson, 2013). The topical cream (PAPILEND™®) used in this case was developed to soften wart-like formations seen in cattle and reduce their adverse effects by inducing hardening. The cream's composition includes glacial acetic acid, salicylic acid, garlic oil, tea tree oil, glyceryl monostearate, stearic acid, cetyl stearyl alcohol, hydrogenated castor oil, podophyllum, and water. It has been reported that some of the ingredients in the cream cause warts to regress and disappear due to their topical cytotoxic and antimetabolic effects (Rivera & Tying, 2004). BPV is not a strong immunogen in mammalian organisms and does not induce significant inflammation, except for local cellular immunity. Therefore, the main objectives in combating the virus include the development of neutralizing antibodies, stimulation of cellular immunity, elimination of infected cells producing early proteins, and exposing keratinocytes to the virus (Araibi et al., 2004). To stimulate the immune system, an immunostimulant called Zylexis™ was used. Vitamin E, selenium, copper, and zinc are important substances for animals in strengthening the immune system against diseases and promoting keratin production (Sökel and Kale, 2022). Therefore, Alquermod™ premix powder was used. The primary goal of topical treatments in equine sarcoid cases is to stimulate a local immune response to eliminate tumor cells.

## CONCLUSIONS

We recommend conducting investigations on BPV cases to explore the sequence and phylogeny, as new types and variants of the virus continue to emerge. In this regard, we suggest diagnosing the presence of BPV in a larger population of animals with equine sarcoid cases and subsequently monitoring the outcomes of this combined treatment approach.

## DECLARATIONS

### Ethics Approval

This study was approved by the Local Ethics Committee for Animal Care of the Burdur Mehmet Akif Ersoy University (11/04/2023- decision number: E-93773921-770-264906).

## Conflict of Interest

The authors declare that they have no conflict of interests.

## Author Contribution

Idea, concept, and design: Y.S., M.K.

Data collection and analysis: Y.S., M.K., O.O.

Drafting of the manuscript: Y.S., M.K.

Critical review: S.H., Y.Y., K.A.

## Data Availability

The data used to prepare this manuscript are available from the corresponding author when requested.

## Acknowledgement

This work was supported by Prof.Dr. Mehmet KALE.

## REFERENCES

1. Araibi, E. H., Marchetti, B., Ashrafi, G. H., & Campo, M. S. (2004). Down regulation of major histocompatibility complex class I in bovine papillomas. *Journal of General Virology*, 85, 2809–2814. [https:// doi: 10.1099/vir.0.80128-0](https://doi.org/10.1099/vir.0.80128-0).
2. Chambers, G., Ellsmore, V. A., O'Brien, P. M. Reid, S. W. J., Love, S., Campo, M. S. & Nasir, L. (2003). Association of bovine papillomavirus with the equine sarcoid. *Journal of General Virology*, 84, 1055–1062. [https:// doi: 10.1099/vir.0.18947-0](https://doi.org/10.1099/vir.0.18947-0).
3. Gebre, D., Gizachewu, A., & Negero, J. (2018). Equine sarcoid: Epidemiology and its clinical impact in working donkeys in selected districts of Central Ethiopia. *Journal of Veterinary Science and Technology*, 9(537), 2. [https:// 10.4172/2157-7579.1000537](https://doi.org/10.4172/2157-7579.1000537).
4. Kareem, M. H., & Salman, S. S. (2019). Types and histopathological characteristics of equine sarcoid. *Online Journal of Veterinary Research*, 23(2), 112-120.
5. Kemp-Symonds, J. G. (2000). The Detection and sequencing of Bovine Papillomavirus type 1 and 2 DNA from *Musca autumnalis* (Diptera: Muscidae) face flies infesting sarcoid-affected horses. MSc Thesis. London, UK: Royal Veterinary College.
6. Nasir, L., & Brandt, S. (2013). Papillomavirus associated diseases of the horse. *Veterinary Microbiology*, 167, 159–167. [https:// doi: 10.1016/j.vetmic.2013.08.003](https://doi.org/10.1016/j.vetmic.2013.08.003).
7. Özmen, G., & Kale, M. (2023). Searching bovine papillomavirus presence in lesions seen on teats of cows. *Pesquisa Veterinária Brasileira*, 43, e07150. <https://doi.org/10.1590/1678-5150-PVB-7150>.
8. Reid, S. W., Gettinby, G., Fowler, J.N., & Ikin, P. (1994). Epidemiological observations on sarcoids in a population of donkeys (*Equus asinus*). *Veterinary Record*, 134, 207–11. [https://doi: 10.1136/vr.134.9.207](https://doi.org/10.1136/vr.134.9.207).
9. Rivera, A., & Tying, S. K. (2004). Therapy of cutaneous human papillomavirus infections. *Dermatologic Therapy*, 17(6), 441-448. [https://doi: 10.1111/j.1396-0296.2004.04047.x](https://doi.org/10.1111/j.1396-0296.2004.04047.x).

10. Sökel, S., & Kale, M. (2022). Sığırların vücutlarında görülen bovine papillomavirus kaynaklı siğillerin virolojik, Patolojik ve klinik açıdan incelenmesi. PhD Thesis, Burdur, Turkey. Burdur Mehmet Akif Ersoy Üniversitesi, Sağlık Bilimleri Enstitüsü.

11. Taylor, S., & Halderson, G. (2013). A review of equine sarcoid. *Equine Veterinary Education*, 25(4), 210-216. <https://doi.org/10.1111/j.2042-3292.2012.00411.x>.

12. Torrontegui, B. O., & Reid, S. J. (1994). Clinical and pathological epidemiology of the equine sarcoid in a referral population. *Equine Veterinary Education*, 6, 85-88. <https://doi.org/10.1111/j.2042-3292.1994.tb01098.x>