



Large intraductal papilloma in the breast: A case report and review of the literature

Aydin Ulaş

Department of General Surgery, Bursa Nev Esentepe Hospital, Bursa, Turkey

Journal of Bursa

Faculty of Medicine

e-ISSN: 2980-0218

Case Report

Clinical Sciences

Received

May 4, 2023

Accepted

May 17, 2023

Published online

September 10, 2023

J Bursa Med 2023;1(3)
99-103

ABSTRACT

Most of the patients who come to the breast clinic present with the complaint of a palpable mass. Some of the pathological lesions that cause this picture are intraductal papillomas. Most intraductal papillomas are smaller than 5 mm. In this article, we aimed to present an unusually large intraductal papilloma case seen as a cystic structure, together with its diagnosis and treatment features, in the light of literature.

A 58-year-old female patient was admitted to our hospital with the complaint of retraction of palpable lumps on the left breast. In ultrasonography; A complex cystic mass lesion with a thick wall, smooth contours, a diameter of 56x48 mm in the cystic component and a diameter of 19.2x13.3 mm in the solid component was observed. It was removed with clean surgical margins by excisional biopsy. It reported as low grade papillary ductal intraepithelial neoplasia (Atypical Papilloma). Some researchers have reported that the rate of transformation of benign intraductal papilloma into malignancy with surgical excision may vary between 2% and 10%.

We think that in the management of intraductal polypoid lesions, the effectiveness of each of the radiological follow-up, tru-cut biopsy and surgical excision methods should be evaluated on a patient basis.

Keywords: Intraductal papilloma, papillary breast lesions, surgical excision

Most of the patients who come to the breast clinic present with the complaint of a palpable mass. Some of the pathological lesions that cause this picture are intraductal papillomas. Intraductal papillomas are usually seen in premenopausal women and originate from the major duct [1]. Intracystic papillary lesions of the breast are rare and constitute approximately 1-3% of all breast lesions [2].

Papillomas are formed by the development of ductal epithelial proliferation together with a fibrovascular stalk. Papilloma when papillary lesions are central and solitary; When they are located peripherally

and in more than one terminal ductal lobular unit, it is called papillomatosis [3]. Papillary lesions are classified as benign (papilloma) and malignant (papillary carcinoma). Most of the lesions are benign [4]. On ultrasonography (USG), papillary lesions can be seen as a solid mass in an enlarged duct or a cyst, or as a pure solid mass [5]. Most of the intraductal papillomas are smaller than 5 mm [6]. The risk of malignancy increases as the size of the cyst and the ratio of its solid component increase [7].

In this article, we aimed to present an unusually large intraductal papilloma case seen as a cystic structure, together with its



How to cite this article

Ulaş A, Large intraductal papilloma in the breast: A case report and review of the literature. J Bursa Med 2023;1(3):99-103

Address for correspondence

Aydin Ulaş, MD., Bursa Nev Esentepe Hospital, 16130, Nilüfer/Bursa, Turkey.
E-mail: draydinulas@yahoo.com

©Copyright 2023 by J Bursa Med

Available at <https://dergipark.org.tr/tr/pub/bursamed>

diagnosis and treatment features, in the light of literature.

CASE REPORT

A 58-year-old female patient was admitted to our hospital with a complaint of palpable left breast for about 2 months and nipple retraction in the last 15 days. The patient had no complaints of pain and nipple discharge. There were no features of breast cancer risk factors in the family history. On physical examination, a well-circumscribed, round mass was palpated near the areola at the junction of the left breast outer quadrant. Breast ultrasonography and mammography examinations were requested. In ultrasonography, A

complex cystic mass lesion with a thick-walled, smooth contour, cystic, solid component inside, showing increased internal vascularity, with a cystic component diameter 56 mm and a solid component diameter of 19 mm was observed (Figure 1).

In mammography, A dense nodular area of diameter 6.4 cm with sharp edges and smooth contours was observed compressing the glandular parenchyma (Figure 2). He was informed that the possible pathology result of the detected cystic mass might be benign rather than malignancy, but malignancy could not be

ruled out by radiological imaging alone, and histopathological examination was recommended to the patient. Information was given about the use of core biopsy and excisional biopsy methods accompanied by ultrasonography. At the patient's request, the cystic intraductal polypoid lesion was excised by excisional biopsy with clean surgical margins (Figure 3). In its pathology, Papillary and solid proliferation areas were observed in the dilated duct lumens in the breast parenchyma. In some papillary structures, especially in the areas of solid array pattern, atypia and increased mitosis were noted in the cells. It was reported as low grade papillary ductal intraepithelial neoplasia (Atypical Papilloma).

DISCUSSION

Nipple retraction, discharge and palpable breast stiffness are the main complaints that cause patients to worry and apply to the hospital. As a result of the frequent use of imaging methods such as mammography or ultrasonography in breast cancer screening, papillary lesions can be detected as an asymptomatic mass or calcified lesion [8]. US findings in papillary breast lesions depend on the macroscopic appearance of the lesion [9]. On US, papillary lesions can be seen

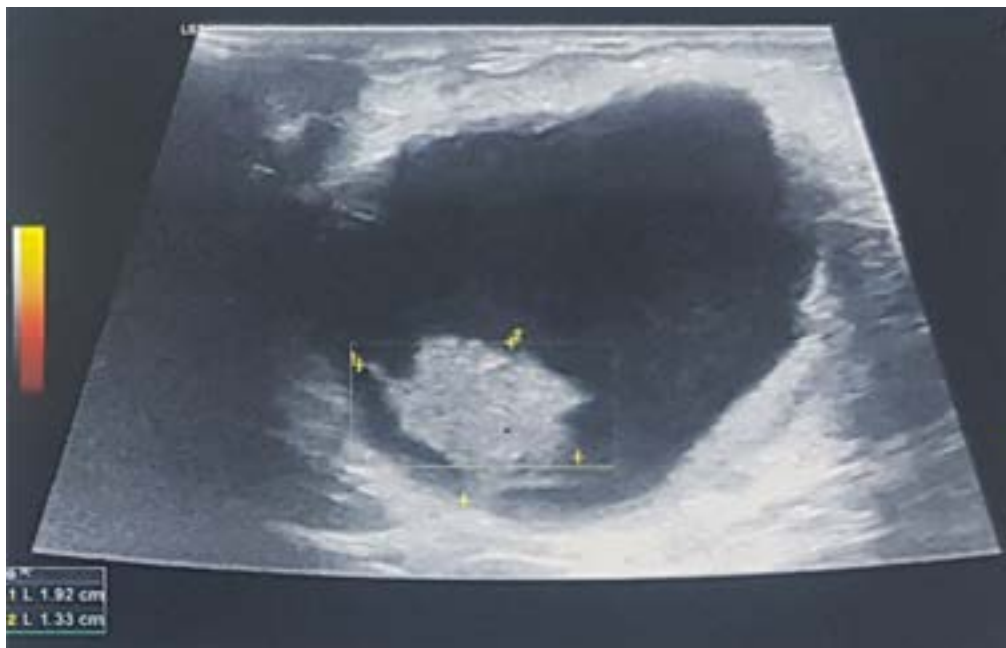

Figure 1. Ultrasound image of a complex cystic mass lesion

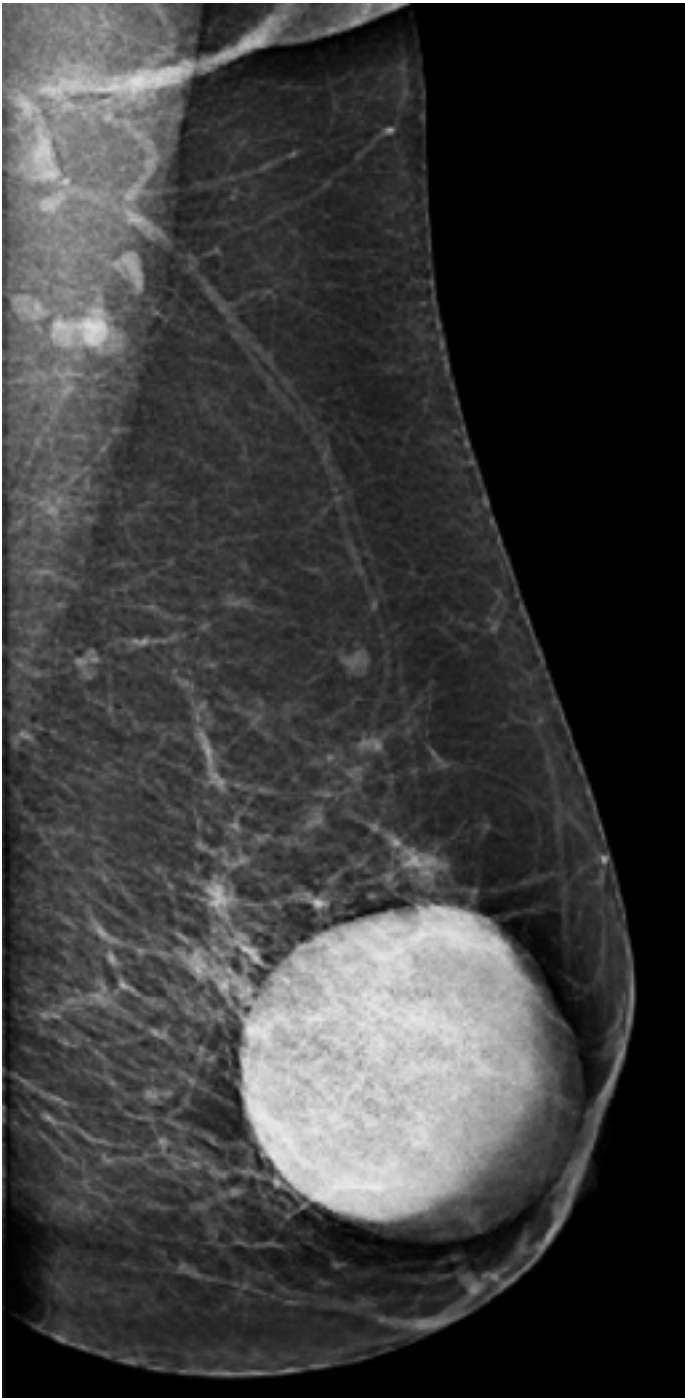


Figure 2. Mammography image of a dense nodular area of diameter 6.4 cm with sharp edges and smooth contours.

as a solid mass in an enlarged duct or a cyst, or as a pure solid mass [5, 9]. If the lesion is small, a focal enlarged canal without a mass may be the only US finding. In this case,

the presence of nipple discharge in the patient should suggest the diagnosis of papillary lesion, even if the mass is not observed [5]. Han *et al.* [10] classified papillary lesions in US into four groups as intraluminal, extraductal, completely solid and solid-cystic

mixed type. Masses localized in the breast, especially behind the nipple-areola complex, may present with skin and nipple retraction as a clinical symptom due to a fibrous process. Pathologically, there are signs of fat necrosis, ductal ectasia, Mondor's disease, and skin retraction in carcinoma [11]. Since ductal ectasia is associated with advanced fibrosis of the duct wall, the nipple may be flattened or completely collapsed in this disease [12].

Intraductal papillomas are usually seen in premenopausal women and originate from the major duct. It is usually less than 0.5 cm in size but can reach up to 5 cm [1]. In our case, there was an uncommon intraductal papillomatoid lesion with a size of approximately 2 cm within the 5 cm ductal cystic component. She complained of nipple recession due to being near the areola.

While papillary neoplasia constitutes 40-70% of pathological nipple discharges, bloody or pathological discharge is observed in only half of the patients diagnosed with papilloma. Papillary carcinomas are rare and account for 1% to 2% of all breast malignancies. It is frequently seen in the postmenopausal group, and complaints of palpable mass and nipple discharge are present [13]. In our case, there was postmenopausal age but no nipple discharge. The absence of this finding was a feature that strengthened the benign character of the lesion. Cysts containing papilloma are smaller in size than papillary carcinoma, and intracystic papillary lesions smaller than 3 cm are usually

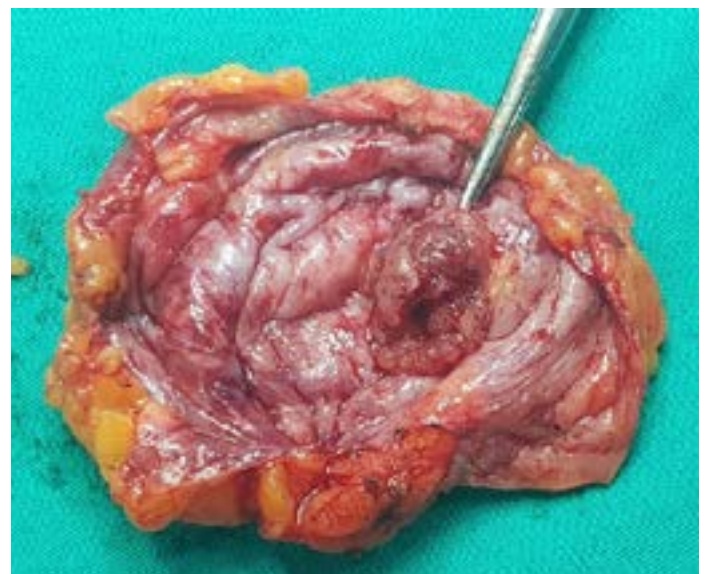

Figure 3. Excised cystic intraductal polypoid lesion.

benign [14]. In our case, there was a polypoid mass of approximately 2 cm in line with the literature, and this finding supported the idea that the lesion was benign.

Although it greatly reduces the rate of excisional biopsy, there is no standard treatment approach for which patients to undergo excision in the management of benign papillary

lesions after tru-cut biopsy or FNAB. Excisional biopsy is recommended because a significant portion of the cases diagnosed with Tru-cut biopsy or FNAB are upgraded to in-situ or invasive cancer after surgical excision [15]. However, some authors suggest removal of only lesions with atypia [16]. One reason for concern in this regard is the possibility that areas of atypia or a focus of carcinoma may be missed in the biopsy specimen. In recent studies, it has been shown that upgrading is detected in one-fifth of the patients, and therefore the treatment approach has changed in favor of surgery [16, 17].

Differentiation of benign and malignant papillary lesions is difficult in the absence of specific radiological and histological findings, and surgical excision is required [18]. Some investigators have reported that the rate of benign intraductal papilloma becoming malignant with surgical excision may vary between 2% and 10% [19]. For this reason, some suggest follow-up with clinical and imaging methods, while others recommend resection. Benign IDPs proven by radiology and core biopsy compatibility rarely turn into malignancy [20].

Various studies in the literature have shown a relationship between advanced age, postmenopausal status, complex cystic echo pattern on imaging, peripheral localization, microcalcifications, large lesion, pathology-radiology mismatch, high Breast Imaging Reporting and Data Systems (BI-RADS) score, and nipple discharge and malignancy. detected [21]. Since the USG finding was BIRADS 4C, the patient was informed, and excisional biopsy was performed without tru-cut biopsy. Pathology result was reported as Low grade papillary ductal intraepithelial neoplasia (Atypical Papilloma).

CONCLUSION

Intraductal papillomas constitute approximately 1-3% of all breast lesions and 1% to 2% of all breast malignancies. As the lesion size increases, the malignancy potential increases. Diagnosis can be made with less invasive methods such as tru cut biopsy,

but the possibility of pathological upgrade of 2-10% should be considered. For this reason, we think that the efficacy of radiological follow-up, tru-cut biopsy and surgical excision methods should be evaluated on a patient basis in the management of intraductal polypoid lesions.

Scientific Responsibility Statement

The authors declare that they are responsible for the article's scientific content including study design, data collection, analysis and interpretation, writing, some of the main line, or all of the preparation and scientific review of the contents and approval of the final version of the article.

Animal and human rights statement

All procedures performed in this study were in accordance with the ethical standards of the institutional and/or national research committee and with the 1964 Helsinki declaration and its later amendments or comparable ethical standards. No animal or human studies were carried out by the authors for this article.

Funding

None

Conflict of interest

None of the authors received any type of financial support that could be considered potential conflict of interest regarding the manuscript or its submission. Patient consent for publication: Obtained

REFERENCES

1. Brunnicardi CF, Andersen DK, Billiar TR, Dunn DL, Hunter JG, Matthews JB, Pollock RE. Schwartz's Principles of Surgery, McGraw-Hill Companies, New York, 10th edition, 2015; pp: 497-565.
2. L.E. Hughes, N.J. Bundred, Breast macrocysts, World J. Surg. 13 (1989) 711-714
3. Tavassoli FA, Devilee P. World Health Organization Classification of Tumours. Pathology and Genetics of the Breast and Female Genital Organs. Lyon, IARC Press, 2003; 9-113
4. A. Estabrook, T. Asch, F. Gump, S.J. Kister, P. Geller, Mammographic features of intracystic papillary lesions, Surg. Gynecol. Obstet. 170 (1990) 113-116
5. Kasumi F (ed). Ultrasound of breast diseases. 2nd edition. Tokyo: Shinohara-shuppan Co;1983. 19-25.
6. Daniel BL, Gardner RW, Birdwell RL, Nowels KW, Johnson D. Magnetic resonance imaging of intraductal papilloma of the breast. Magn Reson Imaging. 2003; 21: 887-92.
7. N.M. Foley, J.M. Racz, Z. Al-Hilli, V. Livingstone, T. Cil,

- C.M. Holloway, et al. An International multicenter review of the malignancy rate of excised papillomatous breast lesions, *Ann. Surg. Oncol.* 22 (Suppl. 3) (2015) S385–S390.
8. Jagmohan P, Pool FJ, Putti TC, Wong J. Papillary lesions of the breast: imaging findings and diagnostic challenges. *Diagn Interv Radiol* 2013;19(6):471-8.
9. Tohno E (ed). *Ultrasound diagnosis of breast diseases*. 3rd edition. Edinburgh: Churchill Livingstone;1994:94–7.
10. Han BK, Choe YH, Ko YH et al. Benign papillary lesions of the breast: sonographic- pathologic correlation. *J Ultrasound Med* 1999;18:217-23.
11. Brasanac D, Boricic I, Todorovic V. Epidermotropic metastases from breast carcinoma showing different clinical and histopathological features on the trunk and on the scalp in a single patient. *J Cutan Pathol* 2003;30:641-643.
12. Blanchard DK, Reynolds CA, Grant CS, Donohue JH. Primary nonphylloides breast sarcomas. *The American Journal of Surgery* 2003;186:359-61
13. Jagmohan P, Pool FJ, Putti TC, Wong J. Papillary lesions of the breast: imaging findings and diagnostic challenges. *Diagn Interv Radiol* 2013;19(6):471-8.
14. PB Jeffrey, BM Ljung , Memenin selim ve habis papiller lezyonları : sitomorfolojik bir çalışma, *Am. J. Clin. Pathol.* 101 (1994) 500–507.
15. McGhan LJ, Pockaj BA, Wasif N, Giurescu ME, McCullough AE, Gray RJ. Papillary lesions on core breast biopsy: excisional biopsy for all patients? *Am Surg* 2013;79(12):1238- 42
16. Ahmadiyah N, Stoleru MA, Raza S, Lester SC, Golshan M. Management of intraductal papillomas of the breast: an analysis of 129 cases and their outcome. *Ann Surg Oncol* 2009;16:2264-9.
17. Celik MF, Yilmaz R, Dural AC, Celik-Yabul F, Baytekin HF, Kapan S, Alis H. The assessment of cases with intraductal papillomas after surgery; the correlation of radiological and pathological findings. *J Ist Faculty Med* 2019;82(2):69-74. doi: 10.26650/2018.0029
18. Shouhed D, Amersi FF, Spurrier R, Dang C, Astvatsaturyan K, Bose S, et al. Intraductal papillary lesions of the breast: clinical and pathological correlation. *Am Surg* 2012;78(10):1161-5
19. Brennan SB, Adriana C, Laura L, et al. Papilloma diagnosed at MRI guided vacuum-assisted breast biopsy: is surgical excision still warranted? *AJR.* 2012;199(4):W512-W519.
20. Fresia P, Corben AD, Brennan SB, et al. Breast intraductal papillomas without atypia in radiologic pathologic concordant core-needle biopsies: rate of upgrade to carcinoma at excision. *Cancer.* 2016;122: 2819-2827
21. Nayak A, Carkaci S, Gilcrease MZ, Liu P, Middleton LP, Bassett RL Jr, et al. Benign papillomas without atypia diagnosed on core needle biopsy: experience from a single institution and proposed criteria for excision. *Clin Breast Cancer* 2013;13(6):439-49.

