

■ Case Report

Idiopathic bone cavity at anterior mandible possibly associated with previous orthodontic treatment

Mandibula anterior bölgede ortodontik tedavi ile oluşmuş idiopatik kemik kavitesi

Mehmet Zahit ADIŞEN¹, Alime OKKESİM^{1a}, Melda MISIRLIOĞLU¹, Fethi ATIL²

¹Department of Oral and Maxillofacial Radiology, Faculty of Dentistry, Kırıkkale University, Kırıkkale,

²Department of Oral and Maxillofacial Surgery, Faculty of Dentistry, Kırıkkale University, Kırıkkale, TURKEY

ÖZ

İdiopatik kemik kavitesine (İKK), sıklıkla uzun kemiklerde ve aynı zamanda kraniyofasiyal iskelette tesadüfi olarak rastlanılmaktadır. Lezyonlar genellikle asemptomatiktir ve rutin diş muayenesi sırasında çekilen panoramik radyografide tesadüfi olarak fark edilir. Radyografik olarak İKK uniloküler veya multiloküler radyolüsent iyi sınırlı ve diş köklerine arasına scallop tarz eğilim göstermektedir. Fakat bu görüntü patognomonik değildir. İKK'nin kesin etiyolojisi bilinmemektedir. İKK oluşumu için en sık önerilen teori travmanın yol açtığı intraosseöz kanama oluşması, kan pıhtısının erimesi ve sonrasında kemik kavitesi oluşumudur. Ortodontik diş hareketinin İKK'nin etiyolojisinde rol oynadığı literatürde tartışılmaktadır. Ayrıca, hormonal etkinin kemik hücre aktivitesi üzerine etkisi İKK'nin etiyolojisinde kabul edilebilir olarak görülmektedir. Bu vaka raporunda, 15 yaşında ortodontik tedavi gören kadın hastada rutin panoramik radyografik incelemede lezyon tesadüfen tespit edilmesi ve İKK'nin klinik, radyografik özellikleri ve cerrahi tedavisi sunulmaktadır.

Anahtar Kelimeler: İdiopatik kemik kavitesi, non-neoplastic intraosseus pseudokist, panoramik radyografi, konik ışınli bilgisayarlı tomografi

ABSTRACT

Idiopathic bone cavities (IBCs) are usually an incidental finding, often found in long bones but also in the craniofacial skeleton. Generally, the lesions are asymptomatic and incidentally detected by panoramic radiography in routine dental examinations. Radiographically, IBC is a radiolucent unilocular or multilocular lucency with well-defined margins that tend to scallop between roots of teeth. But this is not pathognomonic for this entity. IBC has an unclear etiology. The most frequently proposed theory for the development of IBC involves a traumatic event that leads to intraosseous hemorrhage, blood clot liquefaction, and further formation of a cavity. The role of orthodontic tooth movement in the etiology of IBC is discussed in the literature. Additionally, hormonal influence over bone cell activity seems to be an appealing concept in the etiopathogenesis of IBC. This paper describes clinical and radiographic aspects and surgical treatment of an IBC detected incidentally on a 15-year-old orthodontic female patient.

Keywords: Idiopathic bone cavity, non-neoplastic intraosseous pseudocyst, panoramic radiography, cone-beam computed tomography

Corresponding Author³: Alime OKKESİM, Kırıkkale Üniversitesi, Diş Hekimliği Fakültesi, Ağız Diş ve Çene Radyolojisi AD, Yenişehir, Yahşihan, Kırıkkale/ TURKEY

Phone: +90 318 2244927-2243618

E-mail: dt.alimeeraslan@hotmail.com

Received 31.10.2017 accepted 02.12.2016

Doi: 10.18663/tjcl.320054

Introduction

Idiopathic bone cavity (IBC), also known as a simple or traumatic bone cyst, is a benign lesion characterized by an empty or semi-empty cavity within the bone. The World Health Organization currently defines the IBC as a non-neoplastic intraosseous pseudocyst devoid of epithelial lining [1]. In 1929, Lucas first described these lesions and since then it has been frequently reported in medical and dental scientific literature [2]. IBC is usually found in long bones. In the jaw, IBC is uncommon, comprising 1% of all cysts affecting this region. It is often found in the mandible, and most common between children and teenagers in the second decade of life [3]. Some studies have suggested that these cavities are more common among male patients [4]. Generally, the lesions are asymptomatic and are incidentally detected by panoramic radiography. The most common presentation of IBC is a radiolucent unilocular or multilocular lucency with well-defined margins that tend to scallop between roots of teeth but this is not pathognomonic. Teeth related with the lesion are vital, and generally don't show root resorption or displacement. Lamina dura is usually present, although care must be exercised to avoid misdiagnosis of pulpal-associated pathologic conditions [5].

IBC's etiology is unclear where the most frequently proposed theory for the development involves a traumatic event that leads to intraosseous hemorrhage, blood clot liquefaction, and further formation of a cavity [3]. Velez et al. suggested that the orthodontic tooth movement may be involved in the etiology of IBC [6].

This paper describes clinical and radiographic aspects and surgical treatment of a 15-year-old orthodontic female patient who presented an incidentally detected IBC.

Case Report

A 15-year-old female patient applied to our department for routine dental examination. In panoramic radiographic examination, a large unilocular radiolucent lesion at anterior mandible was detected incidentally (Figure 1).

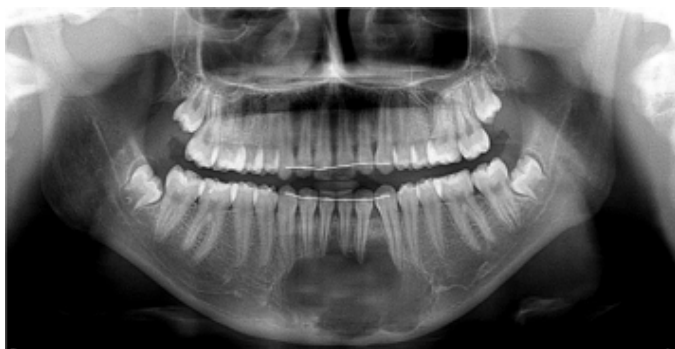

Figure 1. Panoramic radiograph showing a large unilocular radiolucent lesion at anterior mandible.

In her medical history, no relevant systemic conditions were present, but dental anamnesis revealed that she had finished an orthodontic treatment 6 months ago. When we examined her 4 years' previous panoramic radiography before the treatment, there were no signs of lesion at anterior mandible (Figure 2).

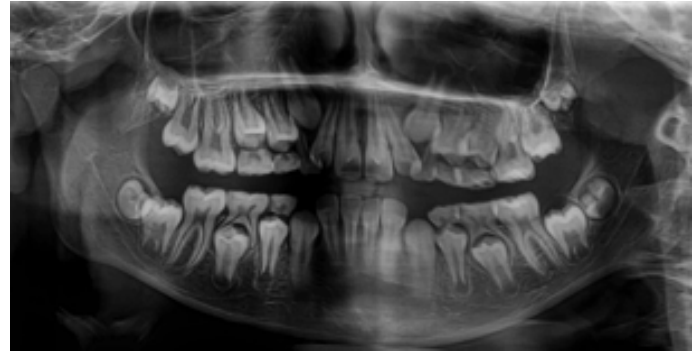


Figure 2. Panoramic radiograph showing before orthodontic treatment, there were no signs of lesion at anterior mandible.

In clinical examination, all teeth related to lesion area were vital and there was no replacement of any teeth. Additionally, there was no expansion in mandible. For advanced imaging of the area; PaxUni 3D (Vatech, Seoul, Korea) was used to capture Cone-beam computed tomography (CBCT) images at the following settings: 50-90 kVp, 4-10 mA, and seconds exposure time, and a 50×50 mm field of view (FOV) size. CBCT scan showed unilocular radiolucency at mandibular anterior region. There was no cortical perforation in mandibular bone and no external resorption in anterior teeth (Figure 3).

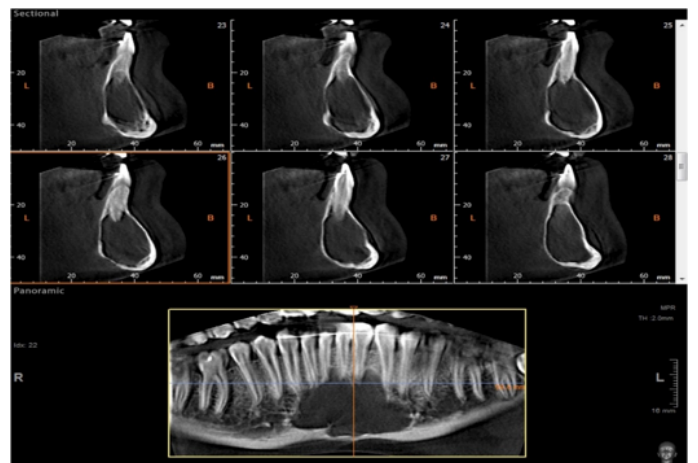


Figure 3. CBCT scan showed unilocular radiolucency at mandibular anterior region.

Due to the radiographic appearance and clinical findings of the lesion; a preliminary diagnosis of an odontogenic cyst was thought. The patient was consulted to Maxillofacial Surgery Department for possible treatment options. Before surgical operation, patient signed an informed consent form. In sur-

gical exploration, an empty cavity without any fluid or blood was detected. There was no epithelial lining on cavity walls. Curettage of the bony walls was performed to serve as both the diagnostic purpose and as the definitive therapy by producing bleeding in the cavity. On histopathology examination non-specific inflammatory cells on fibrin lining was observed, suggesting no other pathological condition. Bone healing occurred within 5 months after the surgical procedure (Figures 4 and 5).

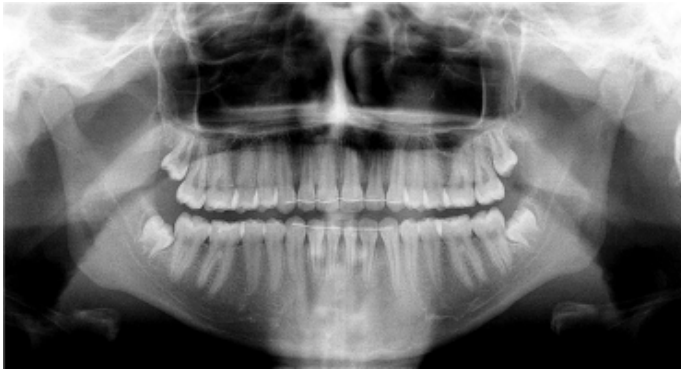

Figure 4 Showing bone healing occurred within 5 months on panoramic radiography.

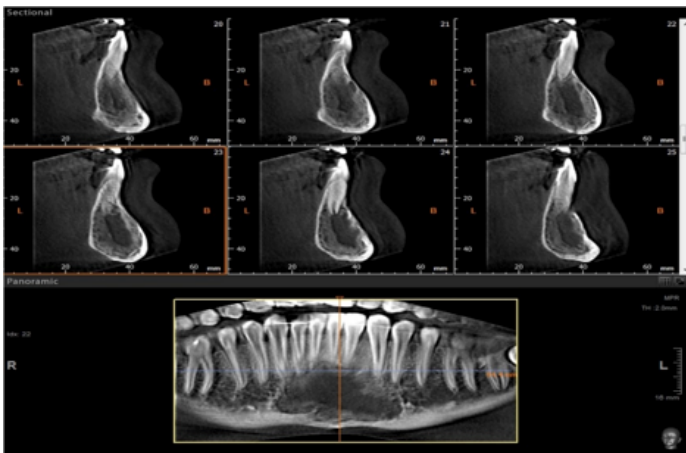


Figure 5. Showing bone healing occurred within 5 months on CBCT scan. The patient recovered uneventfully. The patient still follow-up in long-term period due to the possibility of recurrence.

Discussion

The differential diagnosis of IBC contains odontogenic keratocyst, ameloblastoma, central giant cell lesions, lateral periodontal cyst, and other odontogenic cysts and tumors [4]. Radiographically, IBCs are well-defined radiolucent lesions, with variable shape and size. Some radiographic findings, such as interdental scalloping or the perioperative view of a bone cavity, assist in its identifications [4]. Although the majority of IBCs are asymptomatic, some clinical findings, such as pain, tooth sensitivity, or bone expansion, might hamper the distinction between IBC and odontogenic tumors and cysts [3]. Damante

et al. [7] and Harnet et al. [8] recommend a noninvasive management strategy for recognizing and following IBC lesions with longitudinal radiographic follow-up and without surgical intervention. Although this is reasonable given the benign nature of this lesion, other jaw lesions that might appear similar radiographically cannot be definitively ruled out without an exploratory procedure [9].

The clinical presentation at the time of the surgical exploration is almost pathognomonic for IBCs. The surgical exploration serves as both diagnostic tool and as the definitive therapy by producing bleeding in the cavity [10]. In theory, the presence of blood within the lesion cavity after an operation, from curettage or injection of autologous blood, triggers mesenchymal cell differentiation and bone production [9]. Bone healing usually occurs within 6-12 months after the surgical procedure. Other therapeutic alternatives have been suggested and include the use of allogeneic materials for the filling of the cavity in larger lesions [10].

The pathogenesis of IBC is unclear. Harnet et al. critically reviewed the main etiological theory, and three are the most frequently accepted: (a) bone growth abnormality; (b) bone tumor degeneration; and (c) hemorrhagic trauma caused by a specific factor [5]. Additionally, hormonal influence over bone cell activity seems to be an appealing concept in the etiopathogenesis of IBC. It is easy to understand the hormonal role in females, both during adolescence and in older women. Estrogens are crucial to healthy bone metabolism in males and females, and androgens also help regulate osseous cellular turnover [7]. Velez et al. also suggested that the orthodontic tooth movement may be involved in the etiology of IBC with two mechanisms. 1) An increased vascular activity, in the presence of vascular endothelial growth factor (VEGF), is seen in areas of tension and pressure during experimental tooth movement. 2) The piezoelectric effect may play an important role in the development of IBC [10]. In the present case, there was a possible association with the previous orthodontic treatment with IBC, since there were no signs of lesion in previous panoramic radiography. Hormonal factors may also involve in the pathogenesis of IBC in the present case of young female patient.

In conclusion, IBC is an uncommon lesion of jaws but it should be considered in differential diagnosis of asymptomatic radiolucent lesions in oral cavity especially in mandible. Orthodontic treatment in young subjects seems to have an influence in the etiology of IBC. Although some authors suggested non-invasive management strategy for recognizing and following IBC lesions, we suggest surgical exploration of nonspecific large radiolucent lesions for definitive diagnosis of IBC.

Declaration of conflicting interests

The author declared no conflicts of interest with respect to the authorship and/or publication of this article.

Funding

The author received no financial support for the research and/or authorship of this article.

References

1. Coindre J-M. New WHO classification of tumours of soft tissue and bone. *Ann Pathol* 2012; 32: 115.
2. Lucas C, Blum T. Do all cysts in the jaws originate from the dental system. *J Am Dent Assoc* 1929; 16: 647-61.
3. Discacciati ED, de Faria VMC, Garcia NG, Sakai VT, Pereira AAC, Hanemann JAC. Idiopathic bone cavity: Case series involving children and adolescents. *J Investig Clin Dent* 2012; 3: 103-8.
4. Perdigão P, Silva E, Sakurai E, de Araújo NS, Gomez R. Idiopathic bone cavity: A clinical, radiographic, and histological study. *Br J Oral Maxillofac Surg* 2003; 41: 407-9.
5. Peacock ME, Krishna R, Gustin JW, Stevens MR, Arce RM, Abdelsayed RA. Retrospective study on idiopathic bone cavity and its association with cementoosseous dysplasia. *Oral Surg Oral Med Oral Pathol Oral Radiol* 2015; 119: 246-51.
6. Velez I, Siegel M, Mintz S, Rolle R. The relationship between idiopathic bone cavity and orthodontic tooth movement: Analysis of 44 cases. *Dentomaxillofac Radiol* 2010; 39: 162-6.
7. Damante J, Da S Guerra E, Ferreira Jr O. Spontaneous resolution of simple bone cysts. *Dentomaxillofac Radiol* 2002; 31: 182-6.
8. Harnet J-C, Lombardi T, Klewansky P, Rieger J, Tempe M-H, Clavert J-M. Solitary bone cyst of the jaws: A review of the etiopathogenic hypotheses. *J Oral Maxillofac Surg* 2008; 66: 2345-8.
9. Resnick CM, Dentino KM, Garza R, Padwa BL. A management strategy for idiopathic bone cavities of the jaws. *J Oral Maxillofac Surg* 2016; 74: 1153-8.
10. Cortell Ballester I, Barbosa de Figueiredo RP, Berini Aytés L, Gay Escoda C. Traumatic bone cyst: A retrospective study of 21 cases. *Med Oral Patol Oral Cir Bucal* 2009; 14: 239-43.