



# Investigation of the Effect of Ankaferd Blood Stopper on Wound Healing in the Donor Site

## Ankaferd Kanama Durdurucunun Donör Bölgede Yara İyileşmesi Üzerine Etkisinin İncelenmesi

Ahmet Cemil TALMAÇ<sup>1</sup>   
a.c.talmac@hotmail.com

Dicle ALTINDAL<sup>1\*</sup>   
dtdicle@hotmail.com

Metin ÇALIŞIR<sup>2</sup>   
calisir\_metin@hotmail.com

Bilal EGE<sup>3</sup>   
miregein@gmail.com

### ABSTRACT

**Aim:** The aim of this study is to evaluate the effect of Ankaferd Blood Stopper (ABS) on the palatal donor site following free gingival graft (FGG) surgery.

**Materials and Methods:** A total of 12 patients (24 palatal sites) were included in the study. In each patient, the donor sites were randomly divided into two groups. ABS+collagen pads were applied to the test group. Only collagen pads were applied to the control group. Donor sites were evaluated in terms of bleeding, complete epithelialization, sensitivity, pain score, analgesic usage, wound size, Landry, Turnbull, and Howley (LTH) index, and tissue thickness (TT).

**Results:** Intraoperative bleeding was observed in significantly more patients (n=9) in the control group, while it was not observed in any of the patients in the test group (p=0.000). Although higher complete epithelialization (33.3%) was detected in the test group on day 14, there was no significant difference in epithelialization between the groups. There was no significant difference in pain score, analgesic usage, wound size, LTH index, or TT between the groups. When the amount of change between the times was analyzed, only the change in TT between the 21st day and the 6th week was found to be statistically significant (p=0.028).

**Conclusion:** In our study, it can be said that the use of ABS following FGG surgery has a positive effect on intraoperative bleeding, short-term complete epithelialization, and long-term TT, but it cannot provide superiority compared to collagen sponge alone in terms of early wound healing, postoperative pain, and analgesic usage.

**Keywords:** Ankaferd hemostatic, Free gingival graft, Wound healing

Received: 06.05.2023

Accepted: 11.07.2023

Published: 28.08.2023

### ÖZ

**Amaç:** Bu çalışmanın amacı, serbest dişeti grefti (SDG) cerrahisi sonrası palatinal donör alanda Ankaferd Kanama Durdurucu (AKD) kullanımının etkisini değerlendirmektir.

**Gereç ve Yöntemler:** Toplam 12 hasta (24 palatal bölge) çalışmaya dahil edildi. Her hastada donör bölgeler rasgele iki gruba ayrıldı. Test grubuna AKD+kollajen ped uygulandı. Kontrol grubuna ise sadece kollajen ped uygulandı. Kanama, tam epitelizeasyon, duyarlılık, ağrı skoru, alınan analjezik sayısı, yara boyutu, Landry, Turnbull ve Howley (LTH) indeksi ve doku kalınlığı (DK) açısından donör sahalar değerlendirildi.

**Bulgular:** İntraoperatif kanama bakımından kontrol grubunda anlamlı şekilde daha fazla hastada (n=9) kanama gözlenirken; test grubunda hiçbir hastada kanama gözlenmedi (p=0.000). Test grubunda 14. günde daha yüksek tam epitelizeasyon varlığı (33.3%) tespit edilmesine rağmen, epitelizeasyon bakımından gruplar arasında anlamlı bir farklılık tespit edilmedi. Gruplar arasında ağrı skorları, analjezik kullanımı, yara boyutu, LTH indeksi ve DK bakımından anlamlı bir farklılık tespit edilmedi. Zamanlar arasındaki değişim miktarı incelendiğinde sadece 21. gün ile 6. hafta arasındaki DK'daki değişim, istatistiksel olarak anlamlı bulundu (p=0,028).

**Sonuç:** Çalışmamızda SDG cerrahisi sonrasında AKD kullanımının intraoperatif kanama, kısa dönem tam epitelizeasyon ve uzun dönem DK'da olumlu etkisinin olduğu ancak erken dönem yara iyileşmesi, postoperatif ağrı ve analjezik tüketimi konusunda tek başına kollajen süngere üstünlük sağlayamadığı söylenebilir.

**Anahtar Kelimeler:** Ankaferd kanama durdurucu, Serbest dişeti grefti, Yara iyileşmesi

Geliş: 06.05.2023

Kabul: 11.07.2023

Yayın: 28.08.2023

**Atıf/ Citation:** Talmaç A.C., Altındal D., Çalışır M., Ege B. Investigation of the Effect of Ankaferd Blood Stopper on Wound Healing in the Donor Site NEU Dent J. 2023;5:75-82.

\* Sorumlu Yazar/Corresponding Author

1. Van Yuzuncu Yil University, Faculty of Dentistry, Department of Periodontology, Van, Turkey
2. Adiyaman University, Faculty of Dentistry, Department of Periodontology, Adiyaman, Turkey
3. Adiyaman University, Faculty of Dentistry, Department of Oral and Maxillofacial Surgery, Adiyaman, Turkey



"This article is licensed under a [Creative Commons Attribution-NonCommercial 4.0 International License](https://creativecommons.org/licenses/by-nc/4.0/) (CC BY-NC 4.0)

## INTRODUCTION

Maintenance of long-term periodontal health around teeth and dental implants is associated with increased keratinized tissue (KT). Specifically, KT width has been shown to have an effect on plaque accumulation, tissue inflammation, and brushing discomfort around the implant.<sup>1</sup> Autogenous palatal grafts are known for their excellent clinical performance in improving tissue biotype and increasing KT width.<sup>2</sup> Among these palatal grafts, soft tissue grafts that are completely detached from the rest of the palate with epithelial tissue at the top are defined as free gingival grafts (FGG). However, it has been associated with a high incidence of donor-site pain in the early postoperative period.<sup>3</sup> It has been determined that complications such as paresthesia, herpetic lesion, and excessive bleeding can be seen following this procedure, in addition to the increased discomfort and morbidity experienced by patients in the palatal region.<sup>4</sup> Hemostatics have been used to accelerate the healing process and reduce the prolonged bleeding and pain associated with the palate wound.<sup>5,6</sup>

Ankaferd Blood Stopper (ABS) is a plant extract used as a hemostatic agent in Turkey. ABS consists of a standardized blend of five herbs (*Glycyrrhiza glabra*, *Vitis vinifera*, *Alpinia officinarum*, *Urtica dioica*, and *Thymus vulgaris*). ABS triggers a physiological hemostatic process without disrupting any coagulation factors.<sup>7</sup> It is reported to stop bleeding by forming a protein network that provides vital erythrocyte aggregation.<sup>7</sup> In other words, it exerts its effect not through coagulation factors but physiologically through erythrocyte aggregation. ABS has been shown to affect the vascular endothelium, blood cells, angiogenesis, cellular proliferation, vascular dynamics, and cell mediators, along with exerting antibacterial effects.<sup>7,8</sup> It has also been used on salivary glands, following tooth extraction, in the treatment of intraosseous defects, and in the palatal region.<sup>5,9-12</sup> However, there are limited available studies on the use of ABS, especially in the human palatal region.<sup>5</sup>

Today, there is an ongoing search for new treatment methods to minimize symptoms and increase patient comfort following FGG. Our study aimed to investigate the efficacy of ABS on bleeding, wound healing, and postoperative pain at the palatal donor site due to its therapeutic effects and being a natural agent.

## MATERIALS AND METHODS

### Study Design

Ethical approval for the study was obtained from the Clinical Research Ethics Committee of Van Yüzüncü Yıl University (25.12.2020/02). The study was conducted in the Department of Periodontology, Faculty of Dentistry, Van Yüzüncü Yıl University.

Our study was conducted with a total of 12 patients (total of 24 palatal sites) who had inadequate bilateral keratinized gingiva and were indicated for FGG surgery. Patients who were periodontally and systemically healthy, aged 18-55 years, had no allergies, did not have any blood diseases, did not use any drugs, and had not undergone any periodontal surgery during the last 6 months were included in the study. Patients who had poor oral hygiene, smoked, were pregnant or lactating, had a history of anticoagulant treatment, or had any systemic disease (e.g. diabetes, haemophilia, von Willebrand disease, connective tissue diseases, or immunodeficiency) were not included in the study. Informed consent was obtained from all participating patients.

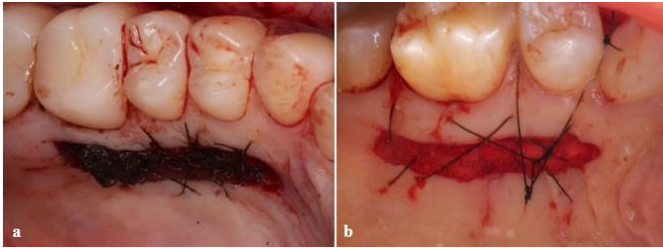
Randomization was performed with the coin test for each patient. Accordingly, one side of the palatal site was sutured with ABS (Ankaferd Blood Stopper® TM, Laurus Ilac Sanayi ve Ticaret a.s., Corlu, Tekirdag/Turkey) and collagen pads (Jason Collagen®, Botiss, Dieburg, Germany) in the test group (TG). On the symmetrical side, only collagen pads were used in the control group (CG). All surgical operations were performed by a single clinician (ACT). Clinical data collection and patient follow-up were performed by another researcher (DA). Statistical evaluations were performed by a third researcher (MC) who was blinded to the study groups.

### Surgical operation

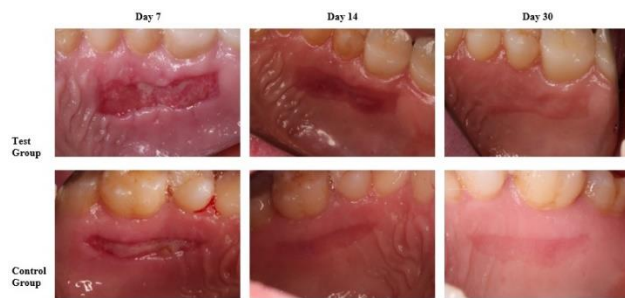FGG was applied by the same researcher (ACT) according to the latest and most frequently used technique today, primarily developed by Sullivan and Atkins.<sup>13</sup> For FGG, the area between the distal end line of the maxillary canine and the first molar tooth was used in both groups. Care was taken to remove the most coronal part of the graft so that the maxillary teeth were at least 2 mm apical from the gingival margins.<sup>5</sup> FGG dimensions were limited according to the dimensions of the recipient area (thickness, length, and width) with a thickness of 1.5-2 mm.<sup>14</sup> ABS-

dripped collagen pads were applied to the wound area in the TG, and only collagen pads were applied to the wound area in the CG (Figure 1). The wound sites were then sutured with 5/0 Supramid Polyamide (Serag Weissner GmbH & Co. KG Zum Kugelfang 8-12 95119 Naila, Germany). Photographs of the healing of the two groups are shown in Figure 2. The second operation was performed at least one month after the first operation data were collected. Patients took analgesics only if needed.

**Figure 1:** a) The test group; b) The control group



**Figure 2:** The healing of the two groups



## Clinical Evaluations

### Bleeding

The donor area was sutured, and an external pressure was applied for 2 minutes, and it was checked whether there was bleeding immediately afterwards. The absence of bleeding confirmed that adequate haemostasis was acquired, and no intraoperative bleeding occurred. The occurrence of bleeding reported by patients on postoperative day 7 was recorded as secondary bleeding (delayed bleeding) in the postoperative period.

### Complete Epithelialization Test with H<sub>2</sub>O<sub>2</sub>

Healing was assessed with H<sub>2</sub>O<sub>2</sub> on postoperative days 7, 14, 21, and 30. The site was dried, and 3% H<sub>2</sub>O<sub>2</sub> was dripped on the wound, and waited for a certain time (10 seconds) for the bubbles to appear.<sup>15</sup> Oxygen is not released since H<sub>2</sub>O<sub>2</sub> cannot spread to the connective tissue when the epithelial barrier is intact and is not affected by catalase. The absence of bubble formation indicated completed epithelialization.

Complete epithelialization was noted as “yes”. It was understood from the presence of bubbles that the surgical site was not completely epithelialized. No complete epithelialization was recorded as “no”. Thus, only a visual inspection was done.

### Sensitivity Test (SensT)

SensT was applied to patients on day 30.<sup>16</sup> Two donor sites were compared by performing two different steps, including submersion of the sharp end of the periodontal probe and frictional movement. Participants were asked to rate their sensory loss as severe, moderate, or none at all using a 3-point verbal descriptive scale.

### Pain

Patients were asked to evaluate their postoperative pain levels on postoperative days 1, 3, 7, and 14 using the Visual Analog Scale (VAS).<sup>17</sup> VAS includes a continuous 10-cm line, with 1 showing minimal pain and 10 showing severe pain. A score of 0 was given if the patient reported no pain.

### Analgesic Usage

Patients took analgesics if needed. Patients were asked to record their total analgesic intake within the first 7 days after surgery.

### Wound Size (WS)

On postoperative days 7, 14, 21, and 30, wound length and width were calculated using a millimetric periodontal probe.

### Wound Healing (Landry, Turnbull, and Howley (LTH) index)

Within the scope of the Landry, Turnbull, and Howley (LTH) index, an evaluation was made for the wound area after the operation.<sup>18</sup> In the scale, 1 point corresponded to very poor healing, whereas 5 points corresponded to excellent healing.<sup>19</sup> Records were collected from the patients on days 3, 7, 14, 21, and 30.<sup>15</sup>

### Tissue Thickness (TT)

The TT of the palatal area was measured preoperatively. The apical 2 mm of the gingival margin of the premolars was considered to be the border, and the mean TT was determined by measurements from the apical point of this border. This procedure was performed with a silicone stopper and a #20 endodontic spreader.<sup>15</sup> The needle was carefully placed

perpendicular to the mucous surface until it came into contact with the palatal bone.<sup>6</sup> The depth of penetration was then measured and recorded with a digital caliper (Mitutoyo Digimatic Caliper, Japan). The same measurements were performed and recorded on day 21 and at week 6.

### Postoperative care

Antibiotics (500 mg amoxicillin, Largopen, Bilim Ilac San. ve Tic. A.S. Tekirdag/Turkey), analgesics (500 mg paracetamol, Parol, Atabey Ilac Fabrikasi A.S. Istanbul/Turkey) and antiseptic spray (chlorhexidine digluconate, Kloroben, Drogosan Ilaclari San. ve Tic. A.S. Ankara/Turkey) were prescribed for all patients to use for one week. The palatal sutures were removed on day 7.

### Statistical Analysis

According to the previous study,<sup>20</sup> it was observed that the standard deviation for VAS values ranged from 0.31 to 1.37. Thus, in this study, the standard deviation was taken as 0.84 for the VAS value. In addition, for the 0.05 type I error rate, the Z value and effect size were assumed to be 1.96 and 0.48, respectively. Based on this information and according to the equation of sample size calculation ( $n = Z^2 \sigma^2 / d^2$ ), the minimum sample size was found to be 12.

Descriptive statistics were expressed as median, mean, standard deviation, minimum, and maximum values for the parameters. The Friedman's test was used to compare these parameters over time. In addition, the Wilcoxon test was used to compare the dependent groups. The Spearman correlation coefficient was calculated to determine the relationship between continuous variables from the features emphasized, while the Chi-Square test was used to determine the relationship between categorical variables. The Mann-Whitney U test was used to compare the groups in terms of the difference between times. The statistical significance level was accepted as 5% for the calculations, and the SPSS (Version 23 Statistical Package for the Social Sciences) statistical package program was used for analyses.

### RESULTS

The mean age of the 12 patients (8 females and 4 males) included in the study was  $41.33 \pm 9.345$ . Descriptive characteristics about age and gender are given in Table 1. Bleeding, epithelialization, and SensT evaluations are given in Table 2. There was a statistically significant difference in intraoperative

bleeding between the groups ( $p=0.000$ ). Accordingly, while intraoperative bleeding was not observed in the TG, 75% of intraoperative bleeding was noted in the CG. Secondary bleeding was not observed in any of the patients in either group.

**Table 1** Descriptive characteristics about age and gender

	n (%)	Mean $\pm$ St. Dev	Minimum	Maximum
Female	8 (66,7 %)	$38 \pm 8,864$	28	52
Male	4 (33,3 %)	$48 \pm 6,928$	42	54
Total	12 (100 %)	$41,33 \pm 9,345$	28	54

n: Number of patients, St. Dev: Standard deviation

**Table 2** Bleeding, epithelialization and sensitive test evaluation

	Yes	No
<b>Intraoperative bleeding</b>		
Control Group n (%)	9 (75%)	3 (25%)
Test Group n (%)	0 (0%)	12 (100%)
p	0,001	
<b>Secondary bleeding</b>		
Control Group n (%)	0 (0%)	12 (100%)
Test Group n (%)	0 (0%)	12 (100%)
p	0,999	
<b>Complete Epithelialization on day 7</b>		
Control Group n (%)	0 (0%)	12 (100%)
Test Group n (%)	0 (0%)	12 (100%)
p	0,999	
<b>Complete Epithelialization on day 14</b>		
Control Group n (%)	1 (8,3%)	11 (91,7%)
Test Group n (%)	4 (33,3%)	8 (66,7%)
p	0,132	
<b>Complete Epithelialization on day 21</b>		
Control Group n (%)	10 (83,3%)	2 (16,7%)
Test Group n (%)	12 (100%)	0 (0%)
p	0,140	
<b>Complete Epithelialization on day 30</b>		
Control Group n (%)	12 (100%)	0 (0%)
Test Group n (%)	12 (100%)	0 (0%)
p	0,999	
	<b>None</b>	<b>Moderate</b>
<b>Sensitivity Test</b>		
Control Group n (%)	6 (50%)	6 (50%)
Test Group n (%)	6 (50%)	6 (50%)
p	0,999	

Pearson Chi-Square

$p < 0.05$  statistically significant

Epithelialization was incomplete on day 7 in both groups. Although higher epithelialization (33.3%) was detected in the TG compared to the CG on day 14 (8.3%), there was no significant difference between the groups ( $p=0.132$ ). Epithelialization was



completed in all wound sites in the TG, especially on day 21, while it was completed on day 30 in the CG. Equal sensitivity was detected in both groups as per the SensT. No patients reported severe sensitivity or tenderness.

The values and comparison results of the groups in terms of mean pain score, analgesic usage, WS, LTH index, and TT are given in Table 3. When the mean VAS scores were evaluated in terms of postoperative pain, there was no significant difference between the groups. In the CG, a significant difference was found

intragroup in terms of VAS scores ( $p < 0.001$ ). Accordingly, the day-1 mean VAS score ( $4.50 \pm 2.43$ ) differed significantly from all other days. Also, no significant difference between the VAS pain scores of the 7th day and the VAS pain scores of both the 3rd and 14th days. In the TG, a significant difference was found in intragroup VAS pain scores. In the TG, the day-1 pain score was found to be statistically significant only with the day-14 pain score ( $p < 0.001$ ). There was no significant difference between the pain scores on days 3 and 7 in the TG.

**Table 3** The values and comparison results of the groups in terms of pain, analgesic usage, wound size, LTH index, and tissue thickness

	Control Group					Test Group					p
	Median	Mean	St. Dev.	Min.	Max.	Median	Mean	St. Dev.	Min.	Max.	
<b>Pain (score)</b>											
1st day	3,50	4,50 a	2,43	2,00	9,00	3,50	4,00 a	2,66	,00	9,00	0,321
3rd day	2,50	2,50 b	1,88	,00	6,00	3,50	3,50 ab	2,15	1,00	7,00	0,231
7th day	1,00	1,75 bc	1,82	,00	5,00	1,50	2,42 ab	2,87	,00	10,00	0,344
14th day	,00	0,33 c	0,49	,00	1,00	,00	1,00 b	2,59	,00	9,00	0,414
p	<b>0,001*</b>					<b>0,001*</b>					
<b>Analgesic usage (number)</b>											
1st day	1,00	1,08 a	0,67	,00	3,00	1,00	1,08 a	0,67	,00	2,00	0,999
2nd day	1,00	0,92 ab	1,00	,00	3,00	1,50	1,17 a	1,11	,00	3,00	0,317
3rd day	,00	0,42 b	0,67	,00	2,00	,50	0,92 ab	1,24	,00	4,00	0,109
4th day	,00	0,17 b	0,39	,00	1,00	,00	0,67 ab	1,23	,00	4,00	0,197
5th day	,00	0,08 b	0,29	,00	1,00	,00	0,50 ab	0,80	,00	2,00	0,102
6th day	,00	0,25 b	0,62	,00	2,00	,00	0,50 ab	0,80	,00	2,00	0,180
7th day	,00	0,25 b	0,62	,00	2,00	,00	0,33 b	0,78	,00	2,00	0,655
p	<b>0,001*</b>					<b>0,002*</b>					
<b>Wound size (mm)</b>											
7th day	104,00	108,58 a	41,81	50,00	200,00	106,00	117,04 a	33,39	75,00	175,00	0,410
14th day	84,25	85,04 b	31,37	44,00	133,00	85,00	82,08 b	24,88	30,00	120,00	0,477
21st day	65,00	67,96 bc	31,29	15,00	126,00	66,50	64,17 bc	22,24	27,00	100,00	0,398
30th day	51,50	53,00 c	22,61	12,00	85,00	46,00	46,75 c	20,09	24,00	90,00	0,285
p	<b>0,001*</b>					<b>0,001*</b>					
<b>LTH index</b>											
3rd day	1,00	1,25 e	0,45	1,00	2,00	1,00	1,25 e	0,45	1,00	2,00	0,999
7th day	2,00	2,08 d	0,51	1,00	3,00	2,00	1,92 d	0,29	1,00	2,00	0,157
14th day	3,00	2,67 c	0,49	2,00	3,00	2,50	2,50 c	0,52	2,00	3,00	0,157
21st day	3,50	3,50 b	0,52	3,00	4,00	3,00	3,42 b	0,67	3,00	5,00	0,564
30th day	4,00	4,42 a	0,51	4,00	5,00	4,00	4,42 a	0,51	4,00	5,00	0,999
p	<b>0,001*</b>					<b>0,001*</b>					
<b>Tissue thickness (mm)</b>											
Baseline	3,79	3,66 a	0,41	3,00	4,25	3,74	3,77 a	0,32	3,25	4,25	0,505
21st day	2,30	2,38 c	0,32	1,97	2,87	2,09	2,16 c	0,54	1,50	2,95	0,347
6th week	2,99	2,99 b	0,37	2,32	3,72	3,18	3,21 b	0,53	2,10	4,01	0,147
p	<b>0,001*</b>					<b>0,001*</b>					

a. b. c. d.e.: ↓ Taking different lowercase letter in the same column, the difference between tenses (periods) is significant

$p < 0.05$ : statistically significant

LTH: Landry, Turnbull, and Howley index, Max.: maximum, Min.: minimum, mm: millimetre, St. Dev.: standard deviation

In the CG, it was noted that a significantly higher number of analgesics were used on day 1 compared to days 3, 4, 5, 6, and 7. No significant difference was

found in analgesic usage on other days. In the TG, intragroup comparisons revealed a significant difference in total analgesic usage. Accordingly, the

difference between day 1 and day 7 was statistically significant, while the difference between the other days was similar. No significant difference was found in total analgesic usage in the comparison between the groups. On day 1, analgesic usage was the same in both groups.

There was no significant difference in WS, in the LTH index, or in TT between the groups. The grading of the LTH index revealed significant differences in intra-group comparisons. The greatest healing was observed on day 30 in both groups. In terms of the TT, intragroup comparisons revealed that the greatest healing occurred significantly at week 6 in both groups. When the difference between the groups in terms of the amount of change between the times was analyzed, only the change in TT between the 21st day and the 6th week was found to be statistically significant ( $p=0.028$ ) (Table 4). Accordingly, there was an increase of 0.61 mm in the TT in the CG at week 6 compared to day 21, while there was an increase of 1.05 mm in the TG. According to this, it can be said that the amount of improvement in the test group is greater than the control group.

**Table 4** Analysing the amount of change between times for wound size and tissue thickness

	Control Group		Test Group		p
	Mean	St. Dev.	Mean	St. Dev.	
Δ Wound size 7 <sup>th</sup> -14 <sup>th</sup> day	23,54	24,82	34,96	25,56	0,279
Δ Wound size 7 <sup>th</sup> -21 <sup>st</sup> day	40,63	21,09	52,88	26,76	0,226
Δ Wound size 7 <sup>th</sup> -30 <sup>th</sup> day	55,58	26,21	70,29	31,93	0,230
Δ Wound size 14 <sup>th</sup> -21 <sup>st</sup> day	17,08	11,78	17,92	12,94	0,870
Δ Wound size 21 <sup>st</sup> -30 <sup>th</sup> day	14,96	10,91	17,42	14,27	0,640
Δ Tissue thickness Baseline-21 <sup>st</sup> day	1,28	0,38	1,61	0,44	0,064
Δ Tissue thickness Baseline-6 <sup>th</sup> week	2,49	0,46	2,77	0,32	0,104
Δ Tissue thickness 21 <sup>st</sup> -6 <sup>th</sup> week	-0,61	0,36	-1,05	0,53	<b>0,028*</b>

Mann-Whitney U test

$p<0.05$ : statistically significant

St. Dev.: standard deviation

## DISCUSSION

In periodontology and implant dentistry, the method of soft tissue grafting from the palatal region is a widely used procedure. FGG is one of the most preferred of these soft tissue grafts. Tavelli et al. <sup>21</sup> defined a safety zone for the removal of soft tissue grafts such as FGG from the palatal region, but various complications are still observed following FGG. These

complications that may occur during or after FGG include excessive bleeding, exposed bones, pain, and recurrent herpetic lesions.<sup>4</sup> Such undesirable conditions have led clinicians to conduct more comprehensive research to smoothly accelerate wound healing. Nevertheless, the palatal regions are preferred for obtaining soft tissue grafts.<sup>22,23</sup> In recent years, the majority of clinicians have preferred various agents to prevent complications. Keceli et al. <sup>5</sup> investigated alternative solutions for hemostasis and early wound healing using the ABS. Thus, it can be thought that the use of a hemostatic agent may be critical for factors such as bleeding, postoperative pain, and wound healing.

ABS is a medicinal plant extract used as a hemostatic agent. In an animal study, ABS application to bone defects was reported to histopathologically increase the formation of new bone in early bone healing while reducing the formation of inflammation and necrosis.<sup>24</sup> Guler et al. <sup>25</sup> in a recent animal study have suggested that ABS may support early periodontal regeneration in fenestration defects. The antibacterial properties of this plant were thus proven.<sup>8</sup> In addition, it was found that ABS significantly reduced wound diameter and inflammation while significantly increasing fibrosis.<sup>26</sup> In another animal study, orally administered ABS was reported to be non-toxic.<sup>27</sup> A review of its clinical use in dentistry shows that ABS has been used as part of antithrombotic therapy in the treatment of periodontal defects and tooth extraction, but there are limited number of randomized controlled studies on its use in the mucogingival area, especially at donor sites.<sup>5,10,12</sup> Our study has investigated the effectiveness of ABS in periodontal surgery, aiming to contribute to the literature with the results obtained.

Complications associated with bleeding in the palatine area may adversely affect the patient's health and quality of life, as well as reflect negatively on the patient's desire to undergo another surgical procedure. In our study, a significantly positive effect was observed in the palatal area where ABS was used in terms of intraoperative bleeding compared to the CG.

Keceli et al. <sup>5</sup> reported that the rate of wound closure in the donor area increased following FGG applications where ABS was used. The authors thought that due to the rapid clot formation provided by ABS, early healing could occur in the connective tissue, thus causing faster wound closure. Gul et al. <sup>9</sup>

observed an increase in epithelial regeneration in the 7, 14, and 21-day ABS groups although it was not statistically significant. Despite higher complete epithelialization in the TG on day 14 supports the results of our studies, no difference between the groups in our study. In addition, when the amount of change between the times was analyzed, only the change in TT between the 21st day and the 6th week was found to be statistically significant ( $p=0.028$ ). According to this, it can be said that the amount of healing in the TG is greater than the CG in terms of TT.

In FGG surgery, donor sites heal through secondary wound healing, which is known to be associated with postoperative pain.<sup>3</sup> There are various agents or treatment methods to reduce postoperative pain. Hemostatic collagen or gelatin sponge has been shown to significantly reduce patient morbidity compared to spontaneous secondary healing, especially when combined with cyanoacrylate tissue adhesive.<sup>6</sup> Similarly, platelet-rich fibrin (PRF) was found to be associated with lower postoperative pain scores when compared with spontaneous healing.<sup>28,29</sup> The evaluation of the VAS pain scores related to ABS in our study revealed no significant difference between the groups, but interestingly, it was observed that the pain score average tended to be higher on all days except the first day in the TG. In parallel, although the TG displayed higher analgesic intake on days 2, 3, 4, 5, and 7 compared to the CG, no significant difference was found in total analgesic intake in the comparison between the groups. It should not be ignored that these results might have been affected by many factors due to the nature of pain sensation. Since pain is a subjective measurement, it can vary considerably among individuals. Another important factor in this regard is that the preferred VAS scale may tend to yield different results.<sup>30</sup> Therefore, although it is a valid method, it has some limitations. However, prospective studies with larger samples are needed for a definite conclusion.

Since available studies are insufficient to conduct comparisons, we examined studies evaluating LTH index scores in palatal wound healing using PRF. Kızıltoprak and Uslu<sup>14</sup> also reported that the LTH scores of the autologous fibrin glue group were significantly higher than the control and injectable-PRF (i-PRF) groups. Similarly, Samani et al.<sup>20</sup> reported that LTH index scores were significantly higher in the platelet-rich plasma group compared to the control

group. In our study, contrary to these studies, no significant difference was found in LTH index scores between the groups. We think that this is due to the fact that the short-term healing was slower in the ABS group than the CG.

The presented study had some limitations. In our study, the small number of patients, the lack of gender equality, and the absence of long-term results constitute the main limitations. Another limitation was that the program was not used to the calculation of the WS and the practice of home care was patient-centered, despite the training of patients on wound care.

## CONCLUSION

In our study, it can be said that ABS has a positive effect on intraoperative bleeding, short-term complete epithelialization, and long-term TT following FGG surgery. However, ABS has been observed to be insufficient in providing an advantage over collagen sponge alone in increasing early wound healing, reducing the amount of analgesic usage, and reducing postoperative pain. As a result, we believe that large-scale studies with a larger sample size may yield more accurate results in elucidating the effectiveness of ABS.

**Ethics Committee Approval:** Ethical approval for the study was obtained from the Clinical Research Ethics Committee of Van Yüzüncü Yıl University (25.12.2020/02)

**Financial Support:** The authors declare that this study received no financial support.

**Conflict of Interest:** The authors deny any conflicts of interest related to this study.

**Author Contributions:** Design: ACT, DA, Data Collection and Processing: DA, Analysis and Interpretation: DA, MC, BE, Literature Review: DA, MC, Writing - Original Draft: DA, Critical Review: ACT, BE.

## REFERENCES

1. Perussolo J, Souza AB, Matarazzo F, Oliveira RP, Araújo MG. Influence of the keratinized mucosa on the stability of peri-implant tissues and brushing discomfort: A 4-year follow-up study. *Clin Oral Implants Res.* 2018;29:1177-85.
2. Zucchelli G, Tavelli L, McGuire MK, Rasperini G, Feinberg SE, Wang H, et al. Autogenous soft tissue grafting for periodontal and peri-implant plastic surgical reconstruction. *J Periodontol.* 2020;91:9-16.
3. Wessel JR, Tatakis DN. Patient outcomes following subepithelial connective tissue graft and free gingival graft procedures. *J Periodontol.* 2008;79:425-30.
4. Brasher WJ, Rees TD, Boyce WA. Complications of

- free grafts of masticatory mucosa. *J Periodontol.* 1975;46:133-8.
5. Keceli HG, Aylıkci BU, Koseoglu S, Dolgun A. Evaluation of palatal donor site haemostasis and wound healing after free gingival graft surgery. *J Clin Periodontol.* 2015;42:582-9.
  6. Tavelli L, Ravidà A, Saleh MHA, Maska B, Del Amo FSL, Rasperini G, et al. Pain perception following epithelialized gingival graft harvesting: a randomized clinical trial. *Clin Oral Investig.* 2019;23:459-68.
  7. Goker H, Haznedaroglu IC, Ercetin S, Kirazli S, Akman U, Ozturk Y, et al. Haemostatic actions of the folkloric medicinal plant extract Ankaferd Blood Stopper. *J Int Med Res.* 2008;36:163-70.
  8. Tasdelen Fisgin N, Tanriverdi Cayci Y, Coban AY, Ozatli D, Tanyel E, Durupinar B, et al. Antimicrobial activity of plant extract Ankaferd Blood Stopper. *Fitoterapia.* 2009;80:48-50.
  9. Gül M, Günay A, Tanik A. An evaluation of the effects of caffeic acid phenethyl ester and Ankaferd blood stopper on secondary wound healing of oral mucosal tissue. *Turk J Med Sci.* 2020;50:248-57.
  10. Çakarar S, Eyüpoğlu E, Günes ÇÖ, Küseoğlu BG, Berberoğlu HK, Keskin C. Evaluation of the hemostatic effects of Ankaferd blood stopper during dental extractions in patients on antithrombotic therapy. *Clin Appl Thromb Hemost.* 2013;19:96-9.
  11. Evren C, Çınar F, Sarıkaya S, Alpay A, Bektas S. Ankaferd "Blood Stopper" in Tükürük Bezi Kanamasında Etkinliği Effectiveness of Ankaferd Blood Stopper on Salivary Gland Bleeding. *J Kartal TR.* 2012;23:1-5.
  12. Pamuk F, Cetinkaya BO, Keles GC, Ballı U, Koyuncuoglu CZ, Cıntan S, et al. Ankaferd blood stopper enhances healing after osseous grafting in patients with intrabony periodontal defects. *J Periodontal Res.* 2016;51:540-7.
  13. Sullivan HC, Atkins JH. Free autogenous gingival grafts. I. Principles of successful grafting. *Periodontics.* 1968;6:121-9.
  14. Kızıltoprak M, Uslu MÖ. Comparison of the effects of injectable platelet-rich fibrin and autologous fibrin glue applications on palatal wound healing: a randomized controlled clinical trial. *Clin Oral Investig.* 2020;24:4549-61.
  15. Ustaoglu G, Ercan E, Tunali M. Low-level laser therapy in enhancing wound healing and preserving tissue thickness at free gingival graft donor sites: a randomized, controlled clinical study. *Photomed Laser Surg.* 2017;35:223-30.
  16. Del Pizzo M, Modica F, Bethaz N, Priotto P, Romagnoli R. The connective tissue graft: a comparative clinical evaluation of wound healing at the palatal donor site. A preliminary study. *J Clin Periodontol.* 2002;29:848-54.
  17. Price DD, McGrath PA, Rafii A, Buckingham B. The validation of visual analogue scales as ratio scale measures for chronic and experimental pain. *Pain.* 1983;17:45-56.
  18. Landry RG, Turnbull RS, Howley T. Effectiveness of benzydamyne HCl in the treatment of periodontal post-surgical patients. *Res Clin Forums.* 1988;10:105-18.
  19. Marini L, Rojas MA, Sahrman P, Aghazada R, Pilloni A. Early wound healing score: a system to evaluate the early healing of periodontal soft tissue wounds. *J Periodontal Implant Sci.* 2018;48:274-83.
  20. Samani MK, Saberi BV, Ali Tabatabaei SM, Moghadam MG. The clinical evaluation of platelet-rich plasma on free gingival graft's donor site wound healing. *Eur J Dent.* 2017;11:447-54.
  21. Tavelli L, Barootchi S, Ravidà A, Oh TJ, Wang HL. What is the safety zone for palatal soft tissue graft harvesting based on the locations of the greater palatine artery and foramen? a systematic review. *J Oral Maxillofac Surg.* 2019;77:271.e1-271.e9.
  22. Bertl K, Pifl M, Hirtler L, Rendl B, Nürnberger S, Stavropoulos A, et al. Relative composition of fibrous connective and fatty/glandular tissue in connective tissue grafts depends on the harvesting technique but not the donor site of the hard palate. *J Periodontol.* 2015;86:1331-9.
  23. Zucchelli G, Mazzotti C, Mounssif I, Mele M, Stefanini M, Montebugnoli L. A novel surgical-prosthetic approach for soft tissue dehiscence coverage around single implant. *Clin Oral Implants Res.* 2013;24:957-62.
  24. İşler SC, Demircan S, Çakarar S, Çebi Z, Keskin C, Soluk M, et al. Effects of folk medicinal plant extract Ankaferd Blood Stopper® on early bone healing. *J Appl Oral Sci.* 2010;18:409-14.
  25. Güler Ş, Cetinkaya BO, Kurt Bayrakdar S, Ayas B, Keles GC. Comparison of the effectiveness of Ankaferd Blood Stopper® and Emdogain in periodontal regeneration. *Oral Dis.* 2022;28:1947-57.
  26. Kaya, H, Gokdemir, M. T., Sogut, O. Effects of folk medicinal plant extract ankaferd blood stopper on burn wound healing. *Acta Medica Mediterranea.* 2013;29:497-502.
  27. Bilgili H, Captug O, Kosar A, Kurt M, Kekilli M, Shorbagi A, et al. Oral systemic administration of Ankaferd blood stopper has no short-term toxicity in an in vivo rabbit experimental model. *Clin Appl Thromb Hemost.* 2010;16:533-6.
  28. Bahammam MA. Effect of platelet-rich fibrin palatal bandage on pain scores and wound healing after free gingival graft: a randomized controlled clinical trial. *Clin Oral Investig.* 2018;22:3179-88.
  29. Ozcan M, Ucak O, Alkaya B, Keceli S, Seydaoglu G, Haytac MC. Effects of platelet-rich fibrin on palatal wound healing after free gingival graft harvesting: a comparative randomized controlled clinical trial. *Int J Periodontics Restorative Dent.* 2017;37:e270-8.
  30. Dias SBF, Fonseca MVA, Dos Santos NCC, Mathias IF, Martinho FC, Junior MS, et al. Effect of GaAIIAs low-level laser therapy on the healing of human palate mucosa after connective tissue graft harvesting: randomized clinical trial. *Lasers Med Sci.* 2015;30:1695-702.