

Endolaryngeal diode laser surgery for early glottic carcinomas involving anterior commissure

Umit Tuncel, Caner Kilic

Department of Otorhinolaryngology, Ankara Dr. Abdurrahman Yurtaslan Oncology Training and Research Hospital, Ankara, Turkey

ABSTRACT

Objectives. In this study, we present the results of endolaryngeal diode laser surgery in patients with an early stage laryngeal carcinoma involving the anterior commissure (AC). **Methods.** A total of 108 patients (103 males, five females; mean age: 52.4 years; range; 31 to 75 years) who were treated between January 2010 and January 2015 were included in this study. All patients with glottic cancer had anterior commissure lesions. Complications, recurrence rates, and overall survival associated with diode laser surgery were recorded. **Results.** Based on the AC classification, the initial local control rate was 89.4% for the AC0 tumors, 81.3% for the AC1 tumors, and 90% for the AC2 tumors. Five-year disease-free and overall survival rates were 93.1% and 98.3, respectively. **Conclusion.** This study provides evidence that microscopic endolaryngeal diode laser surgery is a safe and effective option for the treatment of early glottic cancer involving the AC.

Eur Res J 2017;3(2):182-187

Keywords: Glottic carcinoma, anterior commissure, diode laser surgery, survival

Introduction

The advances in laser technology have produced refined techniques and devices, resulting in a major change from open surgical procedures to endolaryngeal laser surgery in the treatment of early laryngeal cancer. In 1970s, CO₂ laser-complemented cold instrumentation began to use in the endoscopic laryngeal surgery [1]. The CO₂ laser provides a bloodless surgery with minimum charring and without postoperative edema and need for tracheostomy. Despite these advantages, there are certain disadvantages of CO₂ laser surgery. In particular, the

equipment requires a large capital outlay and some extensions of the pathology, such as the anterior commissure (AC) and subglottis, and is unable to be approached transorally with a free beam CO₂ laser. In addition, microlaryngeal tangential dissection and office-based laryngeal procedures are limited by the lack of a fiber-based delivery system [2]. To address these limitations, a fiber transmissible wavelength, such as potassium titanyl phosphate (KTP) and diode laser, was introduced to endolaryngeal surgery. These lasers function similarly to a CO₂ laser with the benefit

Address for correspondence:

Caner Kilic, MD., Ankara Dr. Abdurrahman Yurtaslan Oncology Training and Research Hospital, Department of Otorhinolaryngology, Mehmet Akif Ersoy Cd., 13. Sk., No: 56, Yenimahalle, 06200 Ankara, Turkey E-mail: canerkilic80@gmail.com

Received: March 06, 2017; Accepted: April 06, 2017; Published Online: April 21, 2017

Copyright © 2017 by The Association of Health Research & Strategy

of being delivered through a small glass fiber.

One laser which has gained utilization during the past decade is the 980-nm wavelength diode laser system for the microscopic endolaryngeal surgery. Many studies have demonstrated that diode laser is easily used, effective, and safe for the management of different pathologies in the larynx [3, 4].

In the present study, we aimed to assess the oncological results using microscopic endolaryngeal diode laser surgery (MDLS) in early glottic carcinomas involving the AC.

Methods

The study was approved by the Institutional Review Board of Ankara Oncology Training and Research Hospital and was conducted in accordance with the ethical standards of the 1964 Declaration of Helsinki. A written informed consent was obtained from each patient.

Between January 2010 and January 2015, 108 patients with a T1-T2 glottic carcinoma involving the AC were treated with MDLS. Inclusion criteria were the lack of a previous history of potentially metastatic adenopathy or distant secondary neoplasms, and being treatment-naïve. All the patients had squamous cell carcinoma of the glottic region with normal or impaired vocal cord mobility.

The tumors were defined according to the 2012 American Joint Committee on Cancer/International Union against Cancer Tumor - node - metastasis (TNM) system and the involvement of the AC. AC is the area where both vocal ligaments form anterior. According to the AC classification, AC0 describes tumors which do not involve any subsite of the AC, AC1 describes tumors with the involvement of the AC on only one side of the midline, AC2 describes tumors with the involvement of the subsite which crosses the midline on only part of the longitudinal extension of the subsite, and AC3 describes tumors with the involvement of the whole subsite on both sides of the midline [5].

A gallium-aluminum-arsenide diode laser (Wuhan Gigaa Optronics Technology, Wuhan, China) with the following specifications was used to excise the tumor in all cases: power 3 to 9 W and wavelength 980 nm with a 400-mm fiber and continuous wave mode.

Technique

A gallium-aluminum-arsenide diode laser (Wuhan

Gigaa Optronics Technology, Wuhan, China) with the following specifications was used to excise the tumor in all cases: power 3 to 9 W and wavelength 980 nm, with a 400-mm fiber and continuous wave mode. MDLS is performed through a laryngoscope with the benefit of an operating microscope. The cutting is performed with a hand held fiber delivery systems using straight or 30° angled instruments. The instruments are specifically designed for laryngeal surgery with different lengths. The laser works in a contact manner to cut the tissue but can also be used in a spread form for coagulation. The tip of the fiber needs to protrude from the instrument 3-4 mm so that the fiber can touch the tissue.

The patients were intubated with a protected endotracheal tube, and the tube was inflated using saline with methylene blue dye. The patient was placed in a supine position with the head fully extended. The dentition was protected using a plastic tooth guard. Using a rigid laryngoscope, the larynx was visualized through the laryngoscope. After adequate exposure was obtained, the laryngoscope was fixed using a suspension arm. Then the microscope was brought into position. At first, the surgical margins were marked by making small shots around the tumor. En bloc resection was preferred by cutting around the tumor and removing it in 1 piece. After removal, all specimens were analyzed under the operative microscope and frozen sections were sent only if the surgeon was suspicious for unclear surgical margins. Repeated frozen sections were performed until the section was free of tumor.

Statistical Analysis

The cumulative probability of surviving was analyzed according to the Kaplan-Meier method. Using this method, we studied the disease-free interval according to local control results. The statistical significance of the differences in the cumulative survival tables was tested with the log-rank test with an error of 5% (i.e., significant at $p \leq 0.05$). The data were collected using an Excel (Microsoft, Redmond, Washington, USA) spreadsheet. All analyses were performed using the SPSS for Windows version 15.0 software (SPSS Inc., Chicago, IL, USA).

Results

Of the patients, 103 were males and five were females with a mean age of 52.4 (range; 31 to 75)

years. The mean follow-up was 51.5 (range; 25 to 60) months. There was no perioperative mortality. None of the patients were lost to follow-up. Web developed in 6 (5.5%) patients. The lesions of the patients developing web were AC1-2. The web was involving more than one-third of the vocal cords only in one patient and it was resected with a diode laser. Perichondritis developed in 2 (1.8%) patients. These complications were spontaneous in all patients.

Intraoperative frozen-sections were sent for 28 patients. The results showed that the margins were clear. Pathological examination of the specimens revealed that the surgical margins were positive for the tumor in 22 (20.4%) patients. Finally, free surgical margins were achieved in 86 (79.6%) patients.

The initial five-year local control rate was 93% for the tumors with negative surgical margins and 63.6% for the tumors with positive surgical margins. This positivity was not related to the tumor localization and TNM stage, but it may be associated with tumor volume. The initial five-year disease-free survival was 92.7% for the tumors with negative surgical margins

and 47.7% for the tumors with positive surgical margins. These findings indicated a significant difference ($p=0.001$).

Details on tumor classes and recurrences are given in Table 1. The initial five-year local control and laryngeal preservation rates for all patients were 87% and 99.1%, respectively. Regarding the AC classification, the initial local control rate was 89.4% for the AC0 tumors, 81.3% for the AC1 tumors, and 90% for the AC2 tumors. However, there was no significant difference between the initial local control rates of AC0 and AC1-2 tumors ($p=0.456$).

At the time of this analysis, 106 of 108 patients (98.1%) were alive with no evidence of disease, two (1.8%) patients died from a second primary lung tumor. Twelve (11.1%) patients had local and two (1.9%) patients had locoregional failure within 25 to 38 months after treatment. Among 22 patients whose surgical margins were reported as positive, eight (36.4%) had recurrence.

According to the Kaplan-Meier method, the estimated five-year disease-free and overall survival

Table 1. Patient characteristics

	T1 (n=64)	T2 (n=44)	AC0 (n=66)	AC1-2 (n=42)
Locoregional control	60 (93.8)	34 (77.3)	59 (89.4)	35 (83.3)
Local recurrence	4 (6.2)	8 (18.2)	7 (10.6)	5 (11.9)
Locoregional recurrence	-	2 (4.5)	-	2 (4.8)
Treatment of local recurrence				
MDLS	4 (6.2)	5 (11.4)	5 (7.6)	4 (9.5)
RT	-	2 (4.5)	2 (3)	-
Partial laryngectomy	-	2 (4.5)	-	2 (4.8)
Total laryngectomy	-	1 (2.3)	-	1 (2.4)
Second recurrence	1 (1.5)	2 (4.5)	1 (1.5)	2 (4.8)
Ultimate larynx preservation rate, %	100	97.7	100	97.7

*Values are presented as number (percentage) unless otherwise indicated, MDLS=microscopic endolaryngeal diode laser surgery, RT=radiotherapy; AC=anterior commissure, - =no patients

Table 2. Oncological Results

	DFS at 5 years	p value	OS at 5 years	p value
T1	93.1%	0.019	98.3%	0.783
T2	76.3%		97.4%	
AC0	88.7%	0.603	98.4%	0.117
AC1	79.6%		100%	
AC2	90%		90%	

AC=anterior commissure, DFS=disease free survival, OS=overall survival

for MDLS were 85.9% and 98.1%, respectively. The estimated five-year disease-free survival after any type of salvage treatment was 100%. Regarding T stage, the estimated five-year disease-free rate was 93.8% for T1 tumors and 77.3% for T2 tumors. The difference between the initial local control rates of T1 and T2 tumors was significant ($p=0.019$). The estimated five-year disease-free and overall survival rates according to the AC classification are shown in Table 2. There was no statistically significant difference in terms of prognosis according to AC and TNM classifications. The five-year disease-free survival curves according to the AC classification are presented in Figure 1.

Discussion

A diode laser is a portable laser which is delivered down a fine glass fiber and used with straight or angled handheld probes [3]. The use of handheld probes allows the surgeon resecting deep and curved parts of the larynx easier and safer than with a standard CO₂ laser. The 980-nm diode laser is a new technology, and it has been demonstrated that the 980-

nm diode laser accelerates the wound-healing process by changing the expression of PDGF and bFGF genes responsible for the stimulation of cell proliferation and fibroblast growth [6]. This special feature of the 980-nm diode laser allows it to become a strong alternative to the CO₂ laser [7]. In a review, Arroyo *et al.* [7] reported that diode laser can be a useful tool for the treatment of different laryngeal pathologies.

Diode laser has recently been used for pediatric airway diseases [3, 4]. In 2008, Ferri *et al.* [8] were the first who reported the early oncological results of endolaryngeal endoscopic diode laser surgery for Tis and T1 glottic laryngeal cancer. In 2010, diode laser was introduced in Turkey and, in the light of this study, we began to use MDLS for early glottic cancer. In addition to the oncological and functional success of diode laser surgery, this is predominantly due to the cost of CO₂ laser per patient being more than 2.5 fold of diode laser treatment in Turkey and the lack of reimbursement policies from the current health insurance systems.

On the other hand, although almost 40% of the patients in our study underwent AC1-2 resection, the rate of anterior glottic web was lower in MDLS than in standard CO₂ laser surgery (5.5% vs 10.6%).

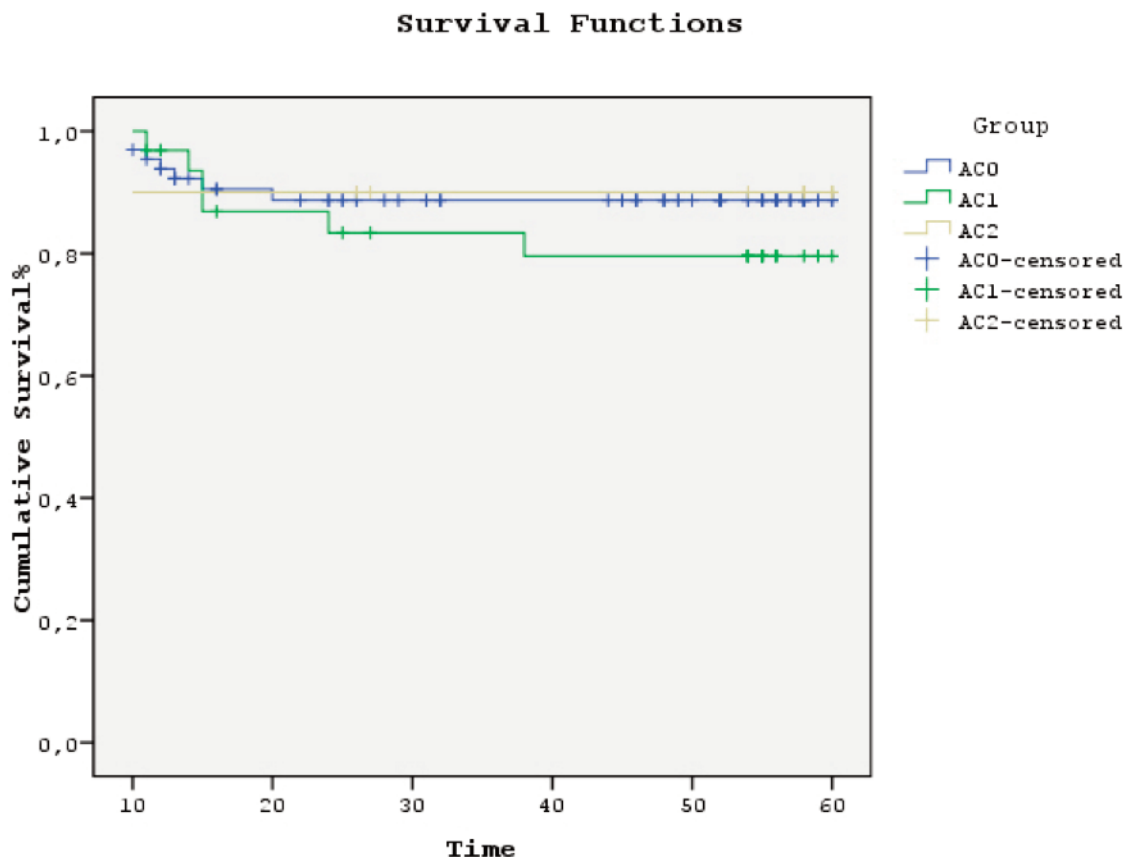


Figure 1. Disease-free survival for AC0, AC1, and AC2 tumors at five-year after primary surgery

In our practice, the use of angled probes during AC resection allows the surgeon resecting deeply enough to reach and feel the thyroid cartilage. The deep resection results in a defect in the AC region which prevents the contact of the vocal folds and heals with a fibrotic tissue attached to the AC, rather than a bulky tissue obliterating the AC. Furthermore, the complication rate of perichondritis caused by the dissection of the inner surface of the thyroid cartilage which we experienced is problematic. This likely relates to the necrosis of the inner perichondrium. In our experience, it is much more difficult to preserve the inner perichondrium of the thyroid cartilage in MDLS than in CO₂ laser. The fact that high-power densities used is the additional factor relating to our complication rate. We, therefore, recommend using the MDLS with a laser power setting of 3 to 5 W.

Furthermore, for CO₂ laser surgery, there is a controversy about the impact of AC involvement on the recurrence rates in the literature. Some authors found an association between AC involvement and increased rate of recurrence, whereas some authors suggested that AC involvement was not significant for local control [13, 14]. It is critical to remind that resection of the tumors involving AC is very difficult and has a very steep learning curve using standard CO₂ laser [14]. Our results demonstrated that the rates of local recurrence were similar in both AC0 and AC 1-2 tumors with MDLS. In our practice, no special experience is needed for the resection of AC in MDLS, as the handheld probe is so much like a cutting instrument used in routine microlaryngeal surgery.

In addition, there is a controversy about the impact of positive surgical margins on the recurrence rates in the literature for CO₂ laser surgery. The main reason of this controversy is the collateral thermal effect of laser on the margins of the incision which results in an additional control margin. Our study demonstrated that although the collateral thermal effect of diode laser is much higher than CO₂ laser, the five-year disease-free survival of the patients who had positive surgical margins was significantly shorter, compared to the patients who had clear surgical margins. Lesions of patients with positive surgical margins may have progressed submucosally. Lesions of patients with positive surgical margins may have progressed submucosally. These lesions are macroscopically safe when removed by surgically. The patients were not treated with adjuvant treatment. Follow-up was performed at close intervals and re-resection was performed on suspicious lesions.

Conclusions

This study provides evidence that MDLS is a safe and effective option for the treatment of early glottic cancer involving the AC. Similar rates of local recurrence in both AC0 and AC1-2 tumors suggest that MDLS can be a strong alternative of CO₂ laser, particularly for the tumors involving the AC.

Conflict of interest

The authors disclosed no conflict of interest during the preparation or publication of this manuscript.

Financing

The authors disclosed that they did not receive any grant during conduction or writing of this study.

References

- [1] Oswal V, Remacle M, Jovanvic S, Zeitels SM, Krespi JP, Hopper C, eds. Principles and Practice of Lasers in Otorhinolaryngology and Head and Neck Surgery. 2nd ed., Amsterdam: Kugler Publications; 2014.
- [2] Zeitels SM, Burns JA, Akst LM, Hillman RE, Broadhurst MS, Anderson RR. Office-based and microlaryngeal applications of a fiber-based thulium laser. *Ann Otol Rhinol Laryngol* 2006;115:891-6.
- [3] Bajaj Y, Pegg D, Gunasekaran S, Knight LC. Diode laser for paediatric airway procedures: a useful tool. *Int J Clin Pract* 2010;64:51-4.
- [4] Saetti R, Silvestrini M, Cutrone C, Narne S. Treatment of congenital subglottic hemangiomas: our experience compared with reports in the literature. *Arch Otolaryngol Head Neck Surg* 2008;134:848-51.
- [5] Remacle M, Eckel HE, Antonelli A, Brasnu D, Chevalier D, Friedrich G, et al. Endoscopic cordectomy: a proposal for a classification by the Working Committee, European Laryngological Society. *Eur Arch Otorhinolaryngol* 2000;257:227-31.
- [6] Usumez A, Cengiz B, Oztuzcu S, Demir T, Aras MH, Gutknecht N. Effects of laser irradiation at different wavelengths (660, 810, 980, and 1,064 nm) on mucositis in an animal model of wound healing. *Lasers Med Sci* 2014;29:1807-13.
- [7] Arroyo HH, Neri L, Fussuma CY, Imamura R. Diode laser for laryngeal surgery: a systematic review. *Int Arch Otorhinolaryngol* 2016;20:172-9.
- [8] Ferri E, Armato E. Diode laser microsurgery for treatment of Tis and T1 glottic carcinomas. *Am J Otolaryngol* 2008;29:101-5.
- [9] Lee M, Buchanan MA, Riffat F, Palme CE. Complications after CO₂ laser surgery for early glottic cancer: An institutional experience. *Head Neck* 2016;38 Suppl 1:E987-90.
- [10] Lee HS, Chun BG, Kim SW, Kim ST, Oh JH, Hong JC, et al. Transoral laser microsurgery for early glottic cancer as one-stage single-modality therapy. *Laryngoscope* 2013;123:2670-74.
- [11] Peretti G, Piazza C, Cocco D, De Benedetto L, Del Bon F,

Redaelli De Zinis LO, et al. Transoral CO(2) laser treatment for T(is)-T(3) glottic cancer: the University of Brescia experience on 595 patients. *Head Neck* 2010;32:977-83.

[12] Stoeckli SJ, Schnieper I, Huguenin P, Schmid S. Early glottis carcinoma: treatment according patient's preference? *Head Neck* 2003;25:1051-6.

[13] Sachse F, Stoll W, Rudack C. Evaluation of treatment results

with regard to initial anterior commissure involvement in early glottic carcinoma treated by external partial surgery or transoral laser microresection. *Head Neck* 2009;31:531-7.

[14] Steiner W, Ambrosch P, Rodel RM, Kron M. Impact of anterior commissure involvement on local control of early glottic carcinoma treated by laser microresection. *Laryngoscope* 2009;114:1485-91.