



# Association between Anesthesia Management and Preoperative Magnetic Resonance Image Quality in Patients Scheduled for Deep Brain Stimulation Surgery

Sezgin Bilgin<sup>1</sup>, Kerim Aslan<sup>2</sup>, Esra Turunc<sup>1</sup>, Burhan Dost<sup>1</sup>, Hakan Aygun<sup>3</sup>, Ersin Koksali<sup>1</sup>

<sup>1</sup>Ondokuz Mayıs University, Faculty of Medicine, Department of Anesthesiology and Reanimation, Samsun, Türkiye

<sup>2</sup>Ondokuz Mayıs University, Faculty of Medicine, Department of Radiology, Samsun, Türkiye

<sup>3</sup>Izmir Bakırçay University, Çiğli Regional Education Hospital, Department of Anesthesiology and Reanimation, İzmir, Türkiye

Content of this journal is licensed under a Creative Commons Attribution-NonCommercial-NonDerivatives 4.0 International License.



## Abstract

**Aim:** To investigate magnetic resonance image quality and the number of motion artifact-related repeated sequences based on anesthesia or sedation management during preoperative MR imaging for DBS surgery.

**Material and Methods:** The medical records of patients who underwent DBS procedures at the hospital of Ondokuz Mayıs University, between April 2011 and October 2021 were retrospectively analyzed. Age, gender, and diagnosis information were recorded for each case. Patients were grouped into general anesthesia, sedation, no sedation groups. The evaluation of magnetic resonance images was performed by a specialized in neuroradiology. The radiologist classified the image quality as good, moderate, or poor based on artifacts resulting from unwanted motion.

**Results:** A total of 127 patients, out of 190 patients, were included in the study. There were no significant differences in image quality based on anesthesia/sedation method and airway management ( $p>0.05$ ). No significant differences were observed in the number of repeated sequences when compared based on anesthesia/sedation method and airway management ( $p>0.05$ ).

**Conclusion:** General anesthesia, sedation, or no sedation during preoperative magnetic resonance imaging in patients with movement disorders did not result in significant differences in image quality and the number of sequences requiring repetition.

**Keywords:** Deep brain stimulation, magnetic resonance imaging, movement disorders, Parkinson's disease, anesthesia, sedation

## INTRODUCTION

Deep brain stimulation (DBS) is a surgical treatment option used in movement disorders such as Parkinson's disease (PD), essential tremor (ET), and dystonia. The surgical method involves the placement of stimulator electrodes into target nuclei located in the basal ganglia, followed by connection to a pacemaker implanted in the infraclavicular or abdominal region (1). Precise determination of the target nuclei's exact location is of utmost importance, not only to ensure the clinical effectiveness of the treatment but also to minimize the occurrence of unintended complications. Preoperative magnetic resonance (MR) imaging is one of the methods used in targeting the anatomical localization (2). However, the presence of artifacts during imaging in

patients with movement disorders can pose difficulties in determining the target and may require sequence repetition, leading to prolonged scan duration.

In adult patients, anxiety, claustrophobia, mental retardation, and movement disorders necessitate the administration of sedation or general anesthesia during MR imaging. Although sedation and general anesthesia procedures are considered relatively safe in the MR imaging suite (3), they require detailed preparation beforehand and a competent team trained in monitoring and airway interventions during imaging. The entry of the head into the magnet and the placement of receiver coils around it make airway access difficult during brain imaging. It is known that decreased ventilatory functions,

## CITATION

Bilgin S, Aslan K, Turunc E. Association between Anesthesia Management and Preoperative Magnetic Resonance Image Quality in Patients Scheduled for Deep Brain Stimulation Surgery. *Med Records*. 2023;5(Suppl 1):16-21. DOI:1037990/medr.1330987

Received: 21.07.2023 Accepted: 22.08.2023 Published: 03.10.2023

**Corresponding Author:** Sezgin Bilgin, Ondokuz Mayıs University, Faculty of Medicine, Department of Anesthesiology and Reanimation, Samsun, Türkiye

**E-mail:** sezgin.bilgin@omu.edu.tr

weakened cough reflex, and inadequate clearance of secretions in PD patients increase the frequency of post-anesthetic laryngospasm and aspiration pneumonia (4). When making the decision to apply sedation or general anesthesia during MR imaging, healthcare providers should consider the benefits it will offer, potential side effects, and costs involved.

There is limited data regarding whether the administration of sedation or general anesthesia during MR imaging in patients with movement disorders provides higher-quality images (5).

The aim of this retrospective study is to evaluate and compare the image quality and the frequency of motion artifact-related repeated sequences, in patients who underwent preoperative MR imaging for DBS surgery based on their anesthesia or sedation management.

## MATERIAL AND METHOD

### Study Population

This retrospective study was approved by the Ondokuz Mayıs University Medical Ethics Committee (approval number: 2022/157). The medical records of patients who underwent DBS procedures at the Department of Neurosurgery of our University, between April 2011 and October 2021 were retrospectively reviewed. The study included patients with accessible preoperative MR images and information regarding the administration of sedation or anesthesia during the imaging. Patients lacking accessible MR images, preoperative evaluations, and intraoperative monitoring forms, despite undergoing sedation or anesthesia administration, were excluded from the study.

### Data Collection

The records of patients who underwent DBS surgery were obtained from the hospital information management system, and the MR images were obtained from the radiological imaging archives. Preoperative evaluation and intraoperative monitoring forms were used to gather information on sedation and anesthesia management. Age, gender, and diagnosis information were recorded for each case. Data on airway management and medications used were collected for patients who received sedation or anesthesia.

### Evaluation of the MRI Records and MRI Protocol

The evaluation of MR images was performed by a radiologist specialized in neuroradiology. A randomized list of included patients was provided to the radiologist. The radiologist was asked to classify the image quality as good, fair, or poor based on artifacts resulting from involuntary motion. Additionally, the number of sequences requiring repetition during imaging was recorded for each patient.

MR images were obtained according to our institutional protocol with a 3T scanner (Ingenia, Philips Healthcare, Best, The Netherlands) using a 32-channel head coil. All examinations included a 3D T1-weighted conventional gradient echo (3D T1-TFE) sequence with and without

gadolinium (160 contiguous sagittal slices with an in-plane voxel resolution: 1x1x1 mm; repetition time [TR]/echo time [TE], 7.9/3.5 millisecond [ms], number of excitations [NEX], 1), 3D T2 fluid attenuation inversion recovery (FLAIR) sagittal (TR/TE/TI, 4800/381/1650 ms; section thickness, 3 mm; NEX, 2); T2W sagittal turbo spin-echo sequence (TR/TE, 3000/80 ms; section thickness, 5 mm; matrix, 261 x 384; NEX, 3); T2W axial turbo spin-echo sequence (TR/TE, 3000/80 ms; section thickness, 5 mm; matrix, 261 x 384; NEX, 3); and contrast-enhanced T1W axial conventional spinecho sequence (TR/TE, 606/17 ms; section thickness, 5 mm; FOV, 230; matrix, 230 x 384; NEX, 2).

### Anesthesia, Sedation and Related Side Effects

According to the obtained records, patients were classified into three groups: those who received general anesthesia, those who received sedation, and those who did not receive sedation. The general anesthesia procedure consisted of iv propofol induction (1-2.5 mg/kg bolus), rocuronium (0.6 mg/kg iv), endotracheal intubation, and mechanical ventilation, followed by propofol infusion (4-10 mg/kg/h). Sedation was defined as the administration of intravenous sedative agents while maintaining spontaneous respiration without the need for airway management. Patients who did not receive sedation were either not given any sedative agent or only received oral premedication. Respiratory, hemodynamic, and allergic side effects that could occur during anesthesia were recorded from the patients' anesthesia records.

### Statistical Analysis

The statistical analyses were performed using the NCSS (Number Cruncher Statistical System) 2007 software program (Kaysville, Utah, USA). Descriptive statistical methods such as mean, standard deviation, median, frequency, ratio, minimum, and maximum were used to evaluate the study data. The distribution of the data was assessed using the Shapiro-Wilk test. The Kruskal-Wallis test was used for comparing three or more groups of quantitative data, while the Mann-Whitney U test was used for comparing two groups. Chi-square analysis was employed to determine the relationship between qualitative variables. The significance level was evaluated at  $p < 0.05$ .

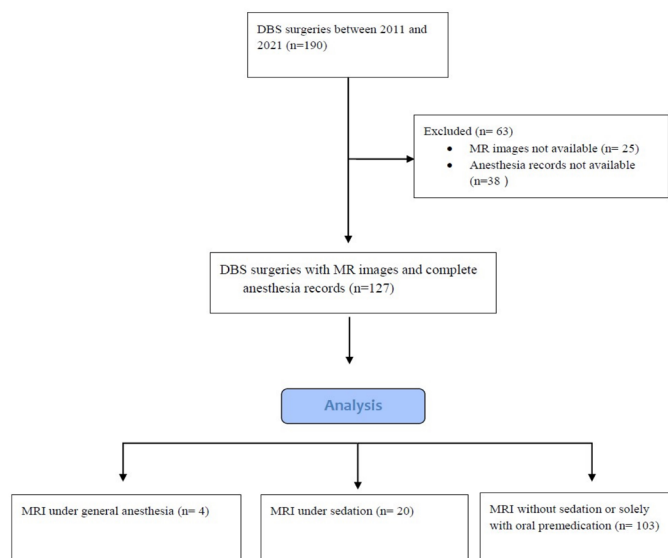
## RESULTS

A total of 127 patients, out of 190 patients identified as having undergone DBS surgery, were included in the study due to the availability of sufficient data. The age of the evaluated patients ranged from 18 to 77 years, with a mean age of  $55.23 \pm 13.78$ . Among the study participants, 39.4% ( $n=50$ ) were female, and 60.6% ( $n=77$ ) were male. Parkinson's disease was the most common preoperative diagnosis, accounting for 74% ( $n=94$ ) of the patients. The demographic characteristics and diagnostic information of the patients are presented in Table 1.

Among the patients, it was determined that no sedation was administered during MR imaging in 103 cases, general anesthesia with endotracheal intubation was performed in

4 cases, and sedation was administered in 20 cases (Figure 1). Out of the patients who did not receive sedation, 27 of them received oral diazepam premedication on the night before the scan. The most commonly preferred drugs for sedation were found to be propofol and midazolam. The distribution of patients according to the sedation method, drugs used, and airway management is shown in Table 2.

According to the assessment performed by the radiologist, 61.4% (n=78) of the patients' MR images were classified as good quality, 29.1% (n=37) as fair quality, and 9.4% (n=12) as poor quality. The number of repeated sequences ranged from 0 to 6, with a mean of  $2.32 \pm 1.33$ . When comparing image quality based on anesthesia/sedation method and airway management, no significant differences were found ( $p > 0.05$ ) (Table 3). Similarly, no significant differences were observed in the number of repeated sequences when compared based on anesthesia/sedation method and airway management ( $p > 0.05$ ) (Table 4). Except for two cases where mild allergic reaction was successfully resolved with antihistamine administration, no other side effects or complications were observed.



**Figure 1.** Flow chart detailing the exclusion criteria applied to all DBS surgeries with preoperative MR imaging. DBS, deep brain stimulation; MR imaging, magnetic resonance imaging

**Table 1. Demographic and diagnostic characteristics of the patients**

Age (years), (mean±sd)		55.23±13.78
Sex (n), (%)	Female/male	50 (39.4)/77 (60.6)
Diagnosis (n) (%)	Dyskinesia	1 (0.8)
	Dystonia	21 (16.5)
	Essential tremor	7 (5.5)
	Huntington's disease	2 (1.6)
	Multiple sclerosis	1 (0.8)
	Parkinson's disease	94 (74)
	Tourette syndrome	1 (0.8)

**Table 2. Airway and Anesthesia/Sedation management information of the patients**

Drug used (n)(%)	Diazepam (oral premedication)	27 (21.3)
	Midazolam	9 (7.1)
	Ketofol	2 (1.6)
	Ketamine	1 (0.8)
	Thiopental	3 (2.4)
	Propofol	10 (7.9)
	No drug administered	76 (59.1)
Airway management (n) (%)	Intubation	4 (3.1)
	Spontaneous breathing	123 (96.9)
Anesthesia/sedation management n (%)	No sedation	103 (81.1)
	General anesthesia	4 (3.1)
	Sedation	20 (15.7)

**Table 3. Image quality according to anesthesia/sedation management and airway management**

		Image quality n (%)			p
		Good	Moderate	Poor	
Anesthesia/sedation management	No sedation	64 (62.1)	29 (28.2)	10 (9.7)	0.92
	General anesthesia	3 (75)	1 (25)	0 (0)	
	Sedation	11 (55)	7 (35)	2 (10)	
Airway management	Intubation	3 (75)	1 (25)	0 (0)	0.76
	Spontaneous breathing	75 (61)	36 (29.3)	12 (9.8)	

**Table 4. Number of repeated sequences according to anesthesia/sedation management and airway management**

			n	Meant±sd	Min-Max (Median)	p
<b>Number of repeated sequences</b>	Anesthesia/ sedation management	No sedation	103	2.36±1.34	0-6 (3)	0.72
		General anesthesia	4	2±1.16	1-3 (2)	
	Airway management	Sedation	20	2.15±1.35	0-5 (2)	
		Intubation	4	2±1.16	1-3 (2)	
	Spontaneous breathing	123	2.33±1.34	0-6 (2)	0.65	

## DISCUSSION

In this retrospective study, which examined the records related to preoperative MR imaging of patients who underwent DBS procedures between April 2011 and October 2021 in our hospital, it was observed that the administration of general anesthesia or sedation during MR imaging did not result in better MR image quality compared to no sedation. Furthermore, when comparing the frequency of repeated sequences due to motion artifacts among the three groups, no significant difference was found. Although MR imaging is frequently performed for mapping prior to DBS surgery, data on the relationship between sedation or general anesthesia during MR imaging and image quality in patients with movement disorders are limited.

Contrary to our research, a recent study reported that the administration of general anesthesia during preoperative MR imaging of patients with movement disorders resulted in higher-quality images compared to intravenous sedation and no sedation (5). However, in the same study, the use of sedation did not demonstrate any superiority over no sedation. There are data in the literature indicating that sedation provides better image quality in pediatric patients and adults with anxiety disorders (6,7). The lack of any difference in image quality related to anesthesia management in our study could be attributed to several reasons. The severity of the movement disorder may have been taken into account while determining whether anesthesia or sedation should be administered to the patients for the MR imaging scan. The limited number of patients who received general anesthesia, only four patients in total, suggests that this option may have been preferred for patients with involuntary movements that did not improve even during rest or sleep. In patients who received sedation, the fact that the underlying cause necessitating sedation was the movement disorder rather than an anxiety disorder may have contributed to achieving similar results as in patients without sedation who had milder movement disorder.

Indeed, in our study, the rates of good quality images for patients without sedation and those with sedation were found to be 62.1% and 55%, respectively. In the previously mentioned study, these rates were reported as 65%, similar to our study (5). The attainment of a considerable number of good quality images even without sedation highlights the importance of patient selection when deciding on the necessity of anesthesia or sedation, considering the

increased costs and potential risks. The administration of sedation necessitates the use of medication, preparation procedures, monitoring, and dedicated personnel, thereby contributing to elevated costs through the extension of MR imaging room occupancy, recovery periods, and hospital stays (8). One study reported that sedation-requiring MR images accounted for one-third of all outpatient costs (9). Furthermore, although sedation and anesthesia are considered relatively safe when the necessary conditions are met, procedural sedation carries risks such as aspiration, respiratory depression, and laryngospasm that can lead to serious hypoxia (10). The use of coils in brain imaging during MR imaging and the positioning of the patient's head within the tunnel can further hinder access and increase these risks. However, no serious complications were encountered in this study.

While the rate of images classified as poor was approximately 10% in both the sedation and no-sedation groups, no patients in the general anesthesia group were found to have poor-quality images. In cases without sedation, this may be attributed to both the presence of movement disorders and the occasional inability to maintain stillness during the long imaging duration. The need for prolonged immobility is one of the main reasons that necessitate sedation during MR imaging (11). On the other hand, the inability to achieve sufficient image quality despite sedation may be attributed to decreased oropharyngeal tone and a tendency for obstruction, leading to artifact formation during spontaneous respiration.

Undesired movements and respiratory artifacts during MR imaging examinations can necessitate the repetition of specific sequences (12). This can lead to prolonged scan durations, disruptions in scheduled appointments, and increased costs. The purpose of anesthesia or sedation is to achieve immobility and obtain the best possible images. When comparing our patients in terms of the number of sequences requiring repetition, no significant differences were found. These findings suggest that the experience of the sedation team and patient selection play a role in determining the anesthesia management during MR imaging.

In our study, it was observed that the most commonly preferred drugs for sedation management were propofol and midazolam. Although propofol has been reported to trigger dyskinesia (13), it can still be used in patients with movement disorders (14) and is one of the frequently preferred agents for sedation in MR imaging units (15).

The use of dexmedetomidine has been reported for preventing the dyskinesia triggered by propofol (13). However, one patient who received dexmedetomidine in our study was excluded from the analysis due to unavailability of MR images. Whilst midazolam can cause dystonic extrapyramidal side effects (16), it still is used in Parkinson's patients and during the DBS procedure. Ketamine has been presented as an alternative in a recent case report for a DBS patient with severe dyskinesia who could not be adequately sedated with other drugs (17). It was observed that two of our patients received a combination of propofol and ketamine, and one patient received ketamine alone. Concerns regarding extended recovery, increased secretion, and the possibility of aspiration may have contributed to our sedation teams' choice for alternative medications over ketamine.

This study has certain limitations due to its retrospective design. The unavailability of specific information during the data collection process prevented us from determining how the anesthesia management selection was made and which criteria were considered. Similarly, it was not possible to compare the severity of patients' movement disorder symptoms for the same reason. Furthermore, evaluating the image quality in conjunction with the surgical targeting success and outcomes could have provided valuable information. Lastly, using computer-calculated objective image quality measures instead of manual scoring for image quality assessment could have yielded more unprejudiced results. However, due to the technical constraints and lengthy computational durations required for these methods (18), our study utilized the subjective interpretation of an experienced radiologist for the evaluation.

## CONCLUSION

In this retrospective study, the application of general anesthesia, sedation, or no sedation during preoperative MR imaging in patients with movement disorders did not result in significant differences in image quality and the number of sequences requiring repetition. Prospective studies evaluating the obtained images in conjunction with targeting accuracy and surgical outcomes are needed.

**Financial disclosures:** The authors declared that this study has received no financial support.

**Conflict of Interest:** The authors declare that they have no competing interest.

**Ethical approval:** This retrospective study was approved by the Ondokuz Mayıs University Medical Ethics Committee (approval number: 2022/157).

## REFERENCES

1. Chakrabarti R, Ghazanwy M, Tewari A. Anesthetic challenges for deep brain stimulation: a systematic approach. *N Am J Med Sci.* 2014;6:359-69.
2. Hartmann C, Fliegen S, Groiss S, et al. An update on best practice of deep brain stimulation in Parkinson's disease. *Ther Adv Neurol Disord.* 2019;12:1756286419838096.

3. Cravero JP, Blike GT, Beach M, et al. Incidence and nature of adverse events during pediatric sedation/anesthesia for procedures outside the operating room: report from the Pediatric Sedation Research Consortium. *Pediatrics.* 2006;118:1087-96.
4. Roberts DP, Lewis SJ. Considerations for general anaesthesia in Parkinson's disease. *J Clin Neurosci.* 2018;48:34-41.
5. Ronde EM, Silvasti-Lundell M, Pekkola J, et al. Preoperative magnetic resonance image quality in motion disorder patients scheduled for deep brain stimulation surgery. *Stereotact Funct Neurosurg.* 2020;98:363-70.
6. Bluemke DA, Breiter SN. Sedation procedures in MR imaging: safety, effectiveness, and nursing effect on examinations. *Radiology.* 2000;216:645-52.
7. Loh P-S, Ariffin MA, Rai V, et al. Comparing the efficacy and safety between propofol and dexmedetomidine for sedation in claustrophobic adults undergoing magnetic resonance imaging (PADAM trial). *J Clin Anesth.* 2016;34:216-22.
8. Nguyen XV, Tahir S, Bresnahan BW, et al. Prevalence and financial impact of claustrophobia, anxiety, patient motion, and other patient events in magnetic resonance imaging. *Top Magn Reson Imaging.* 2020;29:125-30.
9. Uffman JC, Tumin D, Raman V, et al. MRI utilization and the associated use of sedation and anesthesia in a pediatric ACO. *J Am Coll Radiol.* 2017;14:924-30.
10. Hinkelbein J, Schmitz J, Lamperti M, Fuchs-Buder T. Procedural sedation outside the operating room. *Curr Opin Anaesthesiol.* 2020;33:533-8.
11. Artunduaga M, Liu CA, Morin CE, Serai SD, et al. Safety challenges related to the use of sedation and general anesthesia in pediatric patients undergoing magnetic resonance imaging examinations. *Pediatr Radiol.* 2021;51:724-35.
12. Schreiber-Zinaman J, Rosenkrantz AB. Frequency and reasons for extra sequences in clinical abdominal MRI examinations. *Abdom Radiol.* 2017;42:306-11.
13. Deogaonkar A, Deogaonkar M, Lee JY, et al. Propofol-induced dyskinesias controlled with dexmedetomidine during deep brain stimulation surgery. *Anesthesiology.* 2006;104:1337-9.
14. Yim R, Leung K, Poon C, Irwin M. Peri-operative management of patients with Parkinson's disease. *Anaesthesia.* 2022;77:123-33.
15. Tang Y, Meng J, Zhang X, et al. Comparison of dexmedetomidine with propofol as sedatives for pediatric patients undergoing magnetic resonance imaging: a meta-analysis of randomized controlled trials with trial sequential analysis. *Exp Ther Med.* 2019;18:1775-85.
16. Prommer EE. Midazolam-induced extrapyramidal side effects. *Journal of Pain and Symptom Management.* 2008;36:e5-6.
17. Sokhal S, Goyal K, Sokhal N, et al. Intraoperative management of a patient for deep brain stimulation with severe dyskinesia and tremors: Ketamine to the rescue! *Asian J Neurosurg.* 2019;14:1275-6.
18. Mason A, Rioux J, Clarke SE, et al. Comparison of objective image quality metrics to expert radiologists' scoring of diagnostic quality of MR images. *IEEE Trans Med Imaging.* 2019;39:1064-72.