

Fractal analysis and radiomorphometric indices: comparison of mandibular bone structure changes on digital panoramic radiographs of smokers

Fraktal analiz ve radyomorfometrik indeksler: sigara içenlerin dijital panoramik radyografilerinde mandibular kemik yapısındaki değişikliklerin karşılaştırılması

Berrin Çelik, Zeynep Betül Arslan

Posted date:28.07.2023

Acceptance date:15.12.2023

Abstract

Purpose: The purpose of the study was to assess how smoking affected the mandibular bone structure using a variety of radiomorphometric indices and fractal dimension (FD) analysis.

Material and methods: 56 patients—28 smokers and 28 non-smokers—were included in this retrospective study. In the trabecular bone of the mandible, eight areas of interest of 45x45 pixels were chosen, and fractal dimension analysis was carried out. All digital panoramic radiographs were used to measure the mandibular index and mandibular cortical width. All values were compared between groups. Utilizing the Shapiro-Wilk test, independent samples t-test and Mann-Whitney U test, collected data were evaluated.

Results: A total of 56 patients between the ages of 18 and 52 were evaluated, 28 in the study group (12 female and 16 male) and 28 in the control group (12 female and 16 male). There was a statistically significant difference between the groups in ROI4 and ROI8, but not in the mean FD values of ROI1, ROI2, ROI3, ROI5, ROI6 and ROI7 in the mandibular trabecular bone. No statistically significant differences between groups were seen for PMI and MCW measures ($p>0.05$). There was a statistically significant difference between genders only in FD values of ROI5 and PMI measurements ($p<0.05$). The intraclass correlation coefficient (ICC) values for the FD, PMI and MCW measurements had excellent reliability.

Conclusions: The trabecular bone structures of the anterior of the mental foramen and the condyle were different in smokers. There was no difference in cortical bone structures.

Keywords: Fractal dimension, radiomorphometric indices, smoker, panoramic radiography, osteoporosis.

Çelik B, Arslan ZB. Fractal analysis and radiomorphometric indices: comparison of mandibular bone structure changes on digital panoramic radiographs of smokers. Pam Med J 2024;17:117-128.

Öz

Amaç: Çalışmanın amacı, çeşitli radyomorfometrik indeksler ve fraktal boyut (FB) analizi kullanarak sigaranın mandibular kemik yapısını nasıl etkilediğini değerlendirmektir.

Gereç ve yöntem: Bu retrospektif çalışmaya 56 hasta (28 sigara içen ve 28 sigara içmeyen) dahil edildi. Mandibulada, trabeküler kemikte 45x45 piksellik sekiz ilgi alanı seçildi ve fraktal boyut analizi yapıldı. Mandibular indeks ve mandibular kortikal genişliği ölçmek için dijital panoramik radyografiler kullanıldı. Tüm değerler gruplar arasında karşılaştırıldı. Shapiro-Wilk, bağımsız örneklem t-testi ve Mann-Whitney U testleri kullanılarak toplanan veriler değerlendirildi.

Bulgular: Çalışma grubunda 28 (12 kadın, 16 erkek), kontrol grubunda 28 (12 kadın, 16 erkek) olmak üzere yaşları 18 ile 52 arasında değişen toplam 56 hasta değerlendirildi. Gruplar arasında mandibular trabeküler kemikte ROI4 ve ROI8'de istatistiksel olarak anlamlı bir fark vardı, ancak ROI1, ROI2, ROI3, ROI5, ROI6 ve ROI7'nin ortalama FB değerlerinde fark yoktu. PMI ve MCW ölçümleri için gruplar arasında istatistiksel olarak anlamlı bir fark görülmedi ($p>0,05$). Cinsiyetler arasında yalnızca ROI5'in FB değerleri ve PMI ölçümlerinde istatistiksel olarak anlamlı farklılık vardı ($p<0,05$). FB, PMI ve MCW ölçümleri için sınıf içi korelasyon katsayısı (ICC) değerleri mükemmel güvenilirliğe sahipti.

Sonuç: Mental foramenin anterioru ve kondil bölgesindeki trabeküler kemik yapıları sigara içenlerde farklıydı. Kortikal kemik yapılarında fark yoktu.

Anahtar kelimeler: Fraktal boyut, radyomorfometrik indeksler, sigara, panoramik radyografi, osteoporoz.

Çelik B, Arslan ZB. Fraktal analiz ve radyomorfometrik indeksler: sigara içenlerin dijital panoramik radyografilerinde mandibular kemik yapısındaki değişikliklerin karşılaştırılması. Pam Tıp Derg 2024;17:117-128.

Berrin Çelik, Asst Prof. Ankara Yıldırım Beyazıt University, Faculty of Dentistry, Department of Dentomaxillofacial Radiology, Ankara, Türkiye, e-mail: bcelik@ybu.edu.tr (<https://orcid.org/0000-0002-3602-2354>)

Zeynep Betül Arslan, Asst Prof. Ankara Yıldırım Beyazıt University, Faculty of Dentistry, Department of Dentomaxillofacial Radiology, Ankara, Türkiye, e-mail: zbarslan@yahoo.com (<https://orcid.org/0000-0001-8826-1958>) (Corresponding Author)

Introduction

Universally, tobacco use is one of the most serious public health risks, killing about 8 million people worldwide each year [1]. The main addictive substance in tobacco is nicotine [2]. Apart from being addictive, nicotine has adverse effects on various body systems such as cardiovascular, gastrointestinal and respiratory systems. In addition to its systemic side effects, nicotine use is among the modifiable risk factors for certain types of cancer and bone diseases such as osteoporosis [2, 3]. In the world, smoking is the most popular way to consume tobacco [1].

Smoke exposure has been associated with the bone regeneration process, as it affects the reduction of bone formation and the increase of the mechanism of bone resorption [4]. It has been reported that smoking is a significant risk factor for both bone loss and fractures [5].

Osteoporosis (OP), described as asymptomatic bone disease, is a significant health problem that is increasingly common worldwide. It is characterized by low bone mass and degeneration of the bone's microarchitecture, which increases bone fragility and fracture risk [3, 6]. It is known that osteoporosis causes relatively more trabecular bone loss than cortical bone [3].

By using the box-counting algorithm, the mathematical technique of "fractal analysis" (FA) assesses changes in trabecular bone tissue [3, 7]. FA quantitatively describes the image complexity of the bone structure and correlates with the bone strength of the trabecular bone [3, 7, 8]. A more complex bone structure is characterized by a higher fractal dimension (FD) [7-9]. According to certain reports, fractal analysis is enough to detect osteoporotic disorders in the jaw bones [7, 8].

The fractal analysis method was used to assess complex structures in biology and medicine [3]. In the literature, there are studies showing that FA is useful in detecting changes in bone in the early period, especially in the medical field [10]. FA is an advantageous method that can quantitatively evaluate the trabecular bone structure and is cost-effective, non-invasive, accessible, and unaffected

by variable parameters such as projection geometry and density. Due to these advantages, it has been widely used in many fields, including dentistry, in recent years [11]. With fractal analysis in dentistry, studies have been carried out on different subjects such as the analysis of bone structure of patients with osteoporosis [6], using various systemic drugs [7-9, 12, 13] and systemic diseases [14-16], temporomandibular joint (TMJ) dysfunction [17], bruxism [11, 18], and evaluation of the bone around the implant [19, 20].

Apart from fractal analysis, radiomorphometric measurements such as panoramic mandibular index (PMI), mandibular cortical width (MCW) are essential markers for detection osteoporosis. These indices are simple and effective methods that can be used to detect osteoporotic conditions [7, 8, 10, 21, 22]. Both fractal analysis and radiomorphometric index measurements can be performed on panoramic radiographs used for routine dentistry examinations [9].

The objective of this study is to assess and compare both fractal analysis and radiomorphometric measurements of the mandibular bone on digital panoramic radiography in smokers and non-smokers.

Materials and methods

Ethical issues

The research was carried out in accordance with the guidelines of the Helsinki Declaration. The University's Ethical Committee approved the presented study. The panoramic radiographs of patients who requested hospital examinations in 2021 for a variety of reasons were examined for this retrospective investigation.

Patient selection and study design

Information about the medical conditions of all patients and the drugs they used, as well as demographic information such as age and gender of the patients, were gleaned from anamnesis records and the hospital's automation system.

The study was selected from panoramic radiographs containing explicit images of the mandibular anterior and posterior areas, TMJ,

mental foramen, and mandibular lower cortices. The individuals were between the ages of 18 and 52, smokers (smoking a pack of cigarettes for at least 1 year), and healthy (without a systemic illness that affects bone metabolism specifically). Exclusion criteria for individuals; panoramic radiography of the mandibular or maxillary arch with more than one missing tooth (excluding third molars), low diagnostic value, ghost image or artifact that would prevent analysis and measurements of the mandibular bone, complete or ongoing orthodontic radiographs with jaw fracture or pathological lesions in the evaluated area treatment history, parafunctional habits such as bruxism and TMJ disease, early or late menopause, alcohol and drug addiction, using anti-resorptive drugs, neurological and psychiatric diseases, taking long-term corticosteroid treatment and using drugs that affect bone metabolism patients were excluded.

A total of 56 patients were selected. Systemically healthy individuals who have smoked for at least 1 year were selected for the smoker group, and non-smokers were selected as the control group as non-smokers. The smoker and non-smoker groups were matched based on gender, with the groups consisting of 28 patients (16 males and 12 females).

Digital panoramic radiography

The same radiology technician utilized the dental panoramic device (Planmeca, Helsinki, Finland) to take all digital panoramic radiographs used for measurements with an exposure time of 16 seconds at 70 kVp, 12.5 mA. To ensure standardization in patients, the positioning recommendations recommended by the manufacturer were followed (Frankfurt plane horizontal to the ground, light beam markers were placed in appropriate areas). All patients were subjected to the same standard protocol.

Image preprocessing

The high resolution Tagged Image File Format (TIFF) was used to store the panoramic radiographs that matched the requirements and 8-bit grayscale depth, and a data set was created. For image standardization, all panoramic radiographs were set to 2976x1536 pixels using adobe photoshop CS6 Extended

(Adobe Systems Inc., San Jose, CA, USA). Image manipulation (magnification, contrast, and brightness) was strictly prohibited. The radiographs were examined using the 1920x1080 pixel resolution Windows XPTM Professional operating system.

Fractal dimension analysis

For FD analysis, the free ImageJ 1.53k (National Institutes of Health, USA) software was downloaded (<https://imagej.nih.gov/ij>). Each DPR performed a fractal dimension analysis using the box-counting technique suggested by White and Rudolph [23]. On the digital panoramic image of each patient, a total of eight region of interest (ROI) were selected in four different regions, bilaterally in the mandible trabecular bone: ROI1-8: the condylar subcortical region; ROI2-7: the gonial supracortical region; ROI3-6: above mandibular canal, the interdental area between the second premolar and first molar; ROI4-5: the area adjacent to the mental foramen (Figure 1). Due to anatomical difficulties and artifacts in the maxilla, a relevant area was not selected. The lamina dura, cortical structure, periodontal space and mandibular canal were not included in ROIs. Each ROI 45x45 pixel area was selected. The fractal dimension for each ROI was performed according to the steps defined by White and Rudolph (Figure 2) [23].

Radiomorphometric indices

Panoramic mandibular index

The thickness of the mandibular cortex (a) and the distance (b) between the lower edges of the mental foramen and the mandible were divided to create the PMI values (a/b) (Figure 3) [22].

Mandibular cortical width

For MCW measurement in accordance with Ledgerton et al. [24] definitions, a tangent line parallel to the lower nerve of the mandibular cortex was drawn at the level of the mental foramen in the premolar area. A line was stretched vertically from the mental foramen to the second parallel line, which was drawn along the superior nerve of the mandibular cortex. On this vertical line, the mandibular cortical width was calculated as the distance between two parallel lines (Figure 3).

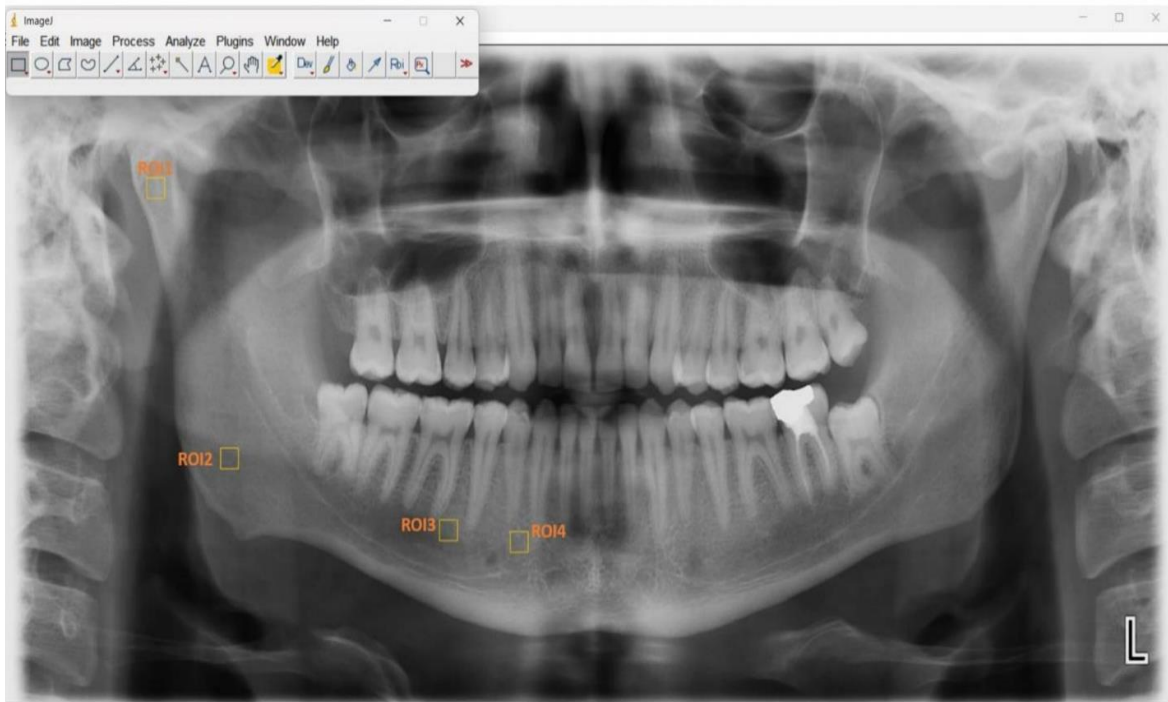


Figure 1. Selection of ROI in digital panoramic radiography with imagej




Figure 2. Steps of fractal dimension analysis of ROI7. a:ROI selection, b:Gaussian blur, c:subtraction d:Addition of 128 gray value, e:Binarization, f:Erosion, g:Dilatation, h:Inversion, i:Skletonization

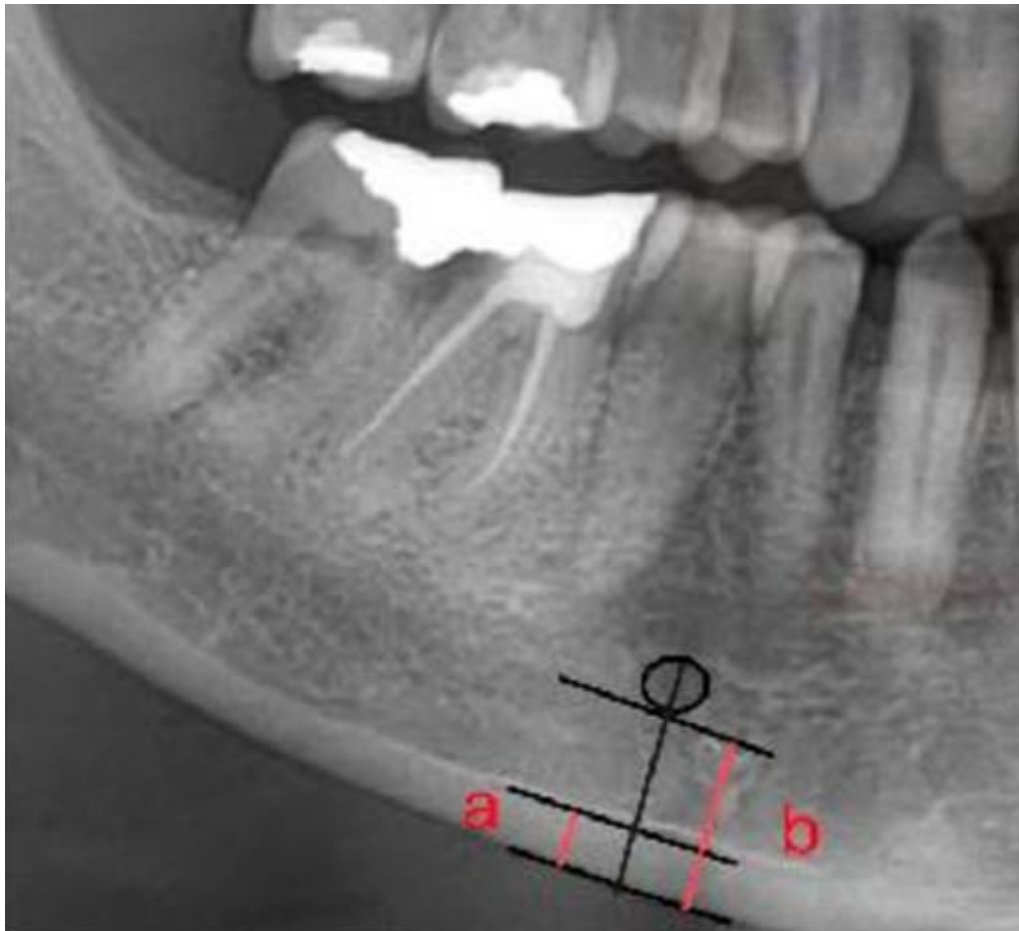


Figure 3. Measurements of mandibular cortical width (a) and panoramic mandibular index (a/b)

In the mandible, the mean values of the PMI and MCW measures were computed bilaterally. An expert in Oral and Maxillofacial Radiology (B.Ç) with six years of clinical experience conducted the FD analysis. Radiomorphometric measurements were performed in a dark room by an expert in Oral and Maxillofacial Radiology (Z.B.A.) with six years of clinical experience. Experts were blind to all information about individuals. For the intraobserver reliability of the obtained values, two weeks after the first measurements were made, 14 randomly selected panoramic images (25%) were re-measured and evaluated.

Statistical analysis

The IBM-SPSS (International Business Machines-Software Package for Social Sciences) statistical package, version 26 (SPSS, Chicago, IL, USA), was used to analyze the data from this study. At .05, the statistical significance level was determined. Intra-observer agreement

was evaluated with the intraclass correlation coefficient (ICC). Descriptive statistics were made for all parameters. To evaluate whether the data had a normal distribution, the Shapiro-Wilk test was performed. To compare normally distributed FD, PMI, and MCW values between groups and gender, an independent samples t-test was utilized. The Mann-Whitney U test was used to compare variables that did not exhibit normal distribution.

Results

A total of 56 patients between the ages of 18-52 were evaluated in all groups. 28 smokers (12 females and 16 males) made up the group of smokers, while 28 non-smokers made up the group of non-smokers (12 females and 16 males). The proportion of females in all group was 42.86%. Smokers and non-smokers had respective mean ages of 29.6 ± 9.40 years and 28.1 ± 7.63 years (Table 1).

Table 1. Distribution of smokers and non-smokers groups by age and gender

Group	Age (Mean±SD)	Sex (N, %)		
		Female	Male	Total
Smoker group	29.6±9.40	12 (21.43%)	16 (28.57%)	28(50%)
Non-smoker group	28.1±7.63	12 (21.43%)	16 (28.57%)	28(50%)
All groups	28.86± 8.52	24 (42.86%)	32 (57.14%)	56 (100%)

SD: standard deviation N: number of cases

For all metrics, including ROI1 (ICC=0.978), ROI2 (ICC=0.981), ROI3 (ICC=0.978), ROI4 (ICC=0.995), ROI5 (ICC=0.996), ROI6 (ICC=0.996), ROI7 (ICC=0.999), ROI8 (ICC=0.975), MCW (ICC=0.981), PMI (ICC=0.969), the intraclass correlation coefficient values showed excellent reliability.

FD values according to regions in smoker and non-smoker groups are shown in Table 2. The FD values assessed in ROI1, ROI2, ROI3, ROI5, ROI6, and ROI7 locations did not differ statistically significantly between the groups. However, ROI4 and ROI8 were found

statistically significantly higher in the non-smoker group ($p<0.05$) (Table 2).

No group differences in MCW or PMI were found to be statistically significant ($p>0.05$) (Table 3). PMI values were obtained as 0.31 in both groups. Smokers group had lower MCW values than non-smokers group (4.40 mm vs. 4.46 mm).

Between the genders, only FD in ROI 5 and PMI values were revealed to be significantly higher in female patients than in male patients ($p\leq 0.05$) (Table 4).

Table 2. Comparison of FD values according to regions in the smoker and non-smoker groups

ROI	Group	Mean+SD	p value	Test value
ROI1	S	1.51± 0.04	0.870	z=-0.164
	NS	1.51± 0.05		
ROI2	S	1.49±0.06	0.207	z=-1.262
	NS	1.48±0.05		
ROI3	S	1.50±0.05	0.057	z=-1.901
	NS	1.48±0.04		
ROI4	S	1.52±0.04	0.013*	z=-2.483
	NS	1.50±0.03		
ROI5	S	1.50±0.04	0.403	z=-0.836
	NS	1.49±0.04		
ROI6	S	1.49±0.04	0.533	z=-0.623
	NS	1.48±0.05		
ROI7	S	1.49±0.07	0.298	z=-1.041
	NS	1.47±0.07		
ROI8	S	1.52±0.03	0.008*	t=2.743
	NS	1.50±0.04		

ROI, region of interest: ROI1,8 condylar region, ROI2,7 gonial region
 ROI3,6 interdental area between the first molar and the second premolar, ROI4,5 adjacent to the mental foramen
 S: smoker, NS: non-smoker, *: significant at the 0.05 level, t: independent samples t-test, z: Mann-Whitney U test

Table 3. Comparison of radiomorphometric indices in the smoker and non-smoker groups

	Group	Mean±SD	p value	Test value
MCW	Smoker	4.40±0.67	0.718	z= -0.361
	Non-smoker	4.46±0.69		
PMI	Smoker	0.31±0.07	0.890	t=0.139
	Non-smoker	0.31±0.06		

MCW: Mandibular cortical width, PMI: Panoramic mandibular index, t: independent samples t-test, z: Mann-Whitney U test

Table 4. Comparison of FD values and radiomorphometric indices according to gender

	Female (n:24) Mean±SD	Male (n:36) Mean±SD	P value	Test value
ROI1	1.51± 0.03	1.50±0.05	0.351	t=0.940
ROI2	1.49±0.05	1.49±0.06	0.513	z=-0.654
ROI3	1.49±0.04	1.49±0.05	0.797	t=0.258
ROI4	1.51±0.04	1.50±0.04	0.790	t=0.267
ROI5	1.50±0.03	1.49±0.05	0.044*	t=2.067
ROI6	1.49±0.05	1.48±0.05	0.524	z=-0.638
ROI7	1.48±0.06	1.48±0.07	0.855	t=0.183
ROI8	1.51±0.04	1.51±0.03	0.585	z=-0.547
MCW	45.83±7.09	43.12±6.35	0.197	z=-1.291
PMI	0.35±0.06	0.29±0.05	0.000*	t=4.116

*: significant at the 0.05 level, n: number of cases, t: independent samples t-test, z: Mann-Whitney U test

Discussion

Osteoporosis is an age-related bone disease with a higher risk of fracture and is characterized by decreasing bone microstructure and density [25]. Risk factors for osteoporosis include a low body mass index, genetics, smoking, a deficiency in vitamin D, hormonal state, aging inadequate calcium intake, excessive caffeine and alcohol and consumption, a decline in physical activity, female gender [26, 27]. One of the most significant osteoporosis risk factors that can be changed is smoking [28]. The compounds in cigarette smoke cause changes in BMD due to their negative effects on osteoclastogenesis, bone angiogenesis, calcium-phosphate balance, sex and adrenal hormones. Due to their detrimental effects on calcium-phosphate balance osteoclastogenesis, adrenal and sex hormones, bone angiogenesis, the chemicals in cigarette smoke alter BMD [29].

Although dual-energy x-ray absorptiometry (DEXA), which measures bone mineral density (BMD), is a costly method, it is regarded as the

gold standard for osteoporosis screening [30]. Additionally, as the population ages, the costs related to this condition likely to rise [31]. The application of panoramic radiography in the early detection of low bone mass will provide those suffering from osteoporosis with the significant benefit of early treatment because it is a more frequent and affordable examination than DEXA and shows the complete maxilla and mandible on a single film [32].

By analyzing structural components such as bone tissue and complex shapes, FA [6], reveals the microarchitectural structure of trabecular bone, allowing the detection of osteoporotic changes in alveolar bone [33]. FA allows the computation of existing fractals with digitized images, but these images need to be preprocessed. After the image preprocessing process is completed, various algorithms are used to calculate the FD [34]. Since the box-counting algorithm is the most used technique in the literature for determining the fractal dimension [6, 35], it was also preferred

in our study. In the present work, we used radiomorphometric indices and FD analysis to assess the changes in the mandibular bone structure in smokers. In the field of dentistry, FA is used to assess the jaw's bone structure [3]. Fractal analysis is thought to be a metric that assesses the distinction between healthy and osteoporotic bone tissue [36]. According to a comprehensive review, investigations have been conducted using a variety of imaging modalities, with panoramic radiographs being the most common [3]. They argued that the use of panoramic radiography in FA is more advantageous because cone beam computed tomography (CBCT) shows lower image resolution and the radiation dose is higher in the examination of the trabecular bone [37]. In addition, the processing capacity of DPR allows qualitative and quantitative analysis of bone density and structure [2]. In the light of all this information, in this study, without using additional radiation, DPRs collected from patients who sought treatment at our facility for a variety of reasons were evaluated.

Existing studies in the medical literature on smoking and osteoporosis risk have reported that smoking increases the incidence of fractures by decreasing bone density [38]. Male smokers were shown to have lower forearm BMD than non-smokers [39]. In the study of Hijazi et al. [40], in which they evaluated the incidence of osteoporosis, it was shown that smoking and non-smokers had different incidences. In addition, smoking causes an increase in chronic oxidative stress in the body, which affects bone metabolism, causing the bone mineral density to decrease. By inhibiting vitamin D and calcium absorption, tobacco disrupts the calcium-phosphate balance necessary for bone matrix mineralization and affects bone mineral density [41].

The results of the investigations in the literature show that there is no unambiguous agreement on how alterations in bone microarchitecture and FD values are related. While some of the studies found an inverse relationship between osteoporosis and FD, others found that reduction in complexity in trabecular bone correlated with FD [42].

According to the findings of the present study, the FD of the trabecular bone of smokers was high. Similar to our study, in comparison to

the osteoporotic group, Yasar et al. [43], Mostafa et al. [44], Tosoni et al. [33] obtained lower FD values in the control groups. The premolar and condyle region's results for the fractal dimension were statistically significant. Alman et al. [45], and Cosgunarslan et al. [7], who evaluated the mineral density of the mandible, discovered a substantial variation in FD values in the premolar area, consistent with our study.

Only a few recent studies that examine the relation between bone mineral density and smoking can be found in the dental literature. Basavarajappa et al. [3] found that FD measurements taken only from the anterior of the mental foramen in digital panoramic radiography in male smokers were found to be lower in smoking tobacco (ST) and smokeless tobacco (SLT) users than in the control group. In addition, lower FD values were obtained in SLT users were compared to ST users. In Santolia et al. [46] studies where the FD values in three different areas changed between groups when they assessed patients with oral lesions linked to areca nut and tobacco use. Mean values were lowest in SLT users [46]. In the present research, the front of the mental foramen (ROI4) and condyle region (ROI8) showed a statistically significant difference, but the values were lower in the non-smoker group. This difference between the results of the studies is due to the methodological difference such as ROI selection and sizes, the superposition of the surrounding anatomical structures to the examined areas, the anatomical difference between individuals [47], and different demographic characteristics such as patient gender, number and age range, smoking frequency, and the type of cigarette used may be due to the difference. Compared to those who use smoking tobacco, since the dose of nicotine in smokeless tobacco users is relatively high, nicotine can cause more severe side effects on the bone [29]. We think that the use of smoke tobacco by the people included in the study in the smokers group may have caused the difference between the results.

Most studies published in the literature successfully assess osteoporotic abnormalities on the jawbones in dentistry using both FA and radiomorphometric indices [7, 10, 13-15]. The ability to assess osteoporotic abnormalities using a variety of radiomorphometric indices is one of the most important benefits of dental radiography [48]. The measurement that is

least affected by image distortions in panoramic radiographs is considered to be PMI [22]. However, the size and location of the mental foramen, its radiographic appearance, and its distance to the mandibular cortex differ between individuals [16]. Zihni Korkmaz et al. [8] reported that patients with lack of vitamin D had lower PMI values. Aytekin et al. [15] indicated that it is advantageous to employ in the earlier detection of osteoporotic abnormalities and reported lower PMI values on radiographic images of individuals with hyperthyroidism. Limeira et al. [49] found that patients with Type 1 Diabetes Mellitus (T1DM) that is not well controlled have lower PMI values than healthy people. On the other hand, some studies did not find a relationship between PMI measurements and BMD changes [21, 24].

According to the data, there wasn't any statistically significant variation in PMI among smokers [46]. There was no significant statistical difference in PMI values among non-smokers and smokers, which is in line with the findings of this study.

Some researchers did not discover a statistically significant distinction between the PMI values in the patient group and the healthy group; they found lower MCW values. They argued that MCW measurements would be helpful in the objective evaluation of osteoporotic changes, unlike PMI [7, 10]. They discovered that MCW values were lower in patients with T1 DM when compared to the control groups, even though there was no statistically significant difference in MCW index between patient groups with T1 and T2 DM [14]. In the study performed on patients using antidepressant, no MCW difference was observed [12]. The MCW values across smokers varied significantly, with ST users having the lowest values, but values were not less than 3 mm between groups [46]. No statistically significant difference existed between the groups in our investigation. However, while lower values (4.40 mm) were obtained in smokers, the results were not found to be less than 3 mm, which is consistent with the other study.

Some of the studies investigating FD values with various diseases did not detect a gender-related correlation [8]. However, Demiralp et al. [50], in their study of panoramic radiographs

of cancer patients taking bisphosphonates, observed a significant difference between genders in the FD values around the premolars and mental foramen. Cosgunarslan et al. [7] showed that in individuals using proton pump inhibitors, males had a higher number of affected parameters compared to females. In the current study, PMI and FD values of the region around the left mental foramen were found to be significantly higher in female patients. Due to the risk of sex-related characteristics and hormonal factors that may influence the results, studies with larger samples including different ages and sexes are needed to confirm these results.

Due to the retrospective nature of our current study, the inaccessibility of information such as smoking frequencies, vitamin D levels and supplementation, calcium use, and body mass index are the limitations of the study. Individual variances in this information could have influenced our current findings. Detailed studies should be focused on by considering other risk factors with larger samples.

In conclusion; it is important to determine its effect on the jaw bones due to tobaccos direct and indirect effects on bone mineral density. Our current study found changes in trabecular bone structure anterior to the mental foramen and in the condyle region. No difference was observed in the cortical bone structure. Differences were observed in some measurements between genders. Our study showed that fractal dimension in mandible trabecular bone and PMI are a parameter to be used in the evaluation of osteoporosis in smokers. Since dental radiographs are frequently used during dental control, it is of great importance to obtain the opportunity to screen for possible osteoporosis in dental clinics.

Conflict of interest: There was no conflict of interest among the authors in this study.

References

1. Consensus development conference: diagnosis, prophylaxis, and treatment of osteoporosis. *Am J Med* 1993;94:646-650. [https://doi.org/10.1016/0002-9343\(93\)90218-e](https://doi.org/10.1016/0002-9343(93)90218-e)
2. Mishra A, Chaturvedi P, Datta S, Sinukumar S, Joshi P, Garg A. Harmful effects of nicotine. *Indian J Med Paediatr Oncol* 2015;36:24-31. <https://doi.org/10.4103/0971-5851.151771>

3. Basavarajappa S, Konddajji Ramachandra V, Kumar S. Fractal dimension and lacunarity analysis of mandibular bone on digital panoramic radiographs of tobacco users. *J Dent Res Dent Clin Dent Prospects* 2021;15:140-146. <https://doi.org/10.34172/joddd.2021.024>
4. Abbas S, Baig S, Jamal Q, Danish H, Amber S. Osteoporosis in males and its association with tobacco; smokers and chewers. *European J Biotechnol Biosci* 2015;3:15-18.
5. Wong PK, Christie JJ, Wark JD. The effects of smoking on bone health. *Clin Sci* 2007;113:233-241. <https://doi.org/10.1042/CS20060173>
6. Franciotti R, Moharrami M, Quaranta A, et al. Use of fractal analysis in dental images for osteoporosis detection: a systematic review and meta-analysis. *Osteoporos Int* 2021;32:1041-1052. <https://doi.org/10.1007/s00198-021-05852-3>
7. Coşgunarslan A, Canger EM, Soydan Çabuk D. Proton pump inhibitors and mandibular bone quality: a preliminary study. *Dentomaxillofac Radiol* 2021;50:20200505. <https://doi.org/10.1259/dmfr.20200505>
8. Zihni Korkmaz M, Yemenoğlu H, Günaçar DN, Ustaoglu G, Ateş Yildirim E. The effects of vitamin D deficiency on mandibular bone structure: a retrospective radiological study. *Oral Radiol* 2023;39:69-74. <https://doi.org/10.1007/s11282-022-00602-5>
9. Ersu N, Akyol R, Etöz M. Fractal properties and radiomorphometric indices of the trabecular structure of the mandible in patients using systemic glucocorticoids. *Oral Radiol* 2022;38:252-260. <https://doi.org/10.1007/s11282-021-00552-4>
10. Aktuna Belgin C, Serindere G. Fractal and radiomorphometric analysis of mandibular bone changes in patients undergoing intravenous corticosteroid therapy. *Oral Surg Oral Med Oral Pathol Oral Radiol* 2022;130:110-115. <https://doi.org/10.1016/j.oooo.2019.12.009>
11. Gulec M, Tassoker M, Ozcan S, Orhan K. Evaluation of the mandibular trabecular bone in patients with bruxism using fractal analysis. *Oral Radiol* 2021;37:36-45. <https://doi.org/10.1007/s11282-020-00422-5>
12. Coşgunarslan A, Aşantoğrul F, Soydan Çabuk D, Canger EM. The effect of selective serotonin reuptake inhibitors on the human mandible. *Oral Radiol* 2021;37:20-28. <https://doi.org/10.1007/s11282-019-00419-9>
13. Gupta B, Acharya A, Singh S, et al. Evaluation of jawbone morphology and bone density indices in panoramic radiographs of selective serotonin reuptake inhibitor users: a preliminary study. *Dentomaxillofac Radiol* 2019;48:20170360. <https://doi.org/10.1259/dmfr.20170360>
14. Kurşun Çakmak E, Bayrak S. Comparison of fractal dimension analysis and panoramic-based radiomorphometric indices in the assessment of mandibular bone changes in patients with type 1 and type 2 diabetes mellitus. *Oral Surg Oral Med Oral Pathol Oral Radiol* 2018;126:184-191. <https://doi.org/10.1016/j.oooo.2018.04.010>
15. Aytekin Z, Yılmaz SG. Evaluation of osseous changes in dental panoramic radiography using radiomorphometric indices in patients with hyperthyroidism. *Oral Surg Oral Med Oral Pathol Oral Radiol* 2022;133:492-499. <https://doi.org/10.1016/j.oooo.2021.10.011>
16. Neves FS, Barros AS, Cerqueira GA, et al. Assessment of fractal dimension and panoramic radiomorphometric indices in women with celiac disease. *Oral Radiol* 2020;36:141-7. <https://doi.org/10.1007/s11282-019-00388-z>
17. Arsan B, Köse TE, Çene E, Özcan İ. Assessment of the trabecular structure of mandibular condyles in patients with temporomandibular disorders using fractal analysis. *Oral Surg Oral Med Oral Pathol Oral Radiol* 2017;123:382-391. <https://doi.org/10.1016/j.oooo.2016.11.005>
18. Eninanç İ, Yalçın Yeler D, Çınar Z. Investigation of mandibular fractal dimension on digital panoramic radiographs in bruxist individuals. *Oral Surg Oral Med Oral Pathol Oral Radiol* 2021;131:600-609. <https://doi.org/10.1016/j.oooo.2021.01.017>
19. Suer BT, Yaman Z, Buyuksarac B. Correlation of fractal dimension values with implant insertion torque and resonance frequency values at implant recipient sites. *Int J Oral Maxillofac Implants* 2016;31:55-62. <https://doi.org/10.11607/jomi.3965>
20. Kış HC, Güteryüz Gürbulak A. Evaluation of the peri-implant bone trabecular microstructure changes in short implants with fractal analysis. *Int J Implant Dent* 2020;6:13(e1-8). <https://doi.org/10.1186/s40729-020-00209-7>
21. Ledgerton D, Horner K, Devlin H, Worthington H. Radiomorphometric indices of the mandible in a British female population. *Dentomaxillofac Radiol* 1999;28:173-181. <https://doi.org/10.1038/sj/dmfr/4600435>
22. Benson BW, Prihoda TJ, Glass BJ. Variations in adult cortical bone mass as measured by a panoramic mandibular index. *Oral Surg Oral Med Oral Pathol* 1991;71:349-356. [https://doi.org/10.1016/0030-4220\(91\)90314-3](https://doi.org/10.1016/0030-4220(91)90314-3)
23. White SC, Rudolph DJ. Alterations of the trabecular pattern of the jaws in patients with osteoporosis. *Oral Surg Oral Med Oral Pathol Oral Radiol Endod* 1999;88:628-635. [https://doi.org/10.1016/s1079-2104\(99\)70097-1](https://doi.org/10.1016/s1079-2104(99)70097-1)

24. Ledgerton D, Horner K, Devlin H, Worthington H. Panoramic mandibular index as a radiomorphometric tool: an assessment of precision. *Dentomaxillofac Radiol* 1997;26:95-100. <https://doi.org/10.1038/sj.dmfr.4600215>
25. Yu B, Wang CY. Osteoporosis and periodontal diseases - An update on their association and mechanistic links. *Periodontol* 2000 2022;89:99-113. <https://doi.org/10.1111/prd.12422>
26. Pouresmaeili F, Kamalidehghan B, Kamarehei M, Goh YM. A comprehensive overview on osteoporosis and its risk factors. *Ther Clin Risk Manag* 2018;14:2029-2049. <https://doi.org/10.2147/TCRM.S138000>
27. Høiberg MP, Rubin KH, Hermann AP, Brixen K, Abrahamsen B. Diagnostic devices for osteoporosis in the general population: a systematic review. *Bone* 2016;92:58-69. <https://doi.org/10.1016/j.bone.2016.08.011>
28. Ratajczak AE, Szymczak Tomczak A, Rychter AM, Zawada A, Dobrowolska A, Krela Kaźmierczak I. Impact of cigarette smoking on the risk of osteoporosis in inflammatory bowel diseases. *J Clin Med* 2021;10:1515. <https://doi.org/10.3390/jcm10071515>
29. Al Bashairah AM, Haddad LG, Weaver M, Chengguo X, Kelly DL, Yoon S. The effect of tobacco smoking on bone mass: an overview of pathophysiologic mechanisms. *J Osteoporos* 2018;1206235. <https://doi.org/10.1155/2018/1206235>
30. Kavitha MS, An SY, An CH, et al. Texture analysis of mandibular cortical bone on digital dental panoramic radiographs for the diagnosis of osteoporosis in Korean women. *Oral Surg Oral Med Oral Pathol Oral Radiol* 2015;119:346-356. <https://doi.org/10.1016/j.oooo.2014.11.009>
31. Kanis JA, Johnell O, Oden A, Jonsson B, De Laet C, Dawson A. Risk of hip fracture according to the World Health Organization criteria for osteopenia and osteoporosis. *Bone* 2000;27:585- 590. [https://doi.org/10.1016/s8756-3282\(00\)00381-1](https://doi.org/10.1016/s8756-3282(00)00381-1)
32. Oliveira ML, Pedrosa EF, Cruz AD, Haiter Neto F, Paula FJ, Watanabe PC. Relationship between bone mineral density and trabecular bone pattern in postmenopausal osteoporotic Brazilian women. *Clin Oral Investig* 2013;17:1847-1853. <https://doi.org/10.1007/s00784-012-0882-2>
33. Tosoni GM, Lurie AG, Cowan AE, Burtleson JA. Pixel intensity and fractal analyses: detecting osteoporosis in perimenopausal and postmenopausal women by using digital panoramic images. *Oral Surg Oral Med Oral Pathol Oral Radiol Endod* 2006;102:235-241. <https://doi.org/10.1016/j.tripleo.2005.08.020>
34. Kato CN, Barra SG, Tavares NP, et al. Use of fractal analysis in dental images: a systematic review. *Dentomaxillofac Radiol* 2020;49:20180457. <https://doi.org/10.1259/dmfr.20180457>
35. Leite A, Figueiredo P, Caracas H, et al. Systematic review with hierarchical clustering analysis for the fractal dimension in assessment of skeletal bone mineral density using dental radiographs. *Oral Radiol* 2015;31:1-13. <https://doi.org/10.1007/s11282-014-0188-y>
36. Law AN, Bollen AM, Chen SK. Detecting osteoporosis using dental radiographs: a comparison of four methods. *J Am Dent Assoc* 1996;127:1734-1742. <https://doi.org/10.14219/jada.archive.1996.0134>
37. Magat G, Ozcan Sener S. Evaluation of trabecular pattern of mandible using fractal dimension, bone area fraction, and gray scale value: comparison of cone-beam computed tomography and panoramic radiography. *Oral Radiol* 2019;35:35-42. <https://doi.org/10.1007/s11282-018-0316-1>
38. Iki M. Osteoporosis and smoking. *Clin Calcium* 2005;15:156-158.
39. Kopiczko A, Gryko K, Łopuszańska Dawid M. Bone mineral density, hand grip strength, smoking status and physical activity in Polish young men. *Homo* 2018;69:209-216. <https://doi.org/10.1016/j.jchb.2018.08.003>
40. Hijazi N, Alourfi Z. Prevalence and factors associated with low bone mass and osteoporosis in syrian postmenopausal women. *Mathews J Case Rep* 2019;4:58(e1-7). <https://doi.org/10.30654/MJCR.10058>
41. Cusano NE. Skeletal effects of smoking. *Curr Osteoporos Rep* 2015;13:302-309. <https://doi.org/10.1007/s11914-015-0278-8>
42. Updike SX, Nowzari H. Fractal analysis of dental radiographs to detect periodontitis-induced trabecular changes. *J Periodontal Res* 2008;43:658-664. <https://doi.org/10.1111/j.1600-0765.2007.01056.x>
43. Yaşar F, Akgünlü F. The differences in panoramic mandibular indices and fractal dimension between patients with and without spinal osteoporosis. *Dentomaxillofac Radiol* 2006;35:1-9. <https://doi.org/10.1259/dmfr/97652136>
44. Mostafa RA, Arnout EA, Abo el-Fotouh MM. Feasibility of cone beam computed tomography radiomorphometric analysis and fractal dimension in assessment of postmenopausal osteoporosis in correlation with dual X-ray absorptiometry. *Dentomaxillofac Radiol* 2016;45:20160212. <https://doi.org/10.1259/dmfr.20160212>
45. Alman AC, Johnson LR, Calverley DC, Grunwald GK, Lezotte DC, Hokanson JE. Diagnostic capabilities of fractal dimension and mandibular cortical width to identify men and women with decreased bone mineral density. *Osteoporos Int* 2012;23:1631-1636. <https://doi.org/10.1007/s00198-011-1678-y>

46. Santolia DD, Dahiya DS, Sharma DS, et al. Fractal Dimension and Radiomorphometric analysis of Orthopantomographs in patients with tobacco and areca nut associated oral mucosal lesions: a pilot in-vivo study in a North Indian cohort. *Oral Surg Oral Med Oral Pathol Oral Radiol* 2022;134:627-638. <https://doi.org/10.1016/j.oooo.2022.06.003>
47. Chappard C, Brunet Imbault B, Lemineur G, et al. Anisotropy changes in post-menopausal osteoporosis: characterization by a new index applied to trabecular bone radiographic images. *Osteoporos Int* 2005;16:1193-1202. <https://doi.org/10.1007/s00198-004-1829-5>
48. Savic Pavicin I, Dumancic J, Jukic T, Badel T, Badanjak A. Digital orthopantomograms in osteoporosis detection: mandibular density and mandibular radiographic indices as skeletal BMD predictors. *Dentomaxillofac Radiol* 2014;43:20130366. <https://doi.org/10.1259/dmfr.20130366>
49. Limeira FIR, Rebouças PRM, Diniz DN, Melo DP, Bento PM. Decrease in mandibular cortical in patients with type 1 diabetes mellitus combined with poor glycemetic control. *Braz Dent J* 2017;28:552-558. <https://doi.org/10.1590/0103-6440201701523>
50. Demiralp KÖ, Kurşun Çakmak EŞ, Bayrak S, Akbulut N, Atakan C, Orhan K. Trabecular structure designation using fractal analysis technique on panoramic radiographs of patients with bisphosphonate intake: a preliminary study. *Oral Radiol* 2019;35:23-28. <https://doi.org/10.1007/s11282-018-0321-4>

Ethics committee approval: This study was approved by the Ethics Committee of Ankara Yildirim Beyazıt University (number: 2022/640, date: 07.02.2022).

Authors' contributions to the article

B.C: Concept, Design, Definition of content, Literature search, Radiological studies (Fractal Analysis), Data acquisition, Data analysis, Preparation of Manuscript and Proofreading. Z.B.A: Design, Definition of content, Literature search, Radiological studies (Radiomorphometric indices), Data acquisition, Data analysis, Statistical Analysis, Preparation of Manuscript.