

## Effect of Dose-Related Astaxanthin on Rats with Cerebral Ischemia-Reperfusion

### Astaksantinin Serebral İskemi-Reperfüzyonlu Sıçanlarda Doza Bağlı Etkisi

Bengi Yegin<sup>1</sup>, Semih Oz<sup>2</sup>, Dilek Burukoglu Donmez<sup>3</sup>, Hilmi Ozden<sup>4</sup>, Cengiz Ustuner<sup>5</sup>,  
Sibel Canbaz Kabay<sup>6</sup>, Ferruh Yucel<sup>4</sup>

<sup>1</sup>Department of Anatomy, Faculty of Medicine, Yuksek Ihtisas University, Ankara, Turkey

<sup>2</sup>Department of Vocational School of Health Services, Eskisehir Osmangazi University, Eskisehir, Turkey

<sup>3</sup>Department of Histology and Embryology, Faculty of Medicine, Eskisehir Osmangazi University, Eskisehir, Turkey

<sup>4</sup>Department of Anatomy, Faculty of Medicine, Eskisehir Osmangazi University, Eskisehir, Turkey

<sup>5</sup>Department of Medical Biology, Faculty of Medicine, Eskisehir Osmangazi University, Eskisehir, Turkey

<sup>6</sup>Department of Neurology, Faculty of Medicine, Kütahya Health Sciences University, Kutahya, Turkey

#### ABSTRACT

**Introduction:** The prevalence of cerebral ischemia-related diseases, which mostly affect the brain, has become pervasive and is associated with significant societal and economic challenges. The deficiency of the organism's antioxidant defense system results in an elevation of free radicals, which in turn contributes to the development of a range of illnesses and aging processes, with a particular emphasis on cancer. The objective of our research was to examine the potential protective impact of astaxanthin (AST) on the antioxidant system inside the brain.

**Material and Method:** Within the experimental framework, a total of 32 male rats were utilized, with each group consisting of 8 rats separated into 4 subgroups. Dimethyl sulfoxide and AST were delivered intraperitoneally to the rats 30 minutes before to the surgery. A 15-minute period of ischemia was conducted. After a period of 24 hours of reperfusion, the rats underwent decapitation. Malondialdehyde (MDA), superoxide dismutase (SOD), catalase (CAT) levels were analyzed and brain sections were examined.

**Results:** A significant decrease in the levels of SOD and CAT was observed in the sham group, while a significant increase was observed in the group treated with AST. This indicates that the antioxidant defense system is insufficient against the free radicals that increase after ischemia, while AST has a significant protective effect on the antioxidant system. The significant increase in MDA levels in the sham group suggests that oxidative damage occurs in the brain. In the groups administered AST, we observed a significant decrease. This indicates to us that AST has an extensive protective effect on the brain at high doses.

In the sham group, significant damage and a high number of necrotic neurons were observed in the cerebral cortex. Neurons with less damage were observed in the groups treated with AST. The histological data suggest that AST may have a limited neuroprotective effect.

**Conclusion:** The results show that AST has some preventive effect in reducing oxidative damage and against brain damage. In order to increase the objectivity and clarity of the histological evaluations, it will be useful to perform quantitative analyzes and evaluations and to categorize the detected changes.

**Keywords:** Ischemia-reperfusion, common carotid artery, free radicals, antioxidants, astaxanthin, tissue damage.

#### ÖZET

**Giriş:** İskemiye karşı en hassas olan beyinde iskemiden kaynaklanan hastalıklar yaygınlaşarak sosyal ve ekonomik sorunlara yol açmaktadır. Organizmanın oluşturduğu antioksidan savunma sisteminin yetersizliği sonucu artan serbest radikaller başta kanser olmak üzere çeşitli hastalıkların ve yaşlanma süreçlerinin gelişmesine katkıda bulunur. Çalışmamızda güçlü bir antioksidan olan astaksantin (AST) antioksidan sistem ile beyin üzerindeki koruyucu etkisinin araştırılması amaçlandı.

**Materyal ve Metot:** Deneyde toplam 32 adet erkek sıçan kullanıldı ve sıçanlar her grupta sekiz adet olmak üzere dört gruba ayrıldı. Sıçanlara ameliyattan 30 dakika önce intraperitoneal olarak AST verildi. Sonrasında 15 dakika süreyle iskemi ardından da 24 saat reperfüzyon uygulandı. Malondialdehit (MDA), süperoksit dismutaz (SOD), katalaz (CAT) düzeyleri analiz edildi ve beyin kesitleri incelendi.

**Bulgular:** Sham grubunda SOD ve CAT düzeylerinde anlamlı derecede azalma, AST ile tedavi edilen grupta ise anlamlı bir artış gözlemlenmiştir. Bu da iskemi sonrası artan serbest radikaller karşısında antioksidan savunma sisteminin yetersiz olduğunu, ancak AST'nin antioksidan sistem üzerinde önemli bir koruyucu etkiye sahip olduğunu göstermektedir. Sham grubunda görülen MDA düzeylerindeki anlamlı artış beyinde oksidatif hasarın oluştuğunu göstermektedir. Astaksantin verilen gruplarda anlamlı bir düzeyde azalma gözlemledik. Bu da bize yüksek dozda verilen AST'nin beyin üzerinde tam bir koruyucu etkiye sahip olduğunu göstermektedir.

Sham grubunda, serebral kortekste önemli hasar ve yüksek sayıda nekrotik nöron gözlemlenmiştir. Astaksantin verilen gruplarda hasar seviyeleri azalmış nöronlar gözlemlenmiştir. Histolojik veriler, AST'nin sınırlı derecede nörolojik koruma sağlayabildiğini göstermektedir.

**Sonuç:** Çıkan sonuçlar AST'nin oksidatif hasarı azaltmada ve beyin hasarına karşı bir dereceye kadar önleyici etkinlik sergilediğini göstermektedir. Histolojik değerlendirmelerin objektifliğini ve netliğini artırmak için niceliksel analizler ve değerlendirmeler yapmak ve tespit edilen değişiklikleri kategorize etmek faydalı olacaktır.

**Anahtar Sözcükler:** iskemi-reperfüzyon, arteria carotis communis, serbest radikaller, antioksidanlar, astaksantin, serebral iskemi modelleri, doku hasarı

**Cite this article as:** Yegin B, Oz S, Burukoglu Donmez D, Ozden H, Ustuner C, Canbaz Kabay S, Yucel F. Effect of Dose-Related Astaxanthin on Rats with Cerebral Ischemia-Reperfusion. YIU Sağlık Bil Derg 2023;4:42-49

## Introduction

Cerebral ischemic injuries, which have a high morbidity, disability, and mortality worldwide, represent a major psychological burden and economic pressure for patients and society (1).

Ischemia is defined as the inability of tissues to provide oxygen and other metabolic products and to remove the remaining products, especially oxygen, as a result of weakening or complete interruption of blood flow in a given tissue (2). Reperfusion is the restoration of blood circulation in this ischemic tissue (3). Damage to ischemic tissue in many organs such as lung, kidney, liver, heart, brain, and intestine after reperfusion has been investigated in studies (4).

The severity of tissue damage resulting from ischemia is influenced by several parameters, including the occluded artery's size, the duration of the blockage, and the tissue's properties (5). Brains are very delicate and susceptible to interruptions in blood supply. Cerebral ischemia is a medical emergency that results from the temporary interruption of blood supply to the brain, leading to irreparable neuronal damage in various brain regions (6). Transient symptoms may occur if sufficient blood supply is promptly restored. Nevertheless, in the event of a significant delay in the restoration of circulation, it is possible for irreversible brain damage to occur. While the preservation of brain tissue during reperfusion is crucial, it is imperative to acknowledge that reperfusion can also result in injury (1,7). Ischemia-reperfusion injury is a complex sequence of events leading to cell and tissue damage (5). Oxidative stress and inflammation play a critical role in the process of ischemia and reperfusion injury in the brain. Oxidative stress is an important mediator of neuronal apoptosis in the central nervous system (8,9). Blood flow to the brain decreases, leading to ischemia and the breakdown of toxic metabolites such as oxidative stress mediators. The restoration of blood flow, known as reperfusion, has the potential to elevate oxygen levels and induce the creation of reactive oxygen species. This phenomenon has been linked to detrimental effects on the cellular membrane, proteins, and DNA within neurons. The excessive generation of reactive oxygen species (ROS) results in oxidative harm, included lipid peroxidation, protein oxidation, and DNA damage, potentially culminating in cellular demise (10,11,12).

Animal models of brain ischemia have been widely used to study the effects of potentially neuroprotective agents. Strategies based on antioxidant supplementation have been reported to have a beneficial effect on neuronal damage in experimental models of cerebral ischemia-reperfusion. Antioxidant agents can combat oxidative stress by eliminating free radicals or consuming substances that can produce free radicals. Many antioxidants have been reported to protect the brain from ischemia-reperfusion injury (13).

Astaxanthin (AST), a red and orange carotenoid pigment belonging to the class of xanthophylls, is a biological antioxidant that occurs naturally in a variety of aquatic organisms (14,15). It was first isolated from lobsters, and because of its remarkable antioxidant activity, astaxanthin was approved as a dietary supplement (16). Astaxanthin is one of the xanthophyll carotenoids found mainly in microalgae, fungi, complex plants, seafood, flamingos, and quail (17). Although AST is able to exhibit higher antioxidant activity than beta-carotene and vitamin E (18). Astaxanthin has a broad spectrum of biological activities, such as antioxidant, anti-inflammatory, anti-cancer, anti-apoptotic, and cardioprotective effects (19,20). It can also easily cross the blood-brain barrier and protect the brain from acute and chronic damage caused by neurodegenerative diseases (21). Studies in animal models have shown that AST administration in the early stages of ischemia-reperfusion significantly reduces cell death in the hippocampus (22). Astaxanthin has been shown to protect against Alzheimer's disease (23). Astaxanthin has been shown to protect against another common neurodegenerative disease, Parkinson's disease, through multiple mechanisms (24).

The aim of this study is to investigate whether AST has a dose-dependent protective effect on the antioxidant system and brain in the cerebral ischemia-reperfusion model.

## Materials and Methods

Before starting the study, "ethically appropriate" approval was obtained from the local animal experimentation ethics committee of Eskisehir Osmangazi University dated 16/08/2016 with registration number 544/2016. The male rats to be used in the study were obtained from Eskisehir Osmangazi University Medical and Surgical Experimental Research Centre.

### Animals

Thirty-two adult male Wistar albino rats weighing between 180-200 g were used. Rats were obtained from the department's animal shelter and maintained under standard laboratory conditions such as a temperature of  $21 \pm 3^\circ\text{C}$ , 60-70% relative humidity, and a 12/12-hour light and dark cycle. The rats were acclimatized seven days before the experimental study. During the experimental period, the rats had free access to tap water and commercial pellet food.

### Experimental Design

Rats were randomly divided into four groups (eight rats in each group): Control, Sham, ischemia-reperfusion injury treated with AST at 25 mg/kg (AST25), and ischemia-reperfusion injury treated with AST at 75 mg/kg (AST75). Astaxanthin ( $\geq 97\%$ , Haematococcus pluvialis, SML0982 SIGMA) was dissolved in dimethyl sulfoxide (DMSO) and administered intraperitoneally at the appropriate dosage 30 minutes before surgery. With careful surgery and administration, no rat in any group died.

The Control group was administered 1 ml/kg DMSO intraperitoneally 30 minutes before the start of the surgical procedure. To study the effect of the surgical procedure in rats and compare it with the other groups, only the dissection of the left carotid artery was performed in the control group. After 15 minutes, the neck structures were returned to their original position, and the skin was closed.

The Sham group were administered 1 ml/kg DMSO intraperitoneally as an infusion 30 minutes before the start of the surgical procedure. The neck of the rats was dissected, the left carotid artery was exposed, and ischemia was applied for 15 minutes. After this time, the clamp was removed, the structures in the neck were returned to their original position, and the skin was closed.

Twenty-five mg/kg and 75 mg/kg AST were administered intraperitoneally to the rats in the low-dose group (AST25) and the high-dose group (AST75), respectively, 30 minutes before the start of the surgical procedure. The neck of the rats was dissected to expose the left carotid artery, and ischemia was applied for 15 minutes. At the end of this time, the clamp was removed, the structures in the neck were returned to their original position, and the skin was closed. Rats in the whole group were kept in reperfusion for 24 hours after the surgical procedures.

**Biochemical Analysis**

After 24 hours had elapsed, the rats were anesthetized intraperitoneally. Rats were placed on the operating table and restrained in the supine position, and their retraction and blink reflexes were checked. After anesthesia, the rats were perfused via intracardiac access. Blood was collected from the apex of the heart into tubes.

The collected blood was stored at +4°C for 10 minutes and centrifuged at 10,000 rpm. The supernatant obtained by centrifugation was separated for biochemical measurements and stored at -85°C until measurement.

The enzyme Superoxide dismutase (SOD) was studied according to the method of Sun et al (25), the determination of malondialdehyde (MDA) according to the Esterbauer method (lipid peroxidation measurement method) (26), and the determination of catalase (CAT) according to the Aebi method (27). Afterwards, the rats were killed by dislocation of the cervical spine and the brain tissue was removed for further examination.

**Histological Processes of Tissues**

Brain tissue was postfixed in 4% paraformaldehyde solution for 12 hours and rinsed in water. After dehydration in gradient alcohol and kerosene embedding, specimens were cut into 5-mm-thick slices and stained with hematoxylin–eosin. Brain sections were examined by light microscopy, after staining with hematoxylin–eosin (HE).

**Statistical Analysis**

IBM Statistical Package for Social Sciences (SPSS) program v.21 was used for the statistical analysis of the obtained results. Descriptive data were expressed as mean ± standard deviation. When the data were normally distributed, the one-way method ANOVA (post hoc: Tukey) was used as the result of comparisons between groups. The Kruskal-Wallis H test was used to evaluate multiple groups that did not have a normal distribution. The compatibility of the data with the assumption of normal distribution was evaluated using the Kolmogorov-Smirnov test. A value of p <0.05 was accepted as a criterion for statistical significance.

**Results**

**Biochemical Results**

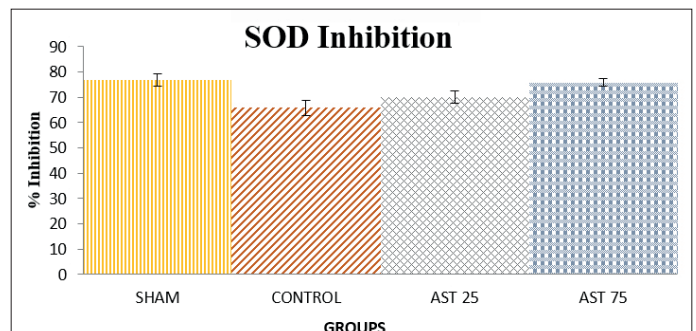
**Superoxide dismutase values**

The numerical data for the blood values SOD (% inhibition) (mean±standard deviation) are given in Table 1, and the graph for the same values is shown in Figure 1.

In the statistical comparison of the groups, it was found that the value of the Sham group, in which we applied ischemia but did not administer any substance, was the lowest. This indicates that the antioxidant defense system is inadequate against free radicals, which increase with ischemia. The significant increase in the values in the AST25 group shows that the substance we administered has a significant protective effect on the antioxidant system. In the AST75 group, the protective effect increased and approached the values of the control group. However, the increase in the dose of the administered substance did not increase to the same extent as the protective effect of the AST25 group. This indicates that the protective effect of astaxanthin continues to increase with increasing dose, but its rate gradually decreases.

**Table 1.** Distribution of SOD levels of the groups

Group Number	Groups	n	SOD (% inhibition) mean±standard deviation	F	p	Multiple Comparison			
						1	2	3	4
1	Sham	8	76,725±2,439				***	***	ns
2	Control	8	65,883±3,062			***		**	***
3	AST25	8	70,190±2,470	34,603	0,000	***	**		**
4	AST75	8	75,735±1,506			ns	***	**	



**Figure 1.** Distribution of SOD levels of the groups

**Catalase values**

The numerical data for the blood values CAT (mmol/min/mg protein) are given in Table 2, and the graph for the same values is shown in Figure 2.

It was found that the values were generally consistent with those of SOD. The lowest value of the sham group indicates that the antioxidant defense system against free radicals, which increase in ischemia, is inadequate. It was observed that the values of the AST25 group increased significantly and the administered substance had a significant protective effect on the antioxidant system, while in the AST75 group, the protective effect increased further and approached the values of the control group.

Group Number	Groups	n	CAT (mmoles/min/mg protein) mean±standard deviation	F	p	Multiple Comparison			
						1	2	3	4
1	Sham	8	18,3813±1,62			***	**	ns	
2	Control	8	14,3263±0,497			***		***	***
3	AST25	8	16,6713±0,216	29,191	0,000	**	***		*
4	AST75	8	17,8163±0,535			ns	***	*	

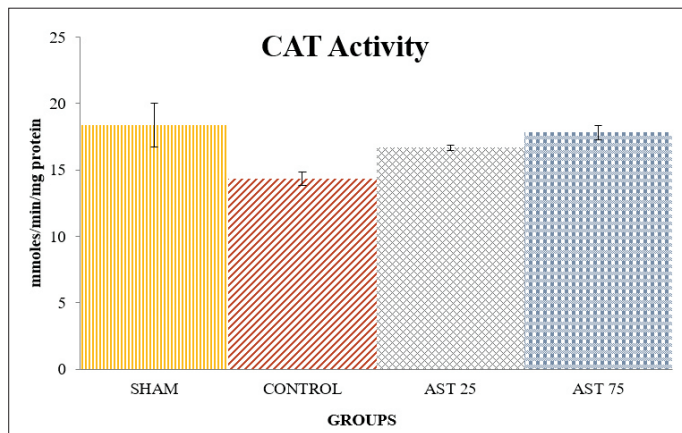


Figure 2. Distribution of CAT levels of the groups

**Malondialdehyde values**

The numerical data for the blood values MDA (nmol/ml) (mean±standard deviation) are given in Table 3, and the graph of MDA levels in the blood is shown in Figure 3.

In the statistical comparison between the Sham group and the other groups, it was found that the MDA values of the Sham group were significantly higher. This indicates that brain tissue damage occurs after ischemia. The rapid decrease of the values in the AST25 group and the approach to the values of the control group indicate that the administered substance has a significant protective effect on the brain. The fact that the values of the AST75 group fell below the values of the control group shows that astaxanthin has a full (100%) protective effect on the brain.

Group Number	Groups	n	MDA (nmol/ml) mean±standard deviation	F	p	Multiple Comparison			
						1	2	3	4
1	Sham	8	1,7288±0,01246				***	ns	ns
2	Control	8	1,8588±0,02167			***		***	***
3	AST25	8	1,7475±0,02915	78,237	0,000	ns	***		ns
4	AST75	8	1,7275±0,01165			ns	***	ns	

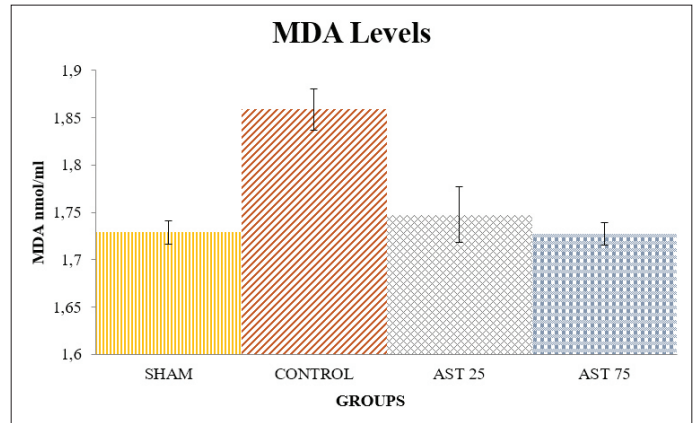


Figure 3. Malondialdehyde values in blood

**Histological Results**

Brain sections stained with hematoxylin-eosin were examined under a light microscope.

Brain samples from the control group showed that the brain had a normal histological structure. Normal-looking neurons and glial cells were also observed in the cortical area (Figure 4). Brain samples from the Sham group revealed severe damage and many necrotic neurons in the cerebral cortex (Figure 5).

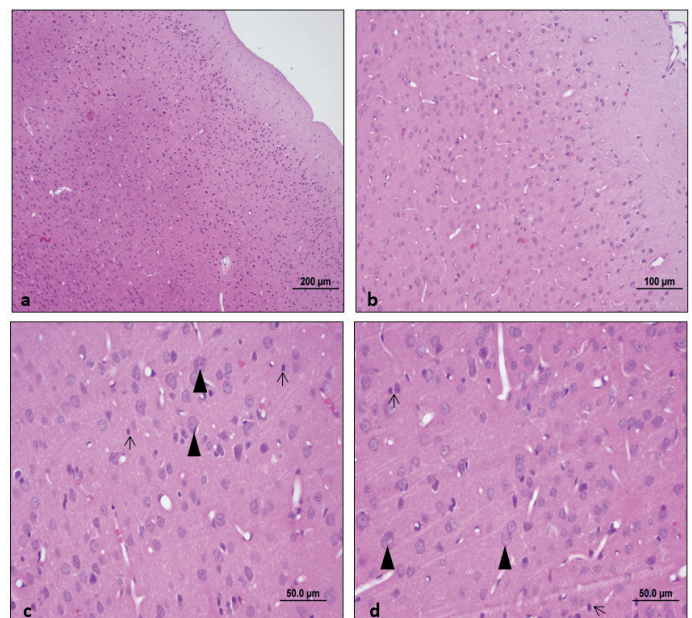
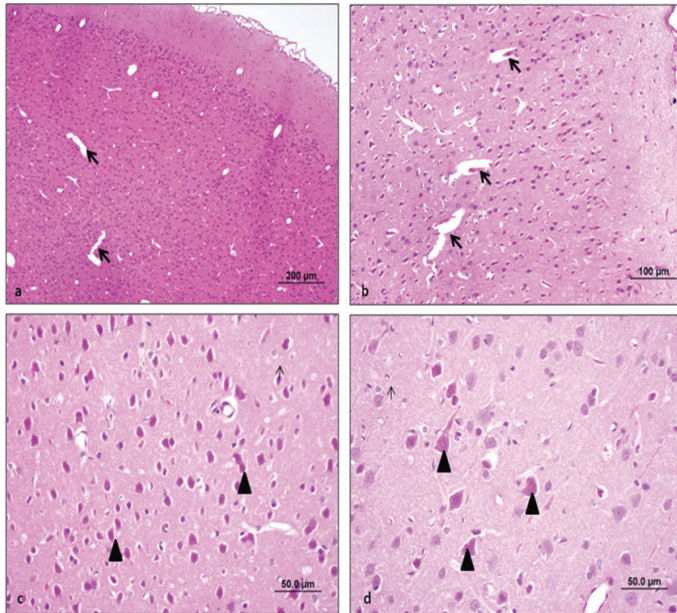
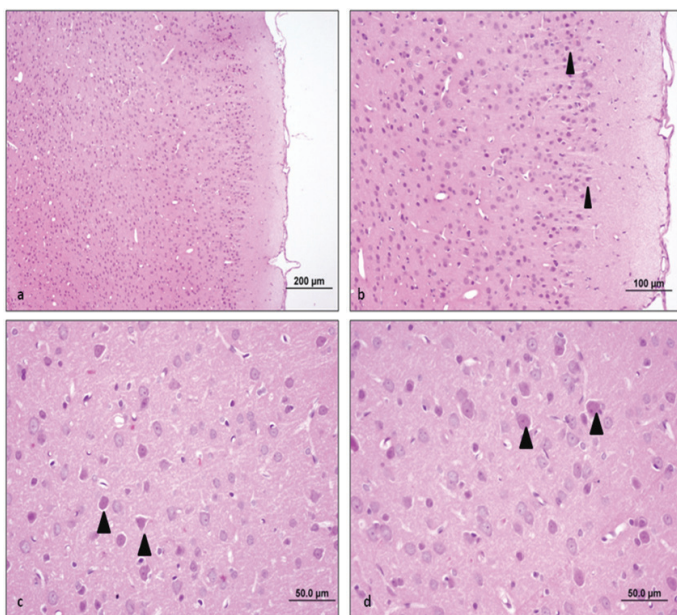


Figure 4. Brain tissue samples from the control group. Normal-looking neurons (▶) and glial cells (→) are observed in the cortical area. (a-d) (scale bar: 200µm, scale bar: 100µm, scale bar: 50.0µm, HE).

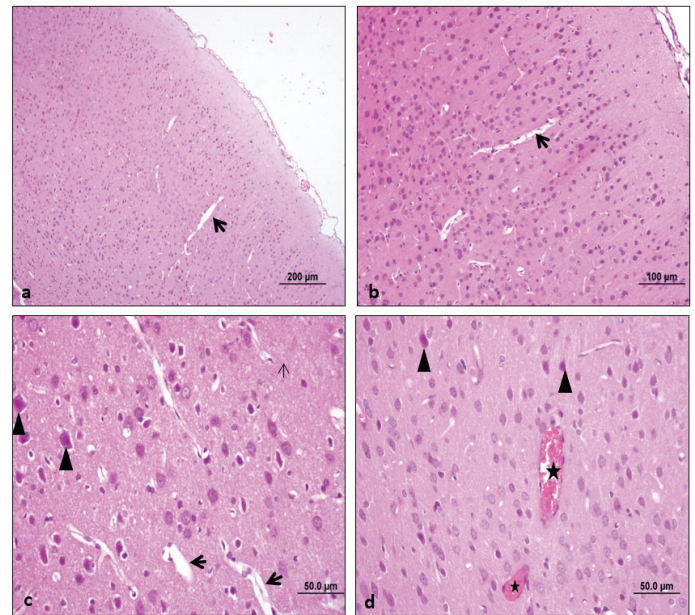
Brain samples from the AST25 group revealed less damage in the cerebral cortex compared with the Sham group. A decrease in the number of necrotic cells was observed. A small number of necrotic neurons were observed together with normal-looking neurons (Figure 6). Brain samples from the AST75 group revealed partial damage in the cortical area with less damage in the cerebral cortex than in the Sham group. Histological evaluation revealed a small number of necrotic neurons in addition to normal-looking neuronal structures. In addition, vascular congestion was observed (Figure 7).



**Figure 5.** Brain tissue samples from the Sham group. Intense damage (→) and many necrotic neurons (▶) are observed in the cortical area. (a-d) (Scale bar: 200µm, scale bar: 100µm, scale bar: 50.0µm, HE).



**Figure 6.** Brain tissue samples from the AST25 group. Reduced damage in the cortical area draws attention. A small number of necrotic neurons (▶) are seen with normal-looking neurons. (a-d) (Scale bar: 200µm, scale bar: 100µm, scale bar: 50.0µm, HE).



**Figure 7.** Brain tissue samples from the AST75 group. Along with partial damage (→) in the cortical area, besides the normal-looking neuron structures, a small number of necrotic neurons (▶) draw attention. In addition, vascular congestion (\*) is observed. (scale bar: 200µm, scale bar: 100µm, scale bar: 50.0µm, HE).

## Discussion

Cerebrovascular disease, especially cerebral ischemia is an important cause of morbidity and mortality in both childhood and adulthood in the context of a wide spectrum of neurologic diseases. Diseases occurring after ischemia are still an important health problem today. Cerebral ischemia is a complex process characterized by the initial deprivation of oxygen and energy supplies, including Adenosine triphosphate (ATP) and glucose, resulting from a decrease or full cessation of blood flow to the brain. This condition can arise from several underlying causes and ultimately leads to the destruction of neurons (28).

Recent studies performed under clinical observation and with modern imaging techniques show that reversible or irreversible damage varies according to the duration of cerebral ischemia. The brain is widely recognized for its elevated rate of oxygen metabolism and absence of a tissue oxygen system. Consequently, any disruption in the delivery of oxygen to the brain promptly results in cellular malfunction and swiftly progresses to the demise of neuronal cells (29).

Ischemic brain injury leads to severe and permanent disability in many cases, and the degree of damage reflects not only the severity of ischemia in individual brain regions. Much research remains to be done on the particular susceptibility and tolerance to ischemia in each brain region (30).

In order to experimentally create the most realistic model of cerebral ischemia, various techniques have been developed on different groups of animals (31,32). In our study, we chose rats for obvious reasons, since their cerebral circulatory system is

very similar to that of humans and they are readily available and inexpensive.

Ischemia in the studies of the cerebral ischemia-reperfusion model in rats time varies between 5-30 minutes, and reperfusion times are determined according to the parameters to be examined (33). The damage in the cerebral ischemia-reperfusion model studies in rodents; has been shown several times to vary according to ischemia and reperfusion times and the severity of ischemia (34). Reperfusion damage has been shown to be low with a short ischemia time, whereas damage and thus infarct volume increase with a longer ischemia time (35).

Various drugs, calcium channel blockers, radical scavengers, and glutamate receptor antagonists are used to prevent or reverse the damage that occurs after ischemia (36).

Astaxanthin is a powerful antioxidant that has a protective effect against reactive oxygen species. Astaxanthin acts against inflammation. Similarly, AST formulations based on structured systems in liquid or solid phase can lead to the stabilization of astaxanthin during absorption. Previous research involving animal studies and clinical trials has consistently shown that AST has a high level of safety and tolerability. The safety, bioavailability, and effects of AST on oxidative stress and inflammation indicate its potential therapeutic use for a range of health issues, including as cardiovascular disease and protection against ultraviolet radiation. These properties have been assessed in a limited number of clinical investigations (37).

In this study, the effect of AST, which has antioxidant and anti-inflammatory properties, was investigated in rats with cerebral ischemia-reperfusion. Recent studies on animal models have shown that AST has a protective impact by reducing oxidative damage in ischemia reperfusion-related liver, brain (38) or cardiovascular (37) injuries. Another research showed that AST decreased oxidative injury in cerebral ischemia-reperfusion injury (39).

The role of ROS is significant in the development of ischemia-reperfusion damage. The occurrence of excessive free radicals and MDA formation, together with detrimental impacts on antioxidative defense enzymes like SOD and glutathione peroxidase, is observed in cases of global and cerebral ischemia-reperfusion when blood flow is reduced and then restored (40). SOD, GPX, and CAT are key enzymatic antioxidants, which convert ROS into less noxious compounds (41). Malondialdehyde serves as a final product and biomarker for the process of lipid peroxidation. The activities of SOD and the contents of MDA are indicative of the equilibrium between oxidative and antioxidative processes inside the brain (42). The excessive formation of ROS and the reduced capacity of antioxidant enzymes are factors that contribute to neuronal death and the development of problems related to brain damage. A recent study revealed that cerebral ischemia-reperfusion resulted in aberrant levels of MDA, GSH,

and SOD in brain tissue. According to reports, the administration of ATS in rats has demonstrated a considerable reduction in MDA levels and an increase in Glutathione levels. This effect is believed to provide protection against oxidative stress generated by cyclophosphamide (43). According to a study (44), ATS has demonstrated the ability to decrease oxidative stress and enhance behavioral problems in a mouse model of autism. Various studies have documented that the antioxidative properties of ATS confer protection against oxidative damage in the amygdala kindling model of epilepsy in rats (45). The findings presented in this study provide confirmation that ATS has the potential to serve as a protective agent in mitigating the oxidative stress that arises from cerebral ischemia.

Concurrently with these investigations, we demonstrated that cerebral ischemia/reperfusion, a condition characterized by interrupted blood flow followed by its restoration, resulted in a decrease in SOD activity within the brain tissue. Superoxide dismutase is regarded as the primary endogenous antioxidant in the body. Also, we showed that AST treatment could reduce MDA levels and increase the activity of SOD and CAT after ischemia-reperfusion injury. These results indicate that the protective effect of AST against ischemia-reperfusion injury might be mediated through reducing ischemia-reperfusion injury-induced oxidative stress.

The fact that AST can cross the blood-brain barrier has led to its preferential use, especially in cerebral ischemia studies, and positive results have been obtained. Hematoxylin-eosin staining is commonly performed in cerebral ischemia studies to observe the effects of cerebral ischemia-reperfusion on neurons (46).

Previous research conducted on animal models has demonstrated that the early treatment of AST during the ischemia-reperfusion process leads to a considerable decrease in cell death inside the hippocampus (47). The hippocampus plays a significant role in cognitive function, and its neurons exhibit heightened vulnerability to cerebral ischemia. Recent research has demonstrated that the impairment of learning and memory function is associated with the depletion of hippocampus pyramidal neurons during cerebral ischemia-reperfusion (48).

The study conducted by Xue et al. provides evidence that AST supplementation improves cognitive impairments associated with cerebral ischemia-reperfusion injury. This intervention effectively reduces degeneration and death of hippocampus neurons (49). Studies in young rats have shown that ischemic brain damage can be reduced by AST (47).

In our study, cerebral tissue sections were evaluated by staining with hematoxylin-eosin. Intense damage and many necrotic neurons were observed in the cerebral cortex of the sham group.

Less damage and necrotic neurons were observed in the cerebral cortex of animals treated with AST compared to the Sham group. This shows us that AST can significantly reduce the damage, that

is, it has a protective effect. In summary, the current investigation has established that AST exhibits substantial neuroprotective properties in the context of cerebral ischemia-reperfusion. The processes can be ascribed to the suppression of oxidative stress. The findings of this study indicate that astaxanthin has the potential to serve as a novel therapeutic intervention for mitigating the effects of cerebral ischemia-reperfusion damage.

**Ethic Committee Approval:** Approval was obtained from Eskisehir Osmangazi University Ethics Committee with the decision dated 16.08.2016 and numbered 544/2016.

**Peer-review:** Externally peer-reviewed.

**Author Contributions:** Concept - BY, HÖ; Design - BY, HÖ, SÖ; Supervision - BY, HÖ, SÖ; Data Collection and/or Processing - BY, HÖ, SÖ, SCK, CÜ, DB; Analysis and/or Interpretation - BY, CÜ, DB; Literature Search - BY, HÖ; Writing - BY, HÖ; Critical Reviews - BY.

**Conflict of Interest:** The authors do not have any conflicts of interest.

**Financial Disclosure:** The authors declared that this study has received no financial support.

## References

- Mehta SL, Manhas N, Raghubir R. Molecular targets in cerebral ischemia for developing novel therapeutics. *Brain Res Rev.* 2007;54:34–66. <https://doi.org/10.1016/j.brainresrev.2006.11.003>
- Majino G, Jorris I. Apoptosis, oncosis, and necrosis—an overview of the cell death. *Am J Pathol.* 1995;146:3–15. Available at: <https://pubmed.ncbi.nlm.nih.gov/7856735/>
- Zimmerman BJ, Granger DN. Reperfusion injury. *Surg Clin North Am.* 1992;72:65–83. [https://doi.org/10.1016/S0039-6109\(16\)45628-8](https://doi.org/10.1016/S0039-6109(16)45628-8)
- Collard CD, Gelman S. Pathophysiology, clinical manifestations, and prevention of ischemia-reperfusion injury. *Anesthesiology.* 2001;94:1133–1138. <https://doi.org/10.1097/0000542-200106000-00030>
- Vardanian AJ, Busuttill RW, Kepiece-Weglinski J. Molecular mediators of liver ischemia and reperfusion injury: a brief review. *Mol Med.* 2008;14(5-6):337–345. <https://doi.org/10.2119/2007-00134.Vardanian>
- Wahul AB, Joshi PC, Kumar A, Chakravarty S. Transient global cerebral ischemia differentially affects cortex, striatum and hippocampus in bilateral common carotid arterial occlusion (BCCAO) mouse model. *J Chem Neuroanat.* 2018;92:1–15. <https://doi.org/10.1016/j.jchemneu.2018.04.006>
- Ma M, Uekawa K, Hasegawa Y, Nakagawa T, Katayama T, Sueta D, et al. Pretreatment with rosuvastatin protects against focal cerebral ischemia/reperfusion injury in rats through attenuation of oxidative stress and inflammation. *Brain Res.* 2013;1519:87–94. <https://doi.org/10.1016/j.brainres.2013.04.040>
- Chen H, Yoshioka H, Kim GS, Jung JE, Okami N, Sakata H, et al. Oxidative stress in ischemic brain damage: Mechanisms of cell death and potential molecular targets for neuroprotection. *Antioxid Redox Signal.* 2011;14:1505–1517. <https://doi.org/10.1089/ars.2010.3576>
- Eltzschig HK, Eckle T. Ischemia and reperfusion—from mechanism to translation. *Nat Med.* 2011;17:1391–1401. <https://doi.org/10.1038/nm.2507>
- Davey A, Agrawal SK. Neuroprotective effects of Riluzole and Curcumin in human astrocytes and spinal cord white matter hypoxia. *Neurosci Lett.* 2020;738:135351. <https://doi.org/10.1016/j.neulet.2020.135351>
- Nguyen TP, Koyama M, Nakasaki K. Effects of oxygen supply rate on organic matter decomposition and microbial communities during composting in a controlled lab-scale composting system. *Waste Manag.* 2022;153:275–282. <https://doi.org/10.1016/j.wasman.2022.09.004>
- Lindblom RPF, Tovedal T, Norlin B, Hillered L, Englund E, Thelin S. Mechanical reperfusion following prolonged global cerebral ischemia attenuates brain injury. *J Cardiovasc Transl Res.* 2020. <https://doi.org/10.1007/s12265-020-10058-9>
- Zeng X, Wang H, Xing X, Wang Q, Li W. Dexmedetomidine protects against transient global cerebral ischemia/reperfusion-induced oxidative stress and inflammation in diabetic rats. *PLoS One.* 2016;11:e0151620. <https://doi.org/10.1371/journal.pone.0151620>
- Zheng YF, Bae SH, Kwon MJ, Park JB, Choi HD, Shin WG, et al. Inhibitory effects of astaxanthin,  $\beta$ -cryptoxanthin, canthaxanthin, lutein, and zeaxanthin on cytochrome P450 enzyme activities. *Food Chem Toxicol.* 2013;59:78–85. <https://doi.org/10.1016/j.fct.2013.04.053>
- Zarneshan SN, Fakhri S, Farzaei MH, Khan H, Saso L. Astaxanthin targets PI3K/Akt signaling pathway toward potential therapeutic applications. *Food Chem Toxicol.* 2020;145. <https://doi.org/10.1016/j.fct.2020.111714>
- Bjerkeng B, Peisker M, von Schwartzberg K, Ytrestyl T, Åsgård T. Digestibility and muscle retention of astaxanthin in Atlantic salmon, *Salmo salar*, fed diets with the red yeast *Phaffia rhodozyma* in comparison with synthetic formulated astaxanthin. *Aquaculture.* 2007;269:476–489. <https://doi.org/10.1016/j.aquaculture.2007.04.070>
- Akkoyun HT, Uyar A, Bengü AŞ, Bayramoglu-Akkoyun M, Arihan O, Keles OF. Protective effect of astaxanthin in the lung injury caused by ischemia-reperfusion of the lower extremities. *J Anim Plant Sci.* 2019;29(1):82–90.
- Zuluaga M, Barzegari A, Letourneur D, Gueguen V, Pavon-Djavid G. Oxidative stress regulation on endothelial cells by hydrophilic astaxanthin complex: chemical, biological, and molecular antioxidant activity evaluation. *Oxid Med Cell Longev.* 2017;2017:8073798. <https://doi.org/10.1155/2017/8073798>
- Yamagishi R, Aihara M. Neuroprotective effect of astaxanthin against rat retinal ganglion cell death under various stresses that induce apoptosis and necrosis. *Mol Vis.* 2014;20:1796–1805.
- Zhang XS, Zhang X, Wu Q, Li W, Wang CX, Xie GB, et al. Astaxanthin offers neuroprotection and reduces neuroinflammation in experimental subarachnoid hemorrhage. *J Surg Res.* 2014;192(1):206–213. <https://doi.org/10.1016/j.jss.2014.05.029>
- Galasso C, Orefice I, Pellone P, Cirino P, Miele R, Ianora A, et al. On the neuroprotective role of astaxanthin: new perspectives? *Mar Drugs.* 2018;16:247. <https://doi.org/10.3390/md16080247>
- Lee DH, Lee YJ, Kwon KH. Neuroprotective effects of astaxanthin in oxygen-glucose deprivation in SH-SY5Y cells and global cerebral ischemia in rat. *J Clin Biochem Nutr.* 2010;47(2):121–129. <https://doi.org/10.3164/jcfn.10-29>
- Taksima T, Chonpathompikunlert P, Sroyraya M, Hutamekalin P, Limpawattana M, Klaypradit W. Effects of astaxanthin from shrimp shell on oxidative stress and behavior in animal model of Alzheimer's disease. *Mar Drugs.* 2019;17:628. <https://doi.org/10.3390/md17110628>
- Shen DF, Qi HP, Ma C, Chang MX, Zhang WN, Song RR. Astaxanthin suppresses endoplasmic reticulum stress and protects against neuron damage in Parkinson's disease by regulating miR-7/SNCA axis. *Neurosci Res.* 2021;165:51–60. <https://doi.org/10.1016/j.neures.2020.04.003>
- Sun Y, Oberley LW, Li Y. A simple method for clinical assay of superoxide dismutase. *Clin Chem.* 1988;34:497–500. <https://doi.org/10.1093/clinchem/34.3.497>
- Esterbauer H, Cheeseman KH. Determination of aldehydic lipid peroxidation products: malonaldehyde and 4-hydroxynonenal. *Methods Enzymol.* 1990;186:407–421. [https://doi.org/10.1016/0076-6879\(90\)86134-H](https://doi.org/10.1016/0076-6879(90)86134-H)
- Aebi H. Catalase. In: Bergmeyer U, editor. *Methods of enzymatic analysis.* NY & London: Academic Press; 1974. pp. 673–680. <https://doi.org/10.1016/B978-0-12-091302-2.50032-3>
- Kietzmann T, Knabe W, Schmidt-Kastner R. Hypoxia and hypoxia-inducible factor modulated gene expression in brain: involvement in neuroprotection and cell death. *Eur Arch Psychiatry Clin Neurosci.* 2001;251:170–178. <https://doi.org/10.1007/s004060170037>
- Agardh CD, Zhang H, Smith ML, Siesjö BK. Free radical production and ischemic brain damage: influence of postischemic oxygenation. *Int J Dev Neurosci.* 1991;9:127–138. [https://doi.org/10.1016/0736-5748\(91\)90003-5](https://doi.org/10.1016/0736-5748(91)90003-5)
- Kontos HA. Oxygen radicals in cerebral ischemia: the 2001 Willis lecture. *Stroke.* 2001;32:2712–2716. <https://doi.org/10.1161/hs1101.098653>
- Drummond JC, Cole DJ, Patel PM, Reynolds LW. Focal cerebral ischemia during anesthesia with etomidate, isoflurane, orthiopental: a comparison of the extent of cerebral injury. *Neurosurgery.* 1995;37:472–479. <https://doi.org/10.1097/00006123-199510000-00019>
- Hillered L, Hallström A, Segersuard S, Persson L, Ungerstedt U. Dynamics of extra-cellular metabolites in the striatum after middle cerebral artery occlusion in the rat monitored by intracerebral microdialysis. *J Cereb Blood Flow Metab.* 1989;9:607–616. <https://doi.org/10.1038/jcbfm.1989.87>
- Selakovic V, Korenic A, Radenovic L. Spatial and temporal patterns of oxidative stress in the brain of gerbils submitted to different duration of global cerebral ischemia. *Int J Dev Neurosci.* 2011;29(6):645–654. <https://doi.org/10.1016/j.ijdevneu.2011.02.009>
- Volpe BT, Hirst W. The characterization of an amnesic syndrome following hypoxic-ischemic injury. *Arch Neurol.* 1983;40:436–440. <https://doi.org/10.1001/archneur.1983.04050070066017>
- White BC, Sullivan JM, DeGracia DJ, O'Neil BJ, Neumar RW. Brain ischemia and reperfusion: molecular mechanisms of neuronal injury. *J Neurol Sci.* 2000;179:1–33. [https://doi.org/10.1016/S0022-510X\(00\)00386-5](https://doi.org/10.1016/S0022-510X(00)00386-5)

36. Aarts MM, Tymianski M. Molecular mechanisms underlying specificity of excitotoxic signaling in neurons. *Curr Mol Med.* 2004;4:137-147. <https://doi.org/10.2174/1566524043479202>
37. Fassett RG, Coombes JS. Astaxanthin: a potential therapeutic agent in cardiovascular disease. *Mar Drugs.* 2011;9:447-465. <https://doi.org/10.3390/md9030447>
38. Shen H, Kuo CC, Chou J, Delvolve A, Jackson SN, Post J, et al. Astaxanthin reduces ischemic brain injury in adult rats. *FASEB J.* 2009;23:1958-1968. <https://doi.org/10.1096/fj.08-123281>
39. Cakir E, Cakir U, Tayman C, Turkmenoglu TT, Gonel A, Turan IO. Favorable effects of astaxanthin on brain damage due to ischemia-reperfusion injury. *Comb Chem High Throughput Screen.* 2020;23:214-224. <https://doi.org/10.2174/1386207323666200219121600>
40. Liu Z, Cai Y, Zhang X, Zhu Z, He J. High serum levels of malondialdehyde and antioxidant enzymes are associated with post-stroke anxiety. *Neurol Sci.* 2018;39:999-1007. <https://doi.org/10.1007/s10072-018-3287-4>
41. Jeeva JS, Sunitha J, Ananthalakshmi R, Rajkumari S, Ramesh M, Krishnan R. Enzymatic antioxidants and its role in oral diseases. *J Pharm Bioallied Sci.* 2015;7:S331-S333. <https://doi.org/10.4103/0975-7406.163438>
42. Khoubnasabjafari M, Ansarin K, Jouyban A. Reliability of malondialdehyde as a biomarker of oxidative stress in psychological disorders. *Bioimpacts.* 2015;5:123-127. <https://doi.org/10.15171/bi.2015.20>
43. Tripathi DN, Jena GB. Astaxanthin intervention ameliorates cyclophosphamide-induced oxidative stress, DNA damage and early hepatocarcinogenesis in rat: role of Nrf2, p53, p38, and phase-II enzymes. *Mutat Res.* 2010;696:69-80. <https://doi.org/10.1016/j.mrgentox.2009.12.014>
44. Al-Amin MM, Rahman MM, Khan FR, Zaman F, Mahmud Reza H. Astaxanthin improves behavioral disorder and oxidative stress in prenatal valproic acid-induced mice model of autism. *Behav Brain Res.* 2015;286:112-121. <https://doi.org/10.1016/j.bbr.2015.02.041>
45. Lu Y, Xie T, He XX, Mao ZF, Jia LJ, Wang, W. P., et al. Astaxanthin rescues neuron loss and attenuates oxidative stress induced by amygdala kindling in adult rat hippocampus. *Neurosci Lett.* 2015;597:49-53. <https://doi.org/10.1016/j.neulet.2015.04.018>
46. Filipsky T, Riha M, Macakova K, Anzenbacherova E, Karlickova J, Mladenka P. Antioxidant effects of coumarins include direct radical scavenging, metal chelation, and inhibition of ROS-producing enzymes. *Curr Top Med Chem.* 2015;15(5):415-431. <https://doi.org/10.2174/1568026615666150206152233>
47. Lee DH, Lee YJ, Kwon KH. Neuroprotective effects of astaxanthin in oxygen-glucose deprivation in SH-SY5Y cells and global cerebral ischemia in rat. *J Clin Biochem Nutr.* 2010;47(2):121-129. <https://doi.org/10.3164/jcbn.10-29>
48. Yue ZY, Dong H, Wang YF, Liu Y, Song CY, Yang WC, et al. Propofol prevents neuronal mtDNA deletion and cerebral damage due to ischemia/reperfusion injury in rats. *Brain Res.* 2015;1594:108-114. <https://doi.org/10.1016/j.brainres.2014.10.016>
49. Xue Y, Qu Z, Fu J, Zhen J, Wang W, Cai Y, et al. The protective effect of astaxanthin on learning and memory deficits and oxidative stress in a mouse model of repeated cerebral ischemia/reperfusion. *Brain Res Bull.* 2017;131:221-228. <https://doi.org/10.1016/j.brainresbull.2017.04.019>