

## Disappeared Third Molar Tooth: A Case Report

Eren Yılmaz<sup>1</sup> (ID)

<sup>1</sup>Department of Oral and Maxillofacial Surgery, Karabük University Faculty of Dentistry

Received: 04 September 2023, Accepted: 15 December 2023, Published online: 30 April 2024

© Ordu University Institute of Health Sciences, Turkey, 2023

### Abstract

Many complications can be encountered during diagnosis and treatment in healthcare. These can range from the simple to the serious enough to be life-threatening. Preventing complications before they occur is essential. However, they can occur despite all the precautions taken. When they develop, the process needs to be managed properly.

Foreign body ingestion and aspiration are among the most important complications in dentistry. While complications can be overcome more easily in cases of ingestion, emergency intervention may be required in cases of aspiration. In both cases, medical doctors and dentists must work in coordination and the process must be managed.

In this case report, the diagnosis of a third molar tooth that was ingested during extraction and the subsequent process is shared.

**Keywords:** Aspiration, Ingestion, Third Molar.

### Gözden Kaybolan Üçüncü Molar Diş: Olgu Sunumu

#### Özet

Sağlıkta tanı ve tedaviler sırasında birçok komplikasyonla karşılaşılabilir. Bunlar basitten, hayatı tehdit edecek kadar önemli düzeyde olanlara kadar değişebilir. Komplikasyonların meydana gelmeden önlenmesi esastır. Ancak alınan bütün önlemlere rağmen meydana gelebilirler. Geliştiklerinde sürecin doğru bir şekilde yönetilmesi gerekmektedir.

Yabancı cisim yutulması ve aspirasyonu, diş hekimliği alanında meydana gelen en önemli komplikasyonlardandır. Yutma olgularında komplikasyon daha kolay atlatabilirken, aspirasyon olgularında acil müdahale gerekebilmektedir. Her iki durumda da mutlaka tıp hekimleri ile diş hekimleri koordineli çalışmalı ve süreç yönetilmelidir.

Bu olgu sunumunda çekim sırasında yutulan bir üçüncü molar dişin tanısı ve sonrasında gelişen süreç paylaşılmaktadır

**Anahtar Kelimeler:** Aspirasyon, Yutma, Üçüncü Molar Diş

**Suggested Citation:** Yılmaz E. Disappeared Third Molar Tooth: A Case Report. ODU Med J, 2024;11(1): 49-54.

Copyright© Author(s) - Available online at <https://dergipark.org.tr/tr/pub/odutip>

Content of this journal is licensed under a Creative Commons Attribution-NonCommercial 4.0 International License.



#### Address for correspondence/reprints:

Eren Yılmaz

**Telephone number:** +90 (370) 418 92 29

**E-mail:** erenyilmaz@karabuk.edu.tr

#### INTRODUCTION

Health is an important and indispensable value for human life. Its deficiency is unthinkable. Because health affects whole life. The disorder in the structure and functions of the organism makes

it impossible to continue life in an ideal way. Disorders in health are defined as diseases and they must be diagnosed and treated (1).

A certain amount of knowledge is required for the treatment of diseases. In addition, it is essential that the application be performed with the utmost care and attention to interventional treatments. However, the occurrence of negativities may be inevitable in some cases no matter how meticulously the physician works. These situations are called complications (2).

Physicians encounter complications in many treatments that they apply throughout their professional lives. These can range from simple to dangerous for patients. Prevention of complications is one of the most important duties of the physician. If it develops despite all kinds of precautions, it is also among the duties of the physician to manage and eliminate it and inform the patient and their relatives if necessary (3).

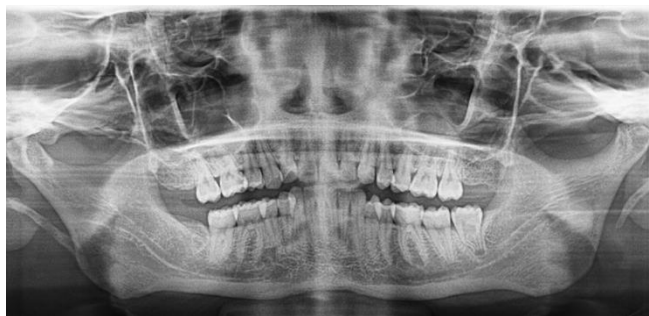In the field of dentistry, many complications can be encountered during treatments. Foreign body ingestion or aspiration is among the most important of these (4). In case of ingestion, there is not much to be done, it is usually expected to come out from digestive tract. However, its aspiration can cause serious complications (5). Because of this, it is very important that the process is managed correctly and that dentists work in coordination with the medical doctors of the relevant departments.

Tooth extractions are among the important treatments in dentistry in which the mentioned complications are observed. Indications for tooth extraction include caries, pulp necrosis, impacted or semi-impacted teeth, association with pathological lesions, and some systemic problems of the individual. On the other hand, tooth extraction is contraindicated in individuals with severe pericoronitis, whose systemic condition is not suitable for surgery, and whose tooth is adjacent to malignant lesions (6).

In this case report, the aim is to share the detection of an ingested tooth during extraction and the subsequent process.

### **CASE REPORT**

A 21-year-old female patient came to our clinic with swelling on the left side of the lower jaw. In her anamnesis, it was learned that she did not have any systemic disease. She reported swelling and pain in her left lower jaw occasionally and this situation improved after antibiotic treatment. In the clinical examination, it was determined that the distal half of tooth 38 was impacted and swelling and hyperemia developed in the soft tissues around the tooth. Panoramic radiography showed that the development of the tooth continued and there was an S-shaped curvature in the mesial root. It was confirmed that there was no other pathology or dental caries in this region (Figure 1).

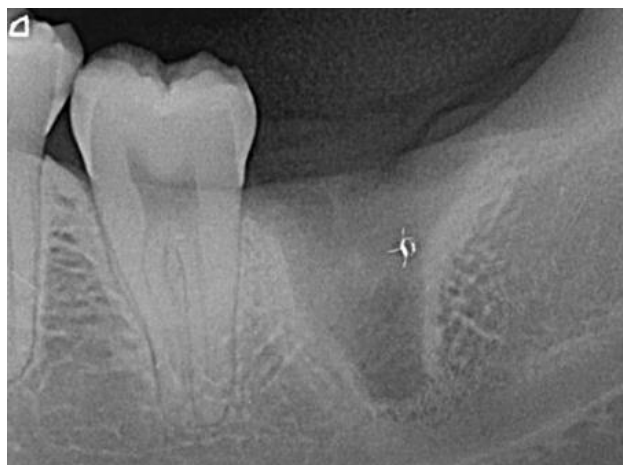


**Figure 1.** Patient's panoramic radiography.

Extraction of the tooth for the treatment was recommended to the patient. Detailed information about the procedure was given and all possible risks were explained. After that, the patient's written consent was obtained, and the extraction of the tooth was started. The flap was removed after local anesthesia. The tooth was fully raised with the elevator. It was observed that the patient developed a nausea reflex while holding the tooth with extraction forceps, and then the tooth was not in place.

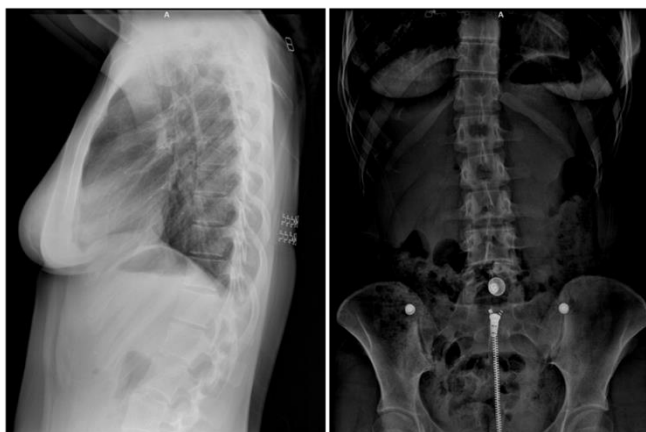The inside of the mouth was checked in detail. The surgical area and its neighbors were searched, but no teeth were found. A periapical radiograph revealed that the tooth had come out of the socket totally (Figure 2). The surgical field was sutured. In this whole process, no symptoms were observed in the patient like a cough, shortness of breath, etc. The patient, who was thought to have ingested the tooth, was immediately referred to the emergency department. A detailed consultation about the situation was written and given to the patient. An hour later, the patient came back to the clinic and declared that several radiographies were taken in the emergency department and that the tooth was

not in the lungs and stomach. Thereupon, the clinic was searched again, but the tooth was not found.

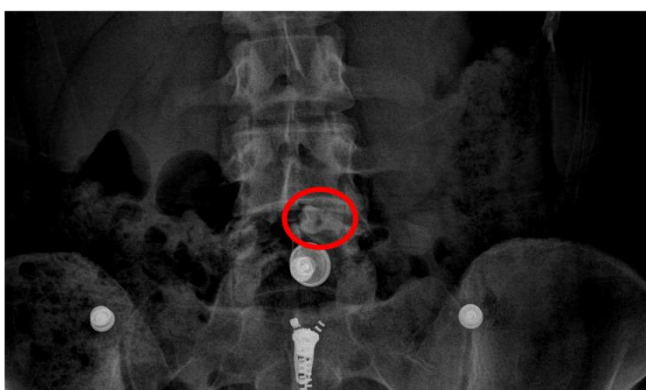

**Figure 2.** Patient's periapical radiography after extraction.

Then the radiographies taken in the emergency department were opened and analyzed via the online system with the patient's permission (Figure 3a-3b). A tooth superposed with the L5 vertebra was detected in the direct abdominal radiography (Figure 4). It was told to the patient that she ingested the tooth, and it would come out digestive tract without damaging any part of the digestive system and, stool follow-up would be beneficial just in case. A phone number was given to her to keep in touch with the clinic and report the situation. It was told that she should apply to the emergency department if an unexpected situation develops. The patient who called on the second day after the procedure said that the tooth had come out from the body.



**Figure 3a-3b.** Patient's lateral lung and direct abdomen radiographies.



**Figure 4.** The tooth which seen on patient's direct abdomen radiography.

## DISCUSSION

Loss of a material used during dental treatments and an extracted tooth, or a tooth piece may occur. The main thing to avoid such problems is to take all necessary precautions and prevent complications. If encountered, the first thing to do is to check the oral cavity and clinic. If not found, it should be considered to go down the oropharynx. Aspiration or ingestion may have occurred here. Which of these occurred should be determined without delay and a course should be followed accordingly (5,6).

Foreign body aspirations are serious complications. Severe cough, pain, shortness of breath, and complete airway obstruction may be seen after aspiration. Some cases may be asymptomatic and serious lung infection may develop in them. In case of aspiration, the patient should be referred to the emergency service as soon as possible and the necessary intervention should be made by the relevant physician (6).

Ingestion foreign bodies is undesirable. However, it is a complication that can be overcome more easily than aspiration. If the object is not pointed, protruding, toxic, etc., it can be easily removed from the digestive system without the need for any intervention. It can be checked whether the object has come out with stool follow-up or radiographs taken at intervals (3).

The patient should be given the necessary information and told that there is no cause for concern in both cases. Always stay in contact with the patient and the patient should be followed up until the complication disappears and the process should be managed ideally.

Medical doctors may not have detailed information about the anatomy of the mouth, teeth, jaw and surrounding tissues, and the diagnosis and treatment of diseases in this region. The same is true for dentists who constantly work in the head and neck region. Therefore, in some cases, the coordinated work of medical doctors and dentists is important.

Emergency departments are the busiest places where health care is provided. Sudden diseases, accidents, injuries, and life-threatening conditions are diagnosed and treated in these units, which work 24 hours a day. Diagnosis and treatment must be carried out quickly due to its nature. This means intense physical and mental workload. Emergency departments physicians, who must make quick and accurate decisions, may make mistakes when deciding on the right diagnosis and treatment under intense physical and mental workload like any physician. For this reason, every effort should be made to prevent unnecessary referrals and individual applications to emergency departments (7,8).

### CONCLUSION

Although Adult Still's Disease should be kept in mind in terms of making a differential diagnosis from other diseases and initiating treatment quickly. In this case, we presented a case of resistant AOSD that was resistant to systemic corticosteroids and complicated by MAS and DAH. The use of tocilizumab after corticosteroids in the treatment of such complicated cases seems promising.

**Ethics Committee Approval:** The presented study is qualitative, and consent was obtained by giving information about the study by one-to-one interviews with the subjects who agreed to participate. The study was carried out by paying attention to the Declaration of Helsinki.

**Author Contributions:**

Concept: EY, Design: EY, Supervision: EY, Data Collection and/or Processing: EY, Analysis and/or Interpretation: EY, Writing: EY.

**Declaration of Interests:** The author declared no conflicts of interest with respect to the authorship and/or publication of this article.

**Funding:** The author received no financial support for the research and/or authorship of this case report.

---

### REFERENCES

1. Alu A. Fundamental concepts of health. *Journal of Health Management*. 2017; 1(2): 32-41.
2. Birtek F. Discrimination of complications from medical interventions and malpractice. *Istanbul Bar Association Journal*. 2007; 81(5): 1937-2006.
3. Milton TM, Hearing SD, Ireland AJ. Ingested foreign bodies associated with orthodontic treatment: report of three cases and review of ingestion/aspiration incident management. *British Dental Journal*. 2001; 190(11): 592-6.
4. Kuo SC, Chen YL. Accidental swallowing of an endodontic file. *International Endodontic Journal*. 2008; 41(7): 617-22.
5. Henderson CT, Engel J, Schlesinger P. Foreign body ingestion: review and suggested guidelines for management. *Endoscopy*. 1987; 19(2): 68-71.
6. Kim E, Noh W, Panchal N. Mortality from aspiration of a dental crown during extraction. *Gerodontology*. 2017; 34(4): 498-500.

7. Kılıç Delice, E. Assessment of mental workload of emergency physicians using the nasa-rtlx method: an application study. *Atatürk University Journal of Economics and Administrative Sciences*. 2016; 30(3): 645-662.
8. Söyük S, Arslan Kurtuluş S. Evaluation of problems experienced in emergency services from the perspective of employees. *Gümüşhane University Journal of Health Sciences*. 2017; 6(4): 44-56.