



## Clinical, Laboratory, Radiography and Ultrasonography Findings and Surgical Treatment the Lower Urinary System Urolithiasis in Cats and Dogs

Rahime YAYGINGÜL<sup>1\*</sup>

<sup>1</sup>Aydın Adnan Menderes University, Veterinary Faculty, Department of Surgery, Aydın, TÜRKİYE

### ABSTRACT

This study aimed to investigate the clinical, laboratory, radiography, and ultrasonography findings for the diagnosis of urolithiasis in cats and dogs. This study consisted a total of 17 animals, of those; 7 cats and 10 dogs were of different ages, breeds, and sex. Urolithiasis diagnosis was made through urine analysis, radiography and ultrasonographic findings. Radiopaque stones were detected in the bladder (n=13), only in the urethra (n=2), and both in the urethra and bladder (n=2). Urethrotomy was performed in two animals with urolith in the urethra, and cystotomy was performed in two cases by pushing the stones in the urethra into the urinary bladder with uroretropropulsion. In other cases, uroliths were removed from the bladder by cystotomy. The uroliths were analyzed by the biochemical method. The results of the present study revealed that clinical, hematological, biochemical, urinalysis, radiographic, and ultrasonographic examinations are essential in dogs and cats for the accurate diagnosis of urolithiasis.

**Keywords:** Cats, diagnosis, dogs, urolithiasis, treatment.

## Kedi ve Köpeklerde Alt Üriner Sistem Ürolitiazisin Klinik, Laboratuvar, Radyografi ve Ultrasonografi Bulguları ve Cerrahi Tedavisi

### ÖZET

Bu çalışmada kedi ve köpeklerde ürolitiazis tanısı için klinik, laboratuvar, radyografi ve ultrasonografi bulgularının değerlendirilmesi amaçlanmıştır. Çalışmaya farklı yaş, ırk ve cinsiyette 7 kedi ve 10 köpek olmak üzere toplam 17 hayvan dahil edildi. Ürolitiazis tanısı, idrar analizi, radyografi ve ultrasonografik bulgular ile konuldu. Radyoopak taşlar idrar kesesinde (n=13), sadece üretrada (n=2) ve hem üretra hem de idrar kesesinde (n=2) tespit edildi. Üretrada üroliti olan iki hayvana üretrotomi yapıldı ve iki olguda üretradaki taşlar üroretropropulsiyon ile mesaneye itilerek sistotomi yapıldı. Diğer olgularda ise sistotomi ile ürolitler idrar kesesinden çıkarıldı. Daha sonra ürolitler biyokimyasal yöntemlerle analiz edildi. Bu çalışmanın sonuçları, ürolitiazisin doğru teşhisi için köpek ve kedilerde klinik, hematolojik, biyokimyasal, idrar tahlili, radyografik ve ultrasonografik muayenelerin gerekli olduğunu ortaya koymuştur.

**Anahtar kelimeler:** Kedi, köpek, tanı, tedavi, ürolitiazis.

\*Corresponding author: Rahime YAYGINGÜL, Aydın Adnan Menderes University, Veterinary Faculty, Department of Surgery, Aydın, TÜRKİYE. ryayingul@adu.edu.tr

Received Date: 13.10.2023 - Accepted Date: 27.02.2024

DOI: 10.53913/aduveterinary.1375487

## Introduction

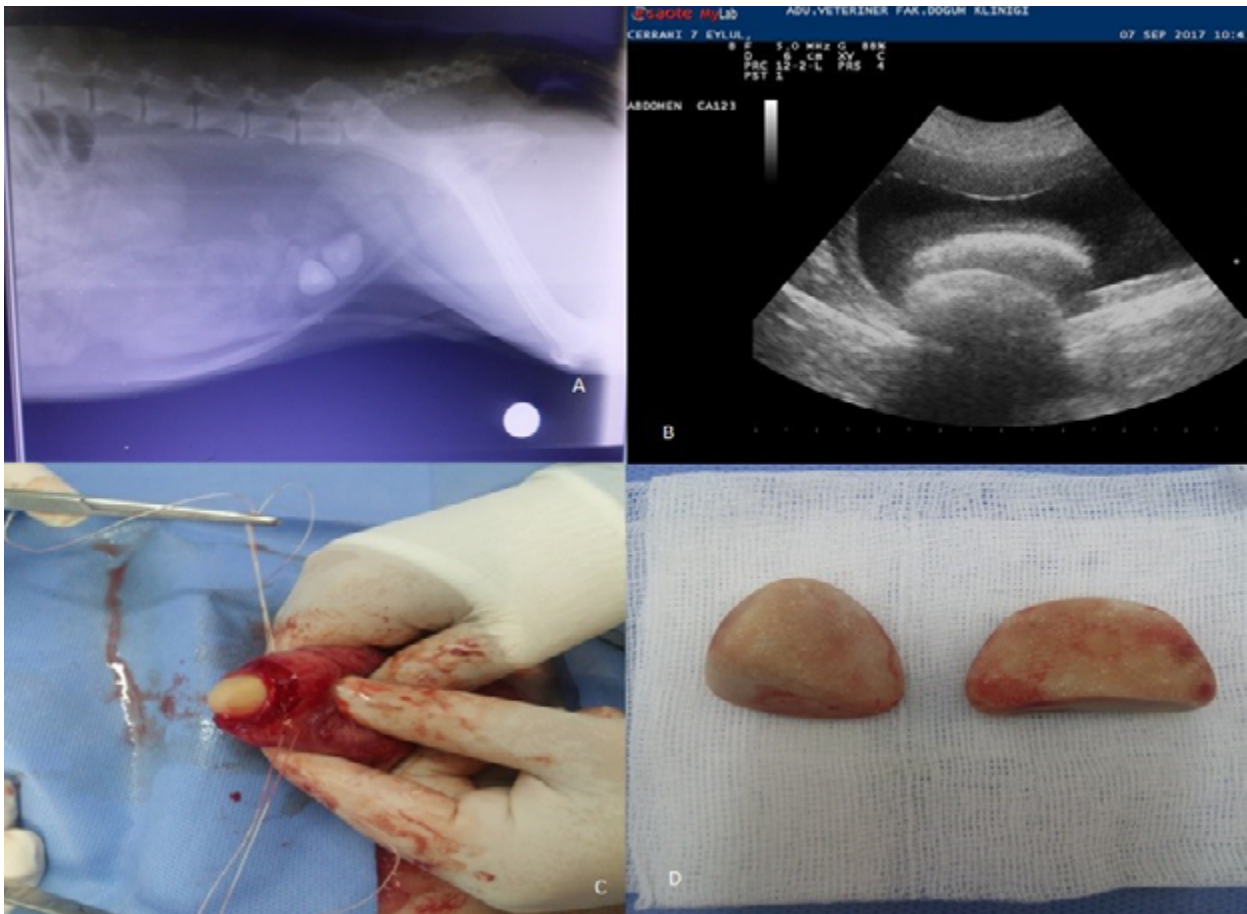
Urolithiasis is a general term given to stone formation and its results in any part of the urinary system, and most commonly in the bladder. Uroliths are commonly observed in both dogs and cats. Many factors are effective in the formation of urinary stones. Anatomical and functional anomalies of the urinary system, metabolic abnormalities, urinary tract infections, poor diets, and changes in the urine pH are important factors in the formation of uroliths. Some dog breeds that are predisposed to urolithiasis include Dachshund, Pekingese, Dalmatian, Miniature Schnauzer, Poodle, Pug, Coker Spaniel, Terrier, Bulldog, Beagle, and Basset Hound. In cats, no breed predisposition was specified (Kaya, 1998; Bumin and Temizsoylu, 2000; Fossum et al., 2007; Houston and Moore, 2009; Sancak et al., 2009; Albasan et al., 2013). Clinical signs, including hematuria, dysuria, pollakiuria, and stranguria, can vary depending on the location, size, and number of uroliths (Nelson and Couto, 2014). The diagnosis of urolithiasis mostly consists of a history, clinical examination, urine analysis, complete blood cell count, serum biochemical analysis, and radiographic and ultrasonographic examination (Tion et al., 2015; Tiruneh and Abdisa, 2017; Polat and Sağılyan, 2022). Therefore, the main purpose of this study was to investigate clinical, laboratory, radiography,

and ultrasonography findings for the diagnosis of urolithiasis in cats and dogs.

## Materials and Methods

This study protocol was approved by Aydın Adnan Menderes University Animal Experiments Local Ethics Committee (HADYEK) on 27.07.2016 and numbered with 64583101/2016/016.

The study was conducted on 7 cats and 10 dogs of different ages, breeds, and sexes. All animals were brought to Aydın Adnan Menderes University Veterinary Faculty Surgery Clinic with lower urinary system complaints, such as dysuria, hematuria, pollakiuria, urinary incontinence and/or urinary retention. All animals were underwent clinical, hematological and biochemical, urine analysis, radiographic and ultrasonographic examinations. Firstly, a detailed anamnesis was obtained from the owners. Then, vital signs (body temperature, heart rate, and respiratory rate) were evaluated. After the clinical examination, venous blood samples were taken into a 2 ml serum separation tube for hematological and biochemical analysis (urea nitrogen and creatinine), and into a 2 ml heparinized blood gas injector for blood gases and serum electrolyte analysis [sodium (Na), ionized calcium ( $Ca^{++}$ ), potassium (K), pH (pH), carbon dioxide partial pressure ( $pCO_2$ ), oxygen partial pressure ( $pO_2$ ), bicarbonate concentration ( $HCO_3$ ), hematocrit (HCT) and



**Figure 1.** A: Radiographic appearance of uroliths in vesica urinaria; B: Ultrasonographic appearance of uroliths in vesica urinaria; C: Intraoperative image of uroliths in vesica urinaria; D: Macroscopic appearance of uroliths

oxyhemoglobin saturation [(O<sub>2</sub>Sat)].

Urine samples were taken with a sterile urinary catheter from all animals. Physical, chemical (color, turbidity, pH, blood, hemoglobin, protein) and microscopic analysis of the urine were performed. For microscopic analysis of the urine, a 5 ml urine sample was centrifuged at 1500 rpm for 5 minutes, and microscopic examinations were performed on the remaining precipitate. Microscopic examination evaluated erythrocyte, leucocyte, epithelial cells and crystals.

Radiographic and ultrasonographic examination were applied to cats and dogs without sedation or anesthesia. The radiographs were taken on a ventral dorsal, or lateral view (Figure 1A). The entire the ultrasonographic examination (8.0 MHz microconvex probe, Mylab 30-Esaote®, Genova, Italy), all parenchyma of the kidney was evaluated with the size, number, shape, and location of the calculi were determined (Figure 1B).

Urolithiasis was diagnosed and clinical, hematological through and biochemical analysis, as well as urine, radiographic and ultrasonographic examinations. Uroliths in the urinary bladder were removed by cystotomy (Figure 1C, D), and uroliths in the urethra were removed by urethrostomy or uro retropropulsion. Following the surgery, a chemical analysis was performed on the uroliths that were removed.

## Results

The data of animals related to the species, breed, gender and age information of the dogs and cats in this study are provided in Table 1.

Anamnesis, radiological and ultrasonographic examination findings, location of the stone, and chemical analysis of the stone are presented in Table 2. The blood results, biochemical analysis results (urea and creatinine

values), urine analysis findings and blood gas values are given in Tables 3, 4, 5 and 6 respectively.

## Discussion

On the diagnostic evaluation of lower urinary tract diseases in cats and dogs, a detailed medical history, physical and clinical examination, laboratory tests, and diagnostic imaging methods are not sufficient on their own, and sometimes all of them should be used (Alkan, 1999; Fossum et al., 2007; Grauser, 2009; Albasan et al., 2013; Sravanthi et al., 2014; Tion et al., 2015; Kamiloğlu and Kılıçoğlu, 2017; Tiruneh and Abdisa, 2017). Hematuria, stranguria, pollakiuria, and dysuria are commonly encountered clinical findings in small animal with lower urinary system disease. Systemic findings are not evident except in case of urinary tract ruptures and patients with obstruction. It is stated that stones in the urinary bladder results in cystitis by causing irritation on the bladder wall (Bumin and Temizsoylu, 2000; Fossum et al., 2007; Grauser, 2009; Lew-Kojrys et al., 2017; Parmar et al., 2021). The clinical findings of our cases were determined as hematuria, stranguria, pollakiuria and dysuria.

Direct radiography is the first step in the evaluation of the urinary system. Information can be obtained from the appearance, position, shape, size, and radiographic opacity of the urinary bladder. While the best radiographic position to view the urinary bladder is the right latero-lateral (L/L) position, it has been reported that the ventro-dorsal (VD) position causes the neck of the bladder not to be visualized due to the intestines, sacrum and vertebral column (Alkan, 1999; Ersöz, 2007; Arıcan, 2012). In our all cases, radiographic examination of the urinary bladder and urethra was performed in the lateral/lateral position. It has been reported that radiopaque stones larger than 1 mm in the urinary bladder and urethra can be detected by direct

**Table 1.** The species, breed, gender, and age information of the dogs and cats

Case No	Species	Breed	Age	Gender
1	Dog	Crossbreed	1 years	♀
2	Dog	Shih Tzu Terrier	2 years	♂
3	Dog	Dogo Argentino	9 years	♂
4	Dog	Golden Retriever	9.5 years	♀
5	Dog	Golden Retriever	11 years	♂
6	Dog	King Charles	4 years	♀
7	Dog	Crossbreed	12 years	♂
8	Dog	Crossbreed	3 years	♀
9	Cat	Tabby	6 years	♀
10	Dog	Crossbreed	8 years	♂
11	Cat	Crossbreed	2.5 years	♀
12	Cat	Crossbreed	1 year	♂
13	Dog	Terrier	9 years	♀
14	Cat	Crossbreed	8 years	♂
15	Cat	Crossbreed	5 years	♂
16	Cat	Crossbreed	8 years	♂
17	Cat	Siamese	7 years	♀

♀: Female ♂: Male

**Table 2.** The clinical, radiological and ultrasonographic examination findings of the cases with the location and the analysis results of the stone

Case No	Clinical Findings	Radiographic Examination Findings	Ultrasonographic Examination Findings	Location of the stone / Stone Analysis Results
1	Haematuria, Stranguria	Many radiopaque stones in the urethra	Thickening of the wall of the bladder	Urethra/Calcium carbonate stone
2	Stranguria	Urinary bladder very full, many radiopaque stones in the urethra	Urinary bladder in normal appearance	Urethra/Calcium carbonate stone
3	Stranguria, Haematuria	Radiopaque stone in the urinary bladder	Acoustic shadow distal to stone with hyperechoic appearance	Urinary bladder/Calcium carbonate stone
4	Haematuria, Stranguria	Two radiopaque stones in the urinary bladder	Acoustic shadow distal to stone with hyperechoic appearance	Urinary bladder/ Calcium carbonate and ammonium urate
5	Stranguria	Urinary bladder full, a single radiopaque stone in the urinary bladder	Acoustic shadow distal to stones with hyperechoic appearance	Urinary bladder/ Calcium oxalate phosphate
6	Haematuria	Urinary bladder full, two radiopaque stones in the urinary bladder	Acoustic shadow distal to stones with hyperechoic appearance	Urinary bladder calcium carbonate cystine
7	Haematuria, Stranguria	Urinary bladder very full, radiopaque stones in the urethra	Urinary bladder in normal appearance	Stone in the urethra Calcium carbonate stone
8	Haematuria	Two radiopaque stones in the urinary bladder	Acoustic shadow distal to stones with hyperechoic appearance	Urinary bladder Calcium carbonate
9	Haematuria	Seven small radiopaque stones in the urinary bladder	Acoustic shadow distal to stones with hyperechoic appearance	Urinary bladder/calcium carbonate phosphate stone
10	Haematuria	Two radiopaque stones in the urinary bladder	Acoustic shadow distal to stones with hyperechoic appearance	Urinary bladder Calcium carbonate stone
11	Haematuria, Stranguria	Radiopaque stones in urinary bladder	Acoustic shadow distal to stones with hyperechoic appearance	Urinary bladder Calcium carbonate and ammonium oxalate
12	Haematuria, Stranguria	Four radiopaque stones in the urinary bladder and five radiopaque stones in the urethra	Acoustic shadow distal to stone with hyperechoic appearance	Urethra and urinary bladder, Calcium carbonate stone
13	Haematuria, Stranguria	A small radiopaque stones in the urinary bladder	Acoustic shadow distal to stones with hyperechoic appearance	Urinary bladder Calcium carbonate stone
14	Haematuria, Stranguria	Radiopaque stones in urinary bladder and urethra	Acoustic shadow distal to stones with hyperechoic appearance	Urethra and urinary bladder/ Calcium oxalate stone
15	Haematuria, Stranguria	A single radiopaque stone in the urinary bladder	Acoustic shadow distal to stones with hyperechoic appearance	Urinary bladder Calcium carbonate stone
16	Haematuria, Stranguria	Three radiopaque stone in the urinary bladder	Acoustic shadow distal to stones with hyperechoic appearance	Urinarybladder/ Calcium oxalate stone
17	Haematuria, Stranguria	Five radiopaque stones in the urinary bladder	Acoustic shadow distal to stones with hyperechoic appearance	Urinary bladder Calcium oxalate stone

radiography, but the diagnosis of other urinary bladder diseases is difficult. In our study, direct radiographs were compatible with previous data and it was observed that the localization of radiopaque stones was urinary bladder (n=13), urethra(n=2), and urinary bladder with

urethra (n=2).

Ultrasonography is used in the evaluation of urinary system diseases because it is a painless examination scanning procedure; it does not require any contrast material, the examination time is short and the cost is

**Table 3.** Blood results of the cases

Case No	WBC x10 <sup>3</sup> / mm <sup>3</sup>	LYM x10 <sup>3</sup> / µL	MON x10 <sup>3</sup> / µL	NEU x10 <sup>3</sup> / µL	EOS x10 <sup>3</sup> / µL	BAS x10 <sup>3</sup> / µL	RBC (x10 <sup>6</sup> / µL	HGB g/dl	HCT %	MCV fl	MCH pg	MCHC g/dl	PLT /µL
1	30.81	4.18	1.61	24.97	0.04	0.01	7.31	13.2	45.64	62	18.1	30.6	153
2	31.13	2.96	0.91	27.20	0.05	0.02	6.46	16.2	47.24	73	25	34.2	368
3	16.24	1.74	0.71	13.75	0.02	0.01	6.73	14.5	46.89	70	21.5	30.9	431
4	9.21	3.68	0.66	4.49	0.28	0.09	6.83	15	49.45	72	21.9	30.2	349
5	8.11	1.83	0.18	6.06	0.02	0.01	8.78	18.2	53.11	60	20.8	34.3	372
6	34.83	2.61	1.60	30.41	0.17	0.05	9.44	20.6	69.66	74	21.8	29.6	231
7	19.77	0.65	1.73	17.27	0.08	0.04	8.24	19.2	52.04	62	22.7	36.9	567
8	12.75	3.01	0.38	9.27	0.06	0.03	6.38	16.7	50.02	78	26.1	33.4	494
9	5.89	4.10	0.19	1.38	0.23	0.00	6.58	11.6	38.57	59	17.6	30.1	248
10	27.04	1.68	0.62	24.72	0.02	0.00	6.33	15.0	44.21	70	23.7	33.9	145
11	5.75	1.99	0.11	3.41	0.20	0.01	9.92	14.9	43.22	44	15.1	34.6	300
12	22.79	5.04	1.12	16.61	0.02	0.00	10.97	19	56.33	51	173	33.7	397
13	1334	0.65	0.87	11.82	0.02	0.01	772	159	49.64	64	20.6	32.0	472
14	1299	149	071	1058	0.21	0.00	6.12	92	255	417	15.0	35.9	89
15	9.73	1.71	080	6.43	0.79	0.02	9.99	14.1	38.6	38.7	14.1	36.5	119
16	8.3	3.5	0.4	4.4	0.00	0.01	6.41	12.	35.3	55.1	19.1	34.8	395
17	25.1	11.1	1.9	12.1	0.05	0.00	7.11	14.2	38.3	53.9	19.9	37.0	73

WCC: White Blood Cell; LYM: Lymphocytes; MON: Monocytes; NEU: Neutrophils; EOS: Eosinophils; BAS: Basophils; RBC: Erythrocyte; HGB: Hemoglobin; HCT: Hematocrit; MCV: Mean corpuscular volume; MCH: Mean corpuscular hemoglobin; MCHC: Mean Corpuscular Hemoglobin Concentration; PLT: Trombosit.

**Table 4.** Urea and creatine values of the cases.

Case No	Urea mg/dl	Creatine mg/dl
1	27	0.5
2	357	6.52
3	15	0.7
4	38	1.5
5	1.3	17
6	17	0.5
7	46	0.9
8	38	0.96
9	30	1.4
10	17	1
11	40	2.1
12	70	6.1
13	87	2.1
14	140	9.85
15	24.9	1.93
16	24.5	3.34
17	20	1.6

low, the application is easy and has no contraindications; and it is a noninvasive method (Rinkardt and Houston, 2004; Sancak et al., 2009; Arican, 2012; Albasan et al., 2013; Tion et al., 2015; Tiruneh and Abdisa 2017). In our study, ultrasonographic examination was performed after the radiographic examinations. In healthy animals, the urinary bladder is an organ that can be easily evaluated by ultrasonography when it is full due to

the acoustic properties of the fluid it contains and its superficial location. When the bladder is full, it is round and pear-shaped, and the urine in its lumen is seen as anechoic. The wall of the full bladder is thin and regular; if the bladder is not full enough, the wall is thick and irregular. If there is no dilatation in the ureter, the entry point of the ureter into the urinary bladder is not seen. Inflammation, blood clots, uroliths, rupture and

**Table 5.** Urinary examination findings of the cases

Case No	Odor	Appearance	Leukocyte	Density	Blood	pH	Protein	Glucose	Ascorbic Acid	Microscopic Examination
1	Special	Turbid	+(3)	1.020	+(3)	5.5	-	-	-	Erythrocyte, crystals
2	Special	Turbid	+(3)	1.005	+(3)	5.5	+++ (3)	-	-	Erythrocyte, calcium crystals
3	Special	Turbid	0	1.020	+(2)	5	+++ (3)	-	+++ (5.6)	Erythrocyte, epithelial eruptions
4	Special	Turbid	+(3)	1.005	+(3)	8	0	+ 2	-	Epithelial eruptions
5	Special	Turbid	+(3)	1.005	+(3)	5.5	0	-	-	Calcium crystals, epithelial eruptions
6	Special	Turbid	+(3)	1.020	+(3)	7.5	+(4)	-	0.6	Erythrocyte, epithelial eruptions
7	Special	Turbid	0	1.030	+(3)	6	+(3)	-	-	Calcium crystals
8	Special	Turbid	0	1.020	+(3)	5	++ (2)	-	-	Erythrocyte, calcium crystals
9	Special	Turbid	+(3)	1.025	+(3)	5.5	++ (2)	-	-	Erythrocyte epithelial eruptions
10	Special	Turbid	+(3)	1.020	+(3)	5	++ (2)	-	-	Erythrocyte, epithelial eruptions
11	Special	Turbid	+(2)	1.025	+(3)	6	++ (2)	-	-	Erythrocyte, calcium crystals
12	Special	Turbid	+(3)	1.010	+(3)	5-6	++ (2)	-	-	Crystals
13	Special	Turbid	0	1.025	+(3)	6	++ (2)	-	-	Erythrocyte, epithelial eruptions
14	Special	Turbid	+(2)	1.005	+(3)	5.5	+++ (3)	-	-	Erythrocyte, epithelial eruptions
15	Special	Turbid	+(3)	1.020	+(3)	5.5	++ (2)	-	-	Erythrocyte, epithelial eruptions
16	Special	Turbid	+(3)	1.030	+(3)	7	+(1)	-	-	Erythrocyte, crystals
17	Special	Turbid	+(3)	1.020	+(3)	6	-	-	-	Erythrocyte, epithelial eruptions

tumors in the urinary bladder can be easily seen with ultrasonography. It has been reported that uroliths in the urinary bladder are observed as hyperechoic lesions and they create strong echoes with an acoustic shadow in their distal region, and uroliths in the urinary bladder fall on the lying side of the animal during ultrasonography examination. However, it has been reported that stones in the urethra are difficult to detect (Alkan, 1999; Ersöz, 2007; Eminağa, 2009; Arican, 2012). In this study, uroliths with a hyperechoic appearance, with an acoustic shadow in the distal part, are displaced when the patient is moved that were detected in the ultrasonography examination in cases with urinary bladder stones, depending on the

number and size of the stones.

In literature, the general condition of the patient should be corrected before surgical treatment is performed in animals with urolithiasis. It is reported that the most frequently applied method for the treatment of uroliths in the urinary bladder is cystotomy. It has been reported that the treatment of uroliths in the urethra is pushing the uroliths into the urinary bladder through catheterization or urohydropulsion, and when the uroliths cannot be pushed into the urinary bladder, urethrotomy can be applied (Smith, 1993; Bumin and Temizsoylu, 2000; Osborne et al., 2000). In this study,

**Table 6.** Blood gases values of the cases.

Case No	pH	pCO <sub>2</sub> (mmHg)	pO <sub>2</sub> (mmHg)	HCT (%)	Na <sup>+</sup> (mmol/L)	K (mmol/L)	Ca <sup>++</sup> (mmol/L)	HCO <sub>3</sub> (mmol/L)	O <sub>2</sub> Sat (%)
1	7.260	55	44	36.8	134.2	4.24	1.2	25	78
2	7.285	60.2	43.2	49.6	144.6	4.37	0.89	27.5	63
3	7.304	46.1	124.9	34.7	122.6	4.29	0.42	22.7	98
4	7.265	43.1	40.2	51.7	153.3	4.06	1.58	18.9	58.7
6	7.384	44.6	66.1	52.9	156.4	3.75	0.89	25.7	89.3
11	7.278	39.5	44.1	44.4	153.5	4.86	1.07	17.9	66.6
12	7.110	53.7	54.8	60	149	3.33	1.21	16.1	76
13	7.202	46.8	41.3	46.9	124	5.12	1.32	17.8	56.7

pCO<sub>2</sub>: Partial pressure of carbon dioxide; pO<sub>2</sub>: Partial pressure of oxygen; HCT: Hematocrit; Na: Sodium; Ca<sup>++</sup>: Ionized calcium; K: Potassium; HCO<sub>3</sub>: Bicarbonate concentration; O<sub>2</sub>Sat: oxygen saturation

urethrotomy was performed in 2 of the 4 cases with the urolith in the urethra, and cystotomy was performed in 2 cases by pushing the stones in the urethra into the urinary bladder with uroretropropulsion. In these cases, uroliths were removed from the urinary bladder by performing a cystotomy in a total of 15 cases.

Azotemia is defined as an increase in the blood concentrations of non-protein nitrogenous compounds. Examples of non-protein nitrogenous substances are urea and creatinine, and these parameters are often measured to assess the excretory function of the kidney. An elevation of either BUN or creatinine is sufficient to qualify as azotemia (Grause, 2005; Lunn, 2011). Although the causes of azotemia show individual differences in some diseases, in general, the stages are easily separated from each other. The causes of azotemia are divided into prerenal, renal and postrenal. Postrenal causes are divided into urethral obstruction, urinary bladder ruptures, and urolithiasis (Langston, 2008). When the urea and creatinine values of the cases in our study were examined, azotemia was observed in 7 cases. We thought that this was post-renal origin due to urolithiasis.

Proteinuria is defined as the presence of protein in the urine. Under normal conditions, very small levels of protein can be found in the urine (Bilal, 2013). When the classification and causes of protein product are examined, it is divided into prerenal, renal and postrenal. As a result of the inflammatory and degenerative disorders of the urogenital canal distal to the kidneys, protein accumulates in the urine and creates a post-renal proteinuria (Harley and Langston, 2012). Since the clinical symptoms are usually directly related to the lower urinary tract, the diagnosis of the disease is easy. Ureters, bladder, prostate or urethra are highly affected by these lesions. Post-renal proteinuria may also occur as a result of inflammatory and degenerative disorders such as cystitis, urogenital duct tumor, and urolithiasis (Barber 1996; Kocabaş and Başol, 2006). We thought that the cause of the proteinuria formed as a result of the examinations performed in our study was of postrenal origin.

Hematuria is the presence of excessive amounts of erythrocytes in the urine. Hematuria can occur in any case where the urogenital system mucosa or vascular

structure is affected. The most important causes of hematuria are infection, inflammation, neoplasia, trauma, vascular diseases and coagulopathies (Turgut, 2000). We thought that the reason of hematuria observed in cases of our study is due to trauma caused by uroliths in the urinary bladder.

It has been reported that an increase in the number of epithelial cells, detected in the examination of urine sediment, which has an important place in urine analysis, is associated with inflammation or infection on the upper or lower urinary tract (Turgut, 2000). In this study, too many erythrocytes, leukocytes and epithelial cells were found in the urine sediment examination.

Magnesium ammonium phosphate (struvite), calcium oxalate, and urate uroliths have been reported as the most frequently observed uroliths in dogs. While struvite and calcium oxalate stones were the most common bladder stones in cats, ammonium urate, cysteine and silicate uroliths have been found less in research (Forrester and Roudebush, 2007; Sancak et al., 2009). In our study, calcium oxalate stones were seen in cats and dogs mostly.

### Conclusion

As a result, since lower urinary tract diseases are very common in dogs and cats, and the clinical symptoms observed are very similar to each other, radiographic and ultrasonographic diagnostic methods should be used in addition to the clinical and laboratory diagnostic methods for the definitive diagnosis of these diseases. Additionally, chemical analysis of the stone should be performed to determine the treatment process. As a result of the chemical analysis, the most calcium carbonate stone was determined. These stones are not amenable to medical dissolution; therefore, they were surgically removed to treat uroliths.

### Acknowledgements

This study supported by Aydın Adnan Menderes University, Scientific Research Foundation (Project No: VTF-18014). The author would like to thank Aydın Adnan Menderes University for their support.

## Conflict of interest

The authors declare that they have no conflict of interest.

## References

- Albasan, H., Osborne, C.A, Lulich, J.P., & Sancak, A.A. (2013). Köpek ve kedilerde ürolitiazis. *Türkiye Klinikleri Journal Veterinary Sciences*, 4(2), 39-52.
- Alkan, Z. (1999). *Veteriner Radyoloji* (1st ed.). Mina Ajans Matbaacılık, Ankara.
- Arıcan, M. (2012). *Veteriner Genel Radyoloji ve Kedi Köpek İçin Tanısal Radyografi Atlası Cilt II* (1st ed.). Bahçivanlar Basım Sanayi A.Ş., Konya.
- Barber, P.J. (1996). Proteinuria. In J. Bainbridge & J. Elliott (Eds), *Manual of Canine and Feline Nephrology and Urology*. Gloucestershire: British Small Animal Veterinary Association (BSAVA).
- Bilal, T. (2013). *Kedi ve Köpeklerde İç Hastalıkları* (1st ed.). Nobel Kitabevi, İstanbul.
- Bumin, A., & Temizsoylu, D. (2000). Köpeklerde idrar kesesi taşlarının radyografik ve ultrasonografik tanısı ve şırıjikal sağaltımı. *Ankara Üniversitesi Veteriner Fakültesi Dergisi*, 47(02), 213-221.
- Eminağa, B. (2009). *Köpeklerde alt üriner sistemin cerrahi hastalıklarının radyografik ultrasonografik tanısı ve cerrahi sağaltımı*. [Yüksek Lisans Tezi, Ankara Üniversitesi Sağlık Bilimleri Enstitüsü]. Ankara.
- Ersöz, P. (2007). *Kedi ve köpeklerde idrar kesesi hastalıklarının ultrasonografik muayenesi*. [Yüksek lisans tezi, Ankara Üniversitesi Sağlık Bilimleri Enstitüsü]. Ankara.
- Forrester, D.S., & Roudebush, P. (2007). Evidence based nutritional management of feline lower urinary tract disease. *Veterinary Clinics North America: Small Animal Practice*, 37(3), 533-58.
- Fossum, T.W., Hedlund, C.S., & Johnson, A.L. (2007). *Small Animal Surgery*. (3rd ed.). Missouri, Mosby-Elsevier.
- Grauer, G. (2005). Early detection of renal damage and disease in dogs and cats. *Veterinary Clinics: North Small Animal Practice*, 35, 581-596.
- Grauser, G.F. (2009). Feline Lower Urinary Tract Disease In Nelson R.W, & CG Couto (4th ed.). *Small Animal Internal Medicine*. (pp.677-683). Elsevier.
- Harley, L., & Langston, C. (2012). Proteinuria in dogs and cats. *The Canadian Veterinary Journal*, 53(6), 631.
- Houston, D.M., & Moore, A.P.E. (2009). Canine and feline urolithiasis: Examination of over 50 000 urolith submissions to the Canadian Veterinary Urolith Centre from 1998 to 2008. *The Canadian Veterinary Journal*, 50(12), 1263-1268.
- Kamiloğlu, A., & Kılıçoğlu, D. (2017). Kedilerde alt üriner sistem ürolitiazisinin klinik, laboratuvar, radyografik, ultrasonografik tanısı ve cerrahi sağaltım: çalışma on kedi üzerinde yapıldı. *Atatürk Üniversitesi Veteriner Bilimleri Dergisi*, 12(1), 14-21.
- Kaya, M. (1998). Ürogenital Sistem Hastalıkları. In İmren H.Y (Eds.), *Kedi ve Köpek Hastalıkları* (pp. 621-655). Medisan, Ankara,
- Kocabaş, R.N., & Başol, G. (2006). Proteinüri ve laboratuvar değerlendirilmesi. *Türk Klinik Biyokimya Dergisi*, 4(3), 133-145.
- Langston, C. (2008). Managing fluid and electrolyte disorders in renal failure. *Veterinary Clinics North America: Small Animal Practice*, 38(3), 677-697. <https://doi.org/10.1016/j.cvsm.2008.01.007>
- Lew-Kojrys, S., Mikulska-Skupien, E., Snarska, A., Krystkiewicz, W., & Pomianowski, A. (2017). Evaluation of clinical signs and causes of lower urinary tract disease in polish cats. *Veterinarni Medicina*, 62(7), 386-393. <https://doi.org/10.17221/170/2016-VETMED>
- Lunn, K.F. (2011). The kidney in critically ill small animals. *Veterinary Clinics: Small Animal Practice*, 41(4), 727-744. <https://doi.org/10.1016/j.cvsm.2011.03.020>
- Nelson, R.W, & Couto, C.G. (2014). *Small Animal Internal Medicine*. (5th ed). St. Louis, Mo, Elsevier.
- Osborne, C.A., Kruger, J.M., Lulich, J.P., Polzin, D.J. & Lekcharoensuk, C. (2000). Feline lower urinary tract disorders. In S. J. Ettinger, & E. C. Feldman (Eds.), *Textbook of Veterinary Internal Medicine* (pp.1710-1747). W.B. Saunders Company, Philadelphia.
- Parmar, J.J., Parikh, P.V., Pancha, I.M.T., Dabhi, P.B., Kelawala, D.N., & Mhala, J.K. (2021). Study on various affections of lower urinary tract in dogs.. *The Pharma Innovation Journal*, 10(2), 209-214. <https://doi.org/10.22271/tpi.2021.v10.i2Sd.5736>
- Polat, E., & Sağlıyan, A. (2022). Clinical, radiographic, ultrasonographic diagnosis, and treatment of urolithiasis in two domestic cats-case report. *Veterinary Journal of Kastamonu University*, 1(1), 34-41.
- Rinkardt, N.E., & Houston, D.M. (2004). Dissolution of infection-induced struvite bladder stones by using a noncalculolytic diet and antibiotic therapy. *The Canadian Veterinary Journal*, 45, 838-840.
- Sancak, İ.G., Özgencil, F.E., & Sancak, A. A. (2009). Fakülte kliniklerine gelen (2002-2003) kedi ve köpeklerde ürolitiazis olgularının klinik değerlendirilmesi. *Ankara Üniversitesi Veteriner Fakültesi Dergisi*, 56, 105-111.
- Sravanthi, P., Sekhar, E.L.C., Raghavender, K.B.P., Pramod, Kumar, D., & Kumar V.G. (2014). Haemato-biochemical and imaging studies for diagnosis of urolithiasis in dogs. *International Journal of Agricultural Sciences and Veterinary Medicine*, 2(3), 60-65.
- Smith, C.W. (1993). Surgical Diseases of Urethra In D. Slatter (Eds), *Textbook of small Animal Surgery*, (pp. 1462-1473). WB Saunders Company,
- Tion, M.T., Dvorska, J., & Saganuwan, S.A. (2015). A review on urolithiasis in dogs and cats. *Bulgarian Journal of Veterinary Medicine*, 18(1), 1-18.
- Tiruneh, D., & Abdisa, T. (2017). Review on canine urolithiasis. *American Research Journal of Veterinary Medicine*, 1(1), 1-7.
- Turgut, K. (200). *Veteriner Klinik Laboratuvar Teşhis* (1st ed.). Bahçivanlar, Konya.