

An unusual foreign body in the midesophagus of an adolescent boy retrieved successfully via a snare with a net

Ergen erkek çocukta orta özofagusta alışılmamış bir yabancı cisim: fileli kement ile başarılı endoskopik çıkarımı

Burcu GÜVEN, Hacer Fulya GÜLERMAN

Department of Pediatric Gastroenterology, Kırıkkale University School of Medicine, Kırıkkale

Foreign body ingestion is a common problem in the pediatric population. Most of these objects pass through the intestinal tract without difficulty; however, due to size or shape, many will become lodged in the esophagus. Sharp and serrated bodies are more dangerous than smooth ones because of the risk of esophageal perforation. We report an accidentally swallowed carbonated drink bottle cap with a peripherally serrated rim by an adolescent, which was removed endoscopically from the midesophagus via a snare with a net, without any damage. Using flexible endoscopy, a wide variety of instruments is suitable for removing foreign bodies. A snare with a net may be a safe and effective option in the pediatric population.

Anahtar kelimeler: Foreign body, esophagus, pediatric, endoscopic snare

INTRODUCTION

Foreign body ingestion is a common problem in the pediatric population. When compared with adults, 98% of foreign body ingestion in children is accidental and involves common objects found in the home environment, such as coins, toys, jewelry, magnets, and batteries (1).

Most ingested objects pass through the gastrointestinal tract without any complication. Foreign bodies might cause severe injuries because of their characteristic features or because of the level at which they became lodged. Extraction of an object lodged in the esophagus is usually achieved endoscopically, with less than 1% of cases requiring surgical intervention for removal (2).

Herein, we report a rare case of an accidentally swallowed carbonated drink bottle cap with a peripherally serrated rim in the esophagus, removed endoscopically via a snare with a net, without any damage.

CASE REPORT

A 16-year-old boy was admitted to the emergency department for dysphagia and chest pain. He stated that the cap of a carbonated drink bottle had blown off of the bottle's mouth and down his throat simultaneously while he tried to open it

Çocuklarda yabancı cisim yutulması sık karşılaşılan bir sorundur. Bu cisimlerin çoğu bağırsak yoluna kolaylıkla geçer, ancak bazıları büyüklük ya da şekline bağlı olarak özofagusta kalır. Keskin ve tırtıklı kenarı olan yabancı cisimler özofagusu perforate etme riskinden dolayı daha çok risk taşırlar. Biz burada kaza sonucu kenarı tırtıklı gazoz kapağı yutan bir ergende bu cismin endoskopik olarak fileli kement ile hasarsız olarak orta özofagustan çıkarımını bildiriyoruz. Fleksibl endoskoplar ile çok sayıda seçenek kullanılarak yabancı cisimler çıkarılabilmektedir. Bu seçeneklerden fileli kement uygulaması da çocuklarda güvenli ve etkin bir seçenek olarak görülmektedir.

Key words: Yabancı cisim, özofagus, çocuk, endoskopik kement

with his teeth. At admission, his blood pressure was 110/70 mm Hg, respiratory rate was 16 breaths/min, and saturation in room air was 95%. His physical examination was unremarkable. Chest radiography revealed the bottle cap as a circular radio-opaque shadow with a peripherally serrated rim (Figure 1). In upper gastrointestinal endoscopy, the bottle cap was observed in the midesophagus and removed by a snare with a net (Figures 2,3).

He was observed 12 hours after the operation. The control chest radiography was normal (Figure 4), and he had no difficulty in swallowing.

DISCUSSION

Foreign body ingestion in children is one of the most common presentations for the pediatric emergency department. It is assumed that up to 40% of ingestions may go unnoticed (3). They most frequently occur in children between six months and four years of age. Foreign bodies that are commonly ingested tend to be everyday objects, including coins, pins, toys, foods, batteries, and magnets (4). Most of these objects pass through the intestinal tract without difficulty; however, due to their size or shape, many will become lodged

Güven B, Gülerman HF. An unusual foreign body in the midesophagus of an adolescent boy retrieved successfully via a snare with a net. *Endoscopy Gastrointestinal* 2017;25:44-46.

DOI: 10.17940/endoskopi.339856

Correspondence: Hacer Fulya GÜLERMAN

Department of Pediatric Gastroenterology,

Kırıkkale University School of Medicine, Kırıkkale

E-mail: fulya.gulerman@gmail.com • Phone: +90 318 225 24 85

Manuscript Received: 23.08.2017 Accepted: 28.08.2017

in the esophagus. Children may present with symptoms such as stridor, pain, drooling, fussiness, chest pain, respiratory distress, abdominal pain, fever, and refusal to eat.

Objects with sharp edges are especially dangerous because of their ability to perforate the esophagus and other structures. Esophageal perforation is a life-threatening injury requiring urgent management, which is associated with high morbidity and mortality. A bottle cap is a rare foreign body to be lodged in the esophagus. Due to the risk of injury because of the sharply serrated rims of the cap in our case, we planned to remove it immediately with flexible endoscopy.

On the other hand, an explosion of the bottle may occur when patients remove the cap of a carbonated drink bottle with their teeth (5). Bottle explosion is one of the etiologic agents of barotraumas in the aerodigestive tract and causes mucosal

perforation. High air pressure is introduced into the potential space of head and neck. It may cause damage to both deeper structures and the mediastinum such as laceration of the oral cavity, pharynx, and esophageal soft tissues, cervical emphysema, pneumothorax, and pneumomediastinum (5). For our patient, the explosion of the bottle did not occur, fortunately, and the cap of the bottle was removed without complication.

In conclusion, foreign body ingestion is a common problem in the pediatric population. Most foreign bodies are usually free of complications, but sharp or serrated bodies are not and are frequently associated with serious complications. With flexible endoscopy, a wide variety of instruments is suitable for removing foreign bodies by an experienced endoscopist. A snare with a net can be considered as a safe and effective option for use in the pediatric population.

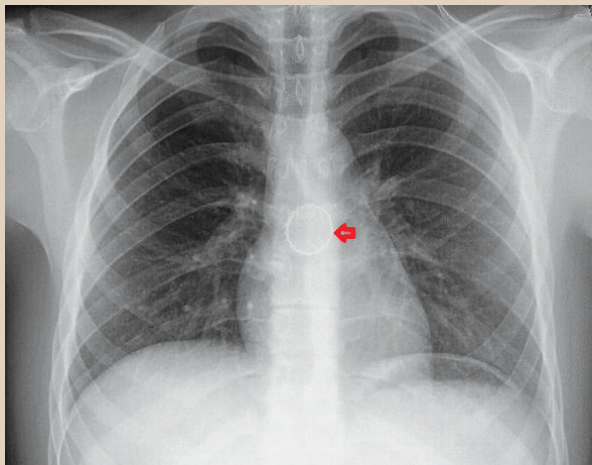


Figure 1. Chest radiography revealing the bottle cap as a circular radio-opaque shadow with a peripherally serrated rim.



Figure 3. The bottle cap with a peripherally serrated rim.

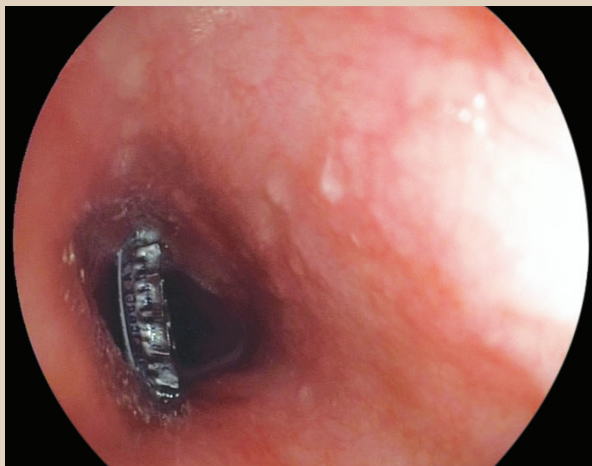


Figure 2. Endoscopic image of bottle cap lodged in the midesophagus.

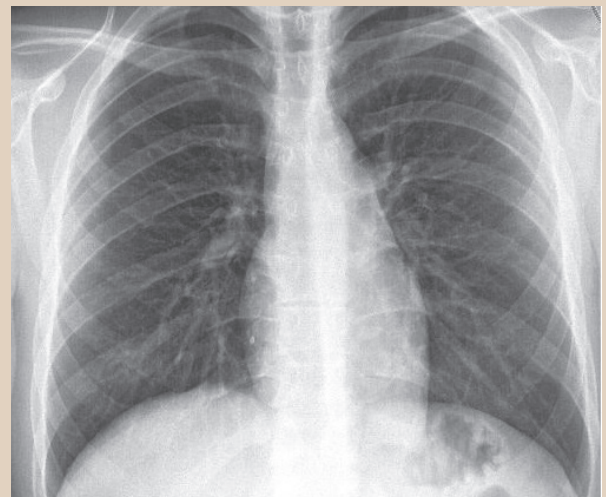


Figure 4. Control chest radiograph after the operation.

REFERENCES

1. Arana A, Hauser B, Hachimi-Idrissi S, et al. Management of ingested foreign bodies in childhood and review of the literature. *Eur J Pediatr* 2001;160:468-72.
2. Eisen GM, Baron TH, Dominitz JA, et al. Guideline for the management of ingested foreign bodies. *Gastrointest Endosc* 2002;55:802-6.
3. Paul SP, Hawes D, Taylor TM. Foreign body ingestion in children: case series, review of the literature and guidelines on minimising accidental ingestions. *J Fam Health Care* 2010;20:200-4.
4. Kramer RE, Lerner DG, Lin T, et al. Management of ingested foreign bodies in children: a clinical report of the NASPGHAN Endoscopy Committee. *J Pediatr Gastroenterol Nutr* 2015;60:562-74.
5. Lee JK, Lim SC. Barotraumatic perforation of pharyngoesophagus by explosion of a bottle into the mouth. *Yonsei Med J* 2005;46:724-8.