



## Spontaneous Pneumomediastinum After Playing Volleyball: A Case Report

### Voleybol Oynadıktan Sonra Gelişen Spontan Pnömomediastinum: Olgu Sunumu

Emre Bülbül<sup>1</sup>, İbrahim Toker<sup>2</sup>, Beyhan Koray<sup>2</sup>, Levent Ceyhan<sup>3</sup>, Mehmet Karakuş<sup>4</sup>

<sup>1</sup>Erciyes University Faculty of Medicine, Department of Emergency Medicine, Kayseri, Turkey

<sup>2</sup>Kayseri City Training and Research Hospital, Department of Emergency Medicine, Kayseri, Turkey

<sup>3</sup>Private Practice in Kayseri, Kayseri, Turkey

<sup>4</sup>Adana Demirspor Football Club, Sports Physician, Adana, Turkey

#### ÖZET

*Pnömomediastinum spontan ve travmaya bağlı nedenler sonucu mediastende hava bulunması olarak isimlendirilmektedir. Bu olguda voleybol oynadıktan sonra başlayan boyun ağrısı şikayeti ile acil servise gelen ve spontan pnömomediastinum saptanan 18 yaşında bir erkek hasta sunuyoruz. Hastaneye yatırılan hastaya konservatif tedavi uygulanmıştır. Klinik ve radyolojik olarak iyileşen hasta takip önerilerek taburcu edilmiştir.*

**Anahtar Kelimeler:** Pnömomediastinum, mediastinal amfizem, voleybol

#### ABSTRACT

*Pneumomediastinum is the presence of air in the mediastinum due to spontaneous and traumatic reasons. In this case, we present an 18 year old male patient with spontaneous pneumomediastinum who came to the emergency department with neck pain after playing volleyball. The patient was admitted to the hospital, and conservative treatment was applied. He recovered clinically and radiologically and was discharged with follow-up advice.*

**Keywords:** Pneumomediastinum, mediastinal emphysema, volleyball

#### INTRODUCTION

Pneumomediastinum can be named air in the mediastinum due to spontaneous and traumatic causes in the chest. This situation can have serious consequences (1). It was first defined as posttraumatic by Laennec in 1819 and later proved by Hamman in 1839 that it could develop spontaneously. The reasons may be various. It is generally divided into two main groups according to the type of occurrence. The first is the primary form that develops spontaneously, and the second is the secondary form that develops due to trauma, etc. Although clinically, it is generally silent, sometimes shortness of breath, chest pain, etc. It may present with symptoms and cause severe and life-threatening consequences (2,3).

The pneumomediastinum pathophysiology can be defined as the alveoli's rupture due to increased intra-alveolar pressure by the rise in intrathoracic pressure. It is even possible to enter the diaphragm and retroperitoneal area. In some cases, pneumopericardium, pneumothorax, and subcutaneous emphysema may be seen (4,5).

#### CASE REPORT

The 18-year-old patient applied with neck pain that started after playing volleyball in the morning hours. He had no complaints, such as shortness of breath and chest pain. He had not injured while playing volleyball. He had no illness, no operation, and no medication.

In the patient's vitals, blood pressure was 100/60 mmHg, respiratory rate was 20/minute, heart rate was 80/minute, and body temperature was 36.7 °C. The patient's oxygen-free saturation was measured as 98 by the finger-type oximeter. Oriente, cooperative, Glasgow coma score of 15, respiratory sounds were natural, S1 + S2 + additional sounds, and murmur was absent in heart sounds. The abdominal examination of the patient was regular.

He had crepitation in the neck. The cervical and chest X-ray was performed, and air density was in front of the cervical vertebrae (Figure 1a, 1b, 2). Then, thorax tomography was performed. The air in the para-tracheal region was observed Figure 3. And no rib fractures or pneumothorax were detected.

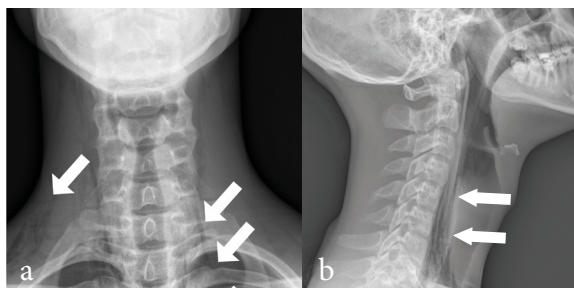
**Corresponding Author:** İbrahim Toker, Kayseri City Hospital, Department of Emergency Medicine, Kayseri, Turkey.  
**email:** ibrahimtoker9@gmail.com

**Cite this article as:** Bülbül E, Toker İ, Koray B, Ceyhan L, Karakuş M. Spontaneous Pneumomediastinum After Playing Volleyball: A Case Report JAMER 2023;8(4)77-9.

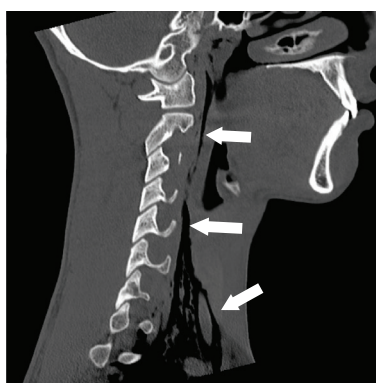
**Received:** 26.10.2023

**Accepted:** 09.11.2023

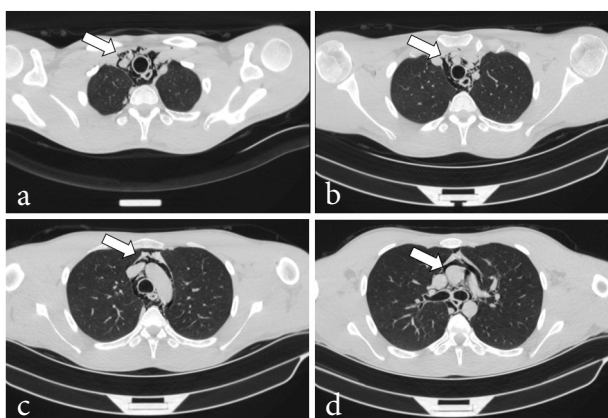
**Online Published:** 05.12.2023



**Figure 1** a. AP cervical X-ray; airlines in lateral of the cervical vertebrae (arrows) b . Lateral cervical vertebrae X-ray shows airline in front of prevertebral space (arrows).



**Figure 2.** Cervical computed tomography shows air density in front of the cervical vertebra (arrows).



**Figure 3. a-d.** Thorax tomography shows the air in the paratracheal region and upper mediastinum, and no rib fractures or pneumothorax (arrows).

The patient had 16.000 neutrophil-dominated white cells in the complete blood count, and there was no pathology in hemoglobin value and biochemical parameters.

The patient was consulted with the pediatric surgeon. No pathology was detected in the endoscopy and bronchoscopy. Oral intake was opened during the follow-up, and the patient was relieved clinically and showed improvement in radiological imaging. He was discharged and called for a follow-up.

## DISCUSSION

The incidence of spontaneous pneumomediastinum is uncommon. However, it is relatively more common (about 3%) in pediatric ages. Besides, the incidence is high among patients with asthma, tall and slender, between the ages of 20 and 40, and sports that increase thoracic pressure, such as underwater diving and weight lifting. The air in the subcutaneous tissues is not pathognomonic for pneumomediastinum but raises clinical suspicion (5,6). Indeed, the most crucial finding in our case was crepitation in the neck region on physical examination.

Approximately 70-90% of the factors that cause pneumomediastinum are the causes that can be determined. These include pushing (waltz maneuver), some drugs, excessive vomiting, underwater diving and paragliding, sports aviation movements such as sail wing jumping, free parachute jumping, intense cough, asthma, bronchiectasis, inhalant inhalation, loud yelling, labor, convulsion, bronchiolitis, foreign body aspiration, laryngotracheitis, intubation, mechanical ventilation, endoscopy (5,7,8). Our case featured the first case reported in the literature due to its development after playing volleyball.

The clinic in pneumomediastinum patients is very variable. The most common symptoms are neck pain, chest pain, difficulty and pain in swallowing, hoarseness, voice change, crackling sound, shortness of breath, tachypnea, chest pain, restlessness, cyanosis, back pain, and cough. The presence of fever should suggest a complication such as mediastinitis. Regarding hypotension, shortness of breath, chest pain, respiratory distress, and tachypnea, pneumothorax should be considered (9–11).

Although erect and lateral chest X-rays are sufficient for diagnosing the disease radiologically, a cervical X-ray may sometimes be required. In literature, the chest X-ray may be false negative in up to 10 percent of cases (12,13). Computed tomography is accepted as the gold standard for diagnosing pneumomediastinum. It is strongly recommended for differential diagnosis and defining complications (14,15). Endoscopy is helpful for suspicion or differential diagnosis of esophageal perforation. Electrocardiography is also recommended for differential diagnosis (5).

A conservative approach should be preferred if there is no cardiopulmonary instability. An excellent recovery is seen in pneumomediastinum cases not accompanied by diseases such as infection and esophageal rupture. It should be monitored by daily physical examination during the treatment. Clinically stable patients can be called for control and discharged after being observed for at least 24-36 hours. Patients can be given 100% O<sub>2</sub> if they have oxygen starvation (9,16,17). Oral intake should be stopped until the esophageal injury is excluded. Conservative treatment was also preferred in our patient. Micro-drainage may be needed in patients with excessive subcutaneous emphyse-

ma (approximately 1.1%). The tube thoracostomy is required in cases accompanied by pneumothorax. Compressed massage is also beneficial. Although antibiotic treatment is frequently used in prevention, the authors have no consensus (5,18).

**Informed Consent:** Written informed consent was obtained from the patient.

**Conflict of Interest:** The authors have no conflicts of interest to declare.

**Financial Disclosure:** None.

## REFERENCES

1. Caceres M, Ali SZ, Braud R, Weiman D, Garrett HE. Spontaneous pneumomediastinum: a comparative study and review of the literature. *Ann Thorac Surg.* 2008 Sep;86(3):962–6.
2. Demirel A, Aynacı E, Özgül MA, Özgül G, Uysal MA. Primer spontan pnömomediastinum. 2008 Apr 1;10(1):71–3.
3. Langwieler TE, Steffani KD, Bogoevski DP, Mann O, Izbicki JR. Spontaneous pneumomediastinum. *Ann Thorac Surg.* 2004 Aug;78(2):711–3.
4. Macklin CC. Transport of air along sheaths of pulmonary blood vessels from alveoli to mediastinum: Clinical implications. *Arch Intern Med.* 1939 Nov 1;64(5):913–26.
5. Tözüm H, Eren TŞ. Primer spontan pnömomediastin. In Balcı AE, Editor. *Mediyasten hastalıkları ve cerrahisi.* Editör: Balcı AE, TÜSAD Eğitim Kitapları Serisi. 2015. p.145-50.
6. Stack AM, Caputo GL. Pneumomediastinum in childhood asthma. *Pediatr Emerg Care.* 1996 Apr;12(2):98–101.
7. Al-Mufarrej F, Badar J, Gharagozloo F, Tempesta B, Strother E, Margolis M. Spontaneous pneumomediastinum: diagnostic and therapeutic interventions. *J Cardiothorac Surg.* 2008 Nov 3;3:59.
8. Damore DT, Dayan PS. Medical causes of pneumomediastinum in children. *Clin Pediatr (Phila).* 2001 Feb;40(2):87–91.
9. Newcomb AE, Clarke CP. Spontaneous pneumomediastinum: a benign curiosity or a significant problem? *Chest.* 2005 Nov;128(5):3298–302.
10. Brand M, Bizos DB, Burnell L. A review of non-obstetric spontaneous pneumomediastinum and subcutaneous emphysema. *South Afr J Surg Suid-Afr Tydskr Vir Chir.* 2011 Aug 31;49(3):135–6.
11. Ryoo JY. Clinical analysis of spontaneous pneumomediastinum. *Tuberc Respir Dis.* 2012 Sep;73(3):169–73.
12. Fujiwara T. Pneumomediastinum in pulmonary fibrosis. Detection by computed tomography. *Chest.* 1993 Jul;104(1):44–6.
13. Kaneki T, Kubo K, Kawashima A, Koizumi T, Sekiguchi M, Sone S. Spontaneous pneumomediastinum in 33 patients: yield of chest computed tomography for the diagnosis of the mild type. *Respir Int Rev Thorac Dis.* 2000;67(4):408–11.
14. Ho AS, Ahmed A, Huang JS, Menias CO, Bhalla S. Multidetector computed tomography of spontaneous versus secondary pneumomediastinum in 89 patients: can multidetector computed tomography be used to reliably distinguish between the 2 entities? *J Thorac Imaging.* 2012 Mar;27(2):85–92.
15. Zylak CM, Standen JR, Barnes GR, Zylak CJ. Pneumomediastinum revisited. *Radiogr Rev Publ Radiol Soc N Am Inc.* 2000;20(4):1043–57.
16. Dur A. Güreş sonrası gelişen spontan pnömomediastinum. *Selçuk Tıp Derg.* 2012 Apr 17;29(4):182–3.
17. Adadioğlu İ, Yavuz Y, Solak O, Yürümez Y, Esme H. Primary spontaneous pneumomediastinum: Case Report. *J Emerg Med Case Rep.* 2010 Jan 1;1(1):37–40.
18. Leo F, Solli P, Veronesi G, Spaggiari L, Pastorino U. Efficacy of microdrainage in severe subcutaneous emphysema. *Chest.* 2002 Oct;122(4):1498–9.