

Lateral Rectus Palsy Caused by Herpes Zoster Ophthalmicus

Herpes Zoster Ophthalmicus ile Oluşan Lateral Rectus Palsisi

Ibrahim Özdemir¹, Ayla Eren Özdemir², Hüseyin Murat Bulut³, Süleyman Cagan Efe⁴

¹ Department of Ophthalmology, Agri State Hospital, Agri, Turkey.

² Sakarya University, Vocational School of Health Services, Sakarya.

³ Department of Dermatology, Agri State Hospital, Agri, Turkey.

⁴ Department of Cardiology, Agri State Hospital, Agri, Turkey

Özdemir I, Özdemir Eren A, Bulut HM, Efe SC. Lateral Rectus Palsy Caused by Herpes Zoster Ophthalmicus. J Biotechnol and Strategic Health Res. 2017;2:60-63

Abstract

Background Acquired abducens nerve palsy presents with horizontal diplopia which has a vary of differential diagnosis. Lateral rectus palsy caused by herpes simplex ophthalmicus (HZO) is a transient and self-limiting condition. A 65 year-old woman presents with double vision and headache. On examination vesicular lesions in left eye with abduction limitation are observed and treated by valacyclovir. In isolated abducens nerve palsy, skin lesions especially vesicular rash should be questioned. One should keep in mind that acquired horizontal diplopia may present following HZO.

Key words: Herpes Virus, Herpes Zoster, Sixth Nerve Palsy, Diplopia, Lateral Rectus Palsy

Özet

Giriş: Kazanılmış abducens siniri felci horizontal diplopi ile kendini gösterir. Herpes simplex ophthalmicus kazanılmış abducens siniri felcinin nadir görülen ama önemli sebeplerinden biridir; kendi kendini sınırlayan ve geçici özellikte olmasıyla diğer sebeplerden ayrılabilir. 65 yaşında kadın hasta, yeni ortaya çıkan çift görme ve baş ağrısı şikayeti ile polikliniğe başvurmuştur. Muayenesinde sol göz çevresinde veziküler döküntü ve dışa bakış kısıtlılığı mevcuttur. Valasiklovir ile tedavi edilmiştir. Bu tip olgularda cilt lezyonu özellikle veziküler döküntü sorgulanmalıdır. Ancak Herpes simplex'e bağlı abducens felcinin döküntünün kaybolmasından çok daha sonra da ortaya çıkabileceği unutulmamalıdır.

Anahtar kelimeler: Herpes Virüs, Herpes Zoster, Altıncı Sinir Felci, Diplopi, Dış Rectus Felci



Geliş Tarihi / Received : 23.07.2017

Kabul Tarihi / Accepted : 22.08.2017

*Corresponding Author:

Dr. Ibrahim Özdemir
Yenikent Devlet Hastanesi Göz Polikliniği,
Karaman, Sakarya.

E-mail: dr.ibrahimozdemir@gmail.com

Introduction

Isolated non-traumatic abducens nerve palsy (ANP) is the most common motor cranial neuropathy in the elderly population. Neoplastic, microvascular (mainly diabetic) and macrovascular diseases are the most common causes.¹ Herpes zoster ophthalmicus (HZO) is a rare cause of ANP.² Herpes zoster ophthalmicus (HZO) is the infection of the ophthalmic division of the trigeminal nerve by varicella-zoster virus (VZV).³ HZO can cause a variety of ocular manifestations.⁴ Extraocular muscle palsy occurs in 7-31% in HZO.⁵ In this case report, a case of HZO complicated by sixth nerve palsy is presented with a discussion of differential diagnosis.

Case report

A 65-year-old woman presented with headache, painful eruptions on her left superior eyelid and nose, double vision and nausea. Initially, she noticed skin lesions and felt pain, with diplopia has occurring later. She has no medical history of diabetic mellitus, hypertension, coronary artery disease or any vascular disease. On physical examination, crusted vesicular erythematous eruptions on the left superior eyelid and vesiculo-pustulous eruptions on the nasolabial sulcus were observed. She had limited abduction in left eye (Figure-1). She had minimal ptosis without anisocoria and both eyes were orthophoric in the primary gaze. Visual acuity was 10/10 in right eye and 9/10 in the left eye. In the slit-lamb examination, conjunctiva was mildly hyperemic with superior superficial punctuate keratitis. Fundus examination was normal bilaterally. The intraocular pressure was 13 mmHg in the right eye and 15 mmHg in left eye.

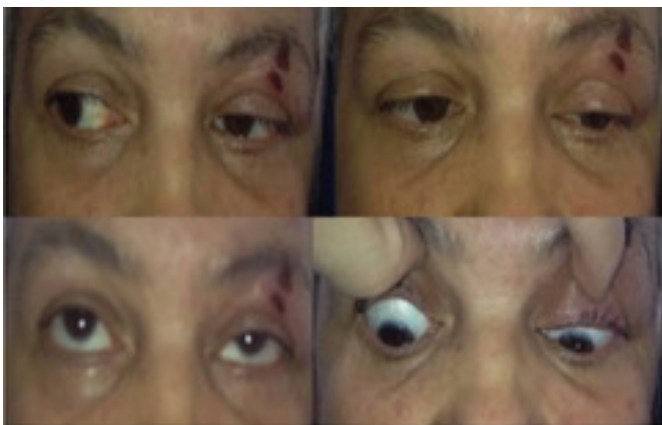


Figure 1: External photographs four cardinal directions of gaze

Laboratory results were within normal limits, except domination of lymphocytes in the white blood cell count. Diffusion-weighted magnetic resonance imaging (MRI) ruled out possible cerebral lesions (Figure-2). The patient did not have any sign of immune deficiency or HIV. After exclusion of possible causes, HZO was suspected. Oral valacyclovir 3000 mg/day (1000 mg, three times per day) was delivered for ten days. A nonsteroid anti-inflammatory drug was added to the treatment regimen. Vesicular lesions resolved approximately one week later, but diplopia persisted for three months. At the first year follow, minimal residual abduction deficit was still present.

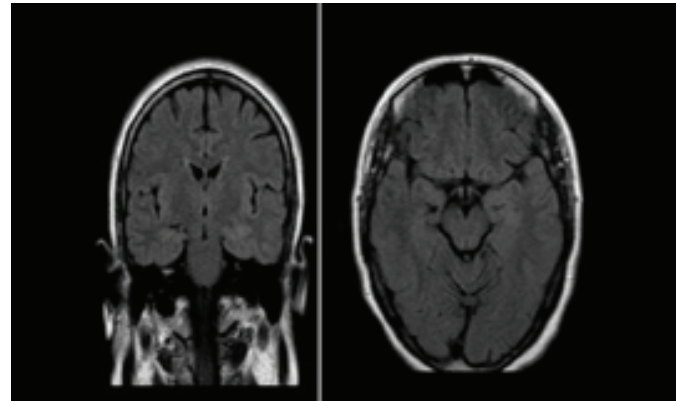


Figure 2: Coronal and axial MRI scans

Discussion

HZO results from reactivation of endogenous latent VZV infection within the ophthalmic branch of the trigeminal cranial nerve. Painful, unilateral vesicular eruptions are The characteristic painful, unilateral vesicular eruptions of HZO usually occurs in the dermatome distribution pattern of the sensory nerves.⁶ In our patient, vesicular lesions were observed on the left superior eyelid and the nasolabial-sulcus (Hutchinson's sign). Hutchinson's sign results from involvement of the nasociliary branch of the trigeminal nerve.⁷ The acute syndrome typically begins with a prodrome of headache, malaise, and fever. Unilateral pain or hypesthesia in the affected eye follows the prodrome.⁸ Most patients describe a deep burning, throbbing, or stabbing sensation.⁹ With the onset of a vesicular eruption along the trigeminal dermatome; hyperemic conjunctivitis, episcleritis, epithelial keratitis, punctate or dendritic and iritis can occur.⁸ In contrast with the usual symptoms, diplo-

pia with vomiting and headache without burning, were the major complaints of our patient. Thus ischemic cerebrovascular disease (CVD) that could affect a small part of brain had to be excluded. MRI ruled out any CVD and possible brain lesions such as silent cranial tumors and aneurysms. Neoplastic and vascular disease are the most common causes of isolated ANP.¹ Ptosis was one of the signs of our patient. Diplopia, malaise and ptosis are major signs of Myasthenia Gravis (MG), but most of the patients with MG do not complain of pain in the eye and headache.¹⁰ Orbital myositis can cause ANP.¹¹ It could present with conjunctival chemosis and injection, ptosis and proptosis. Superficial conjunctival hyperemia with superior punctate keratitis was observed in our patient. This could be the result of ptosis and rubbing of the eyelids. We were lucky to be aware of the vesicular lesions on the eyelids and the nose (Hutchinson's sign). The skin lesions of herpes zoster start as erythematous papules, which quickly evolve into grouped vesicles and they are crusted by 7-10 days.⁶ HZO may cause extraocular muscle palsy in 7-31% of patients.⁵ The extraocular muscle palsy generally appear 2-4 weeks after the skin lesions, and may persist for about 2-23 months. 87.5% of diplopia recovers within a year^{5,12}

Conclusion

As a result; in the differential diagnosis of diplopia caused by abducens nerve palsy, when the other causes could be excluded, HZO must be keep in mind. The vesicular lesions and pain located in ophtalmic nerve dermatome must be kept in mind when examining a patient with ANP.

References

1. Rucker CW. The causes of paralysis of the third, fourth and sixth cranial nerves. *Am J Ophthalmol.* 1966;61: 1293-1298.
2. Lee MS, Galetta SL, Volpe NJ, Liu GT: Sixth nerve palsies in children. *Pediatr Neurol.* 1999;20: 49-52.
3. Edgerton AE: Herpes zoster ophthalmicus: report of cases and a review of the literature. *Trans Am Ophthalmol Soc.* 1942;40: 390-439.
4. Aksoy S, Akova YA: Clinical diagnosis and treatment in herpetic anterior uveitis. *Turk J Ophthalmol.* 2009;39: 485-490.
5. Shin MK, Choi CP, Lee MY. A case of herpes zoster with abducens palsy. *J Korean Med Sci.* 2007;22: 905-907.
6. Dworkin RH, Johnson RW, Breuer J, Gnann JW, Levin MJ, Backonja M, Betts RF, Gershon AA, Haanpaa ML, McKendrick MW, Nurmikko TJ, Oaklander AL, Oxman MN, Pavan-Langston D, Petersen KL, Rowbotham MC, Schmader KE, Stacey BR, Tyring SK, van Wijck AJ, Wallace MS, Wassilew SW, Whitley RJ. Recommendations for the management of herpes zoster. *Clin Infect Dis.* 2007;44: 1.
7. Zaal MJ, Völker-Dieben HJ, D'Amato J. Prognostic value of Hutchinson's sign in acute herpes zoster ophthalmicus. *Graefes Arch Clin Exp Ophthalmol.* 2003;241: 187.
8. Pavan-Langston D. Herpes zoster ophthalmicus. *Neurology* 1995;45: 50.
9. Kost RG, Straus SE. Postherpetic neuralgia--pathogenesis, treatment, and prevention. *N Engl J Med.* 1996;335: 32.
10. Elrod RD, Weinberg DA. Ocular myasthenia gravis. *Ophthalmol Clin North Am.* 2004;17: 275.
11. Slavin ML, Glaser JS. Idiopathic orbital myositis: report of six cases. *Arch Ophthalmol.* 1982;100: 1261.
12. Shin HM, Lew H, Yun YS. A case of complete ophthalmoplegia in herpes zoster ophthalmicus. *Korean J Ophthalmol.* 2005;19: 302-304.