



Case Report

J Exp Clin Med  
2024; 41(1): 218-220  
doi: 10.52142/omujecm.41.1.37

**A lung hydatid cyst that was missed on a chest radiograph**

Ömer TOPALOĞLU<sup>1,\*</sup>, Elvan ŞENTÜRK TOPALOĞLU<sup>2</sup>

<sup>1</sup>Department of Thoracic Surgery, Bitlis State Hospital, Bitlis, Türkiye

<sup>2</sup>Department of Pulmonology, Bitlis State Hospital, Bitlis, Türkiye

Received: 25.11.2023

Accepted/Published Online: 22.03.2024

Final Version: 29.03.2024

**Abstract**

Lung hydatid cysts are easy to diagnose and can be treated with a simple surgical procedure. In lung hydatid cysts, conventional radiographic examinations are generally sufficient for the diagnosis of the disease. A 23-year-old female patient was admitted with complaints of left-sided pain, cough, and clear fluid with a bitter taste in the mouth that came with coughing. A giant cystic lesion was seen on chest radiography and thorax computed tomography (CT). In the external center radiological imaging of the patient examined through the system, it was seen that the cystic lesion was smaller in size and well-circumscribed in the chest radiograph taken 4 years ago. It was determined that the lesion was not noticed at that time, the existing lesion grew over the years and the diagnosis was delayed. Based on the findings, a ruptured lung hydatid cyst was considered. The patient underwent cystotomy and capitonnage through a left thoracotomy. The correct interpretation of radiological imaging methods used in the diagnosis of hydatid cysts is of great importance to prevent serious complications.

**Keywords:** hydatid cyst, chest radiograph, ruptured, complicated lung cysts, surgery

**1. Introduction**

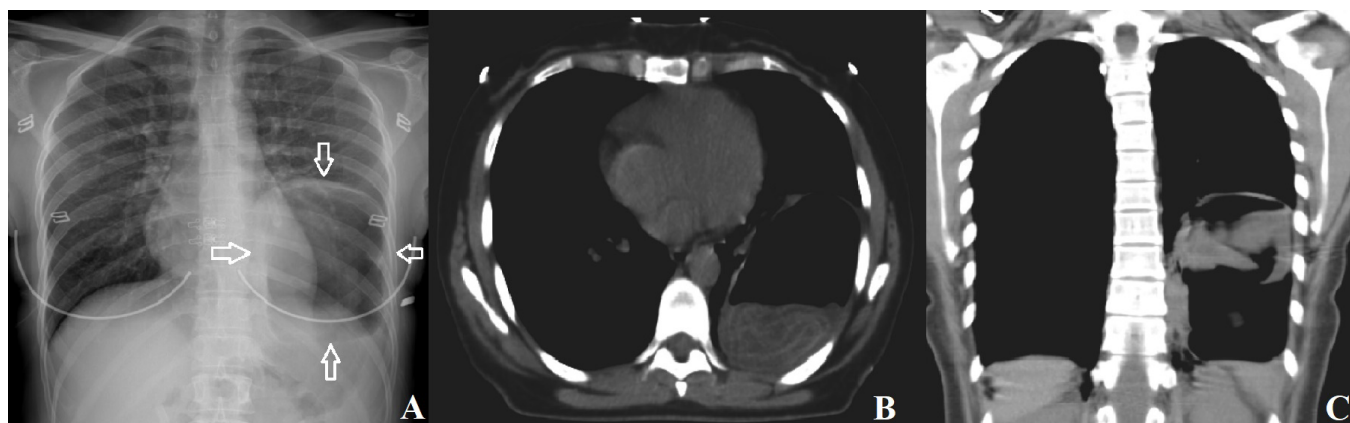
Hydatid cyst disease, which is a parasitic infestation, has very important medical, social, and economic effects. Although it is known as a benign disease, it can cause high morbidity and mortality due to unexpected serious complications. In most cases, it is easy to diagnose and can be treated with a simple surgical procedure (1). In lung hydatid cysts, conventional radiographic examinations are generally sufficient for the diagnosis of the disease (2). Uncomplicated lung cysts appear as round or oval masses with homogeneous density and well-circumscribed borders (3). Ultrasonography, computed tomography (CT), magnetic resonance imaging (MRI), and serological tests can be performed as complementary techniques for diagnosis (4). Here we report a case who presented with a ruptured hydatid cyst following a lesion that was observed on a posterior-anterior lung direct radiograph four years ago but was not noticed or overlooked.

**2. Case Report**

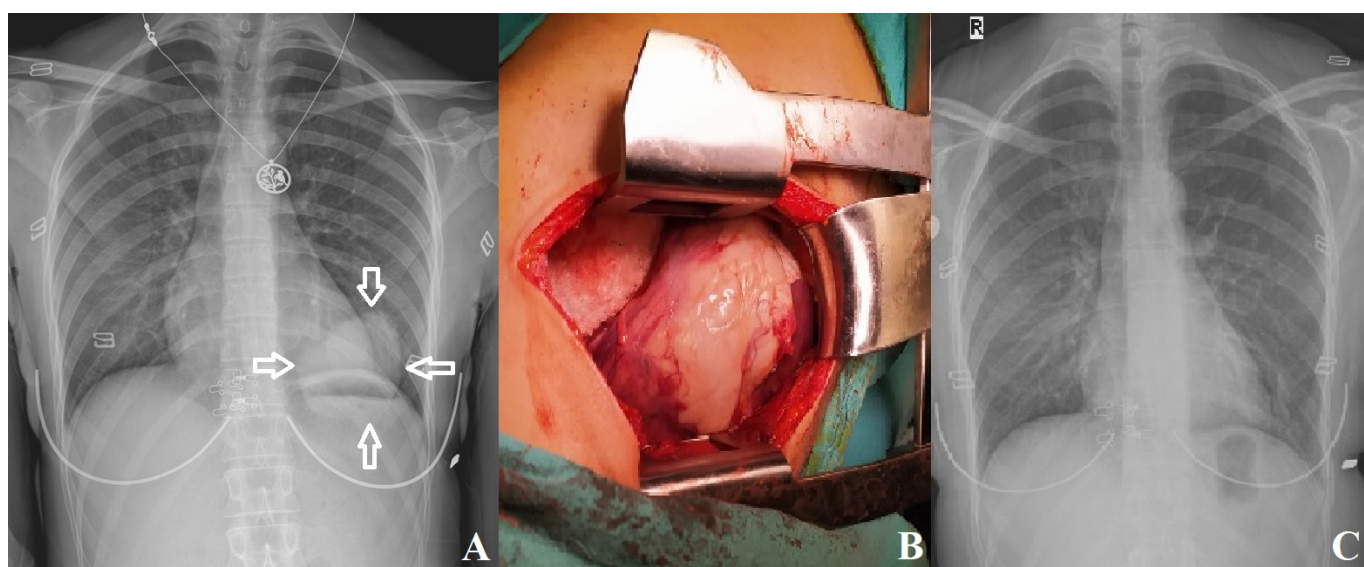
A 23-year-old female patient was admitted to our hospital with complaints of left flank pain, cough, and shortness of breath. From the patient's anamnesis, it was learned that 2 days ago, she coughed up clear liquid that left a bitter taste in her mouth, and her complaints continued to increase since then. During physical examination, auscultation revealed decreased and coarse breath sounds in the basal zone of the left hemithorax.

A cystic lesion was seen in the left lower zone on the chest X-ray (Fig. 1A). In the thorax CT, a thick-walled cystic lesion, approximately 101x72 mm in size, with linear membranous appearances giving an air-fluid level, was observed, filling the lower lobe of the left lung and forming areas of compression atelectasis around it (Fig. 1B and 1C). It was observed that there was a thin-walled, well-circumscribed cystic lesion of approximately 65\*60 mm in size in the left lower zone in the chest radiograph taken 4 years ago from the external center radiological imaging of the patient examined through the system (Fig. 2A). It turned out that the existing lesion grew over the years. A posterolateral thoracotomy was performed under general anesthesia in the case where ruptured hydatid cyst was considered among the preliminary diagnoses. A posteriorly located cyst wall was seen in the basal region of the left hemithorax. The lesion was removed by cystectomy and the lung parenchyma was repaired primarily by the capitonnage method. The diagnosis of a hydatid cyst was confirmed in the histopathological examination of the removed materials (Fig.2B). The patient, who did not cause any problems in the postoperative period, was discharged on the seventh day. As a medical treatment, albendazole 15 mg/kg/day was given for 3 months. At the end of the 6-month follow-up period, the patient was clinically asymptomatic, and no radiological recurrence was observed (Fig. 2C).

\*Correspondence: dromertopaloglu@hotmail.com



**Fig. 1.** (A) Posteroanterior chest radiography showing a giant hydatid cyst (white arrows). Thoracic CT axial (B) and coronal sections (C) shows a giant hydatid cyst of approximately 101x72 mm in the lower lobe of the left lung (white arrows)



**Fig. 2.** (A) Postero-anterior chest radiograph showing cystic lesion in chest radiograph taken 4 years ago (white arrows). (B) The wall of the cyst seen perioperatively. (C) Postoperative control postero-anterior chest radiography at 6th month

### 3. Discussion

In lung hydatid cysts, conventional radiographic examinations are generally sufficient for the diagnosis of the disease (2). Direct radiography, CT, and MRI are among the most important diagnostic methods (5). Uncomplicated lung cysts appear as round or oval masses with homogeneous density and well-circumscribed borders (3). A cyst growing in the lung may put pressure on the hydatid bronchi, causing atelectasis and, as a result, the development of pneumonia, and may rupture, causing anaphylactic shock, infection, or calcification in the lung (6). It was observed that our case was compatible with the appearance of a complicated cyst opening into the bronchus. On computer tomography, there was an appearance compatible with only the germinative membrane, in which the fluid in the cyst had completely drained. Additionally, it may be difficult to distinguish lesions in the lung parenchyma behind the heart in direct chest radiography. Lesions may be overlooked because this part of the lung is superimposed with the view of the heart. When the old images of our case were evaluated through the radiological imaging system, the lesion appeared to be smaller, rounder, well-circumscribed, and uncomplicated, behind the heart, in the posterior-anterior chest radiograph taken at an external center four years ago.

It seems possible to detect the lesion at an early stage with conventional radiographic examinations. However, when it was overlooked, it resulted in the lesion becoming complicated and ruptured in the future. Hydatid cyst, defined as a benign disease, can cause high morbidity and mortality by causing unexpected serious complications when the cyst opens into the bronchus. We think that in order to prevent these complications from occurring, all detected lung hydatid cysts should be treated and if there are no contraindications, surgical treatment should be applied in the early period.

The primary treatment of hydatid disease is surgical procedures. In our case, the lesion was present in the chest radiography four years ago, but as a result of it being overlooked, the cyst ruptured years later. We believe that correct interpretation and careful examination of radiological imaging methods used in the diagnosis of hydatid cysts are of great importance in order to prevent serious morbidity and possible mortalities.

#### Conflict of interest

The authors declared no conflict of interest.

#### Funding

No funding was used for the study.

#### **Acknowledgments**

None to declare.

#### **Authors' contributions**

Concept: Ö.T, E.Ş.T., Design: Ö.T, E.Ş.T., Data Collection or Processing: Ö.T, E.Ş.T., Analysis or Interpretation: Ö.T, E.Ş.T., Literature Search: Ö.T, E.Ş.T., Writing: Ö.T, E.Ş.T.,

#### **Ethical Statement**

This study was conducted ethically in accordance with the World Medical Association Declaration of Helsinki as revised in 2000. Written informed consent was obtained from the patient or the next of kin for publication.

#### **References**

1. Işıtmangil T, Görür R, Yiğit N, Erdik O, Yıldızhan A, Candaş F, Sebit Ş, Tunç H, Selçuk S, Kunter E. Toraksta kist hidatik hastalığı

nedeniyle cerrahi tedavi uygulanan 308 hastanın değerlendirilmesi. Türk Göğüs Kalp Damar Cerrahisi Dergisi. 2010; 18(1): 27 - 33.

2. Morar R, Feldman C. Pulmonary echinococcosis. Eur Respir J. 2003;21:1069-77.
3. Halezeroglu S, Celik M, Uysal A, Senol C, Keles M, Arman B. Giant Hydatid cysts of the lung. J Thorac Cardiovasc Surg 1997;113:712-7.
4. Aydın Y, Ulas AB, Eroglu A. Diagnosis of a hepatic hydatid cyst using posteroanterior chest radiography. Rev Soc Bras Med Trop. 2022;55:e0205-2022.
5. Çelik M, Koç M, Berçin S, Demir H, Özercan R. Maligniteyi taklit eden rüptüre akciğer kist hidatik olgusu. Fırat Tıp Dergisi. 2015; 20(1): 63 - 66.
6. Varela A, Burgos R, Castedo E. Parasitic diseases of the lung and pleura. In: Patterson GA, Cooper JD, Deslauriers J, editors. Pearson's thoracic & esophageal surgery, 3rd ed. Philadelphia: Churchill Livingstone; 2008. p. 550-65.