

Pelvic incidence effects pars interarticularis defect and spondylolisthesis

 Atakan Besnek

Department of Neurosurgery, Şanlıurfa Training and Research Hospital, Şanlıurfa, Turkey

Cite this article as: Besnek A. Pelvic incidence effects pars interarticularis defect and spondylolisthesis. *J Med Palliat Care.* 2023;4(6):651-655.

Received: 28.11.2023

Accepted: 15.12.2023

Published: 31.12.2023

ABSTRACT

Aims: Pars interarticularis defect (PID) is a common problem in society and may be accompanied with low back pain and radiculopathy. Magnetic resonance imaging (MRI) can detect it with high sensitivity. If left untreated, it may progress to spondylolisthesis. In this study, we wanted to emphasize the importance of the pelvic incidence (PI) angle in terms of following the development of spondylolisthesis after PID by examining the relationship between PID and spondylolisthesis and PI.

Methods: 118 patients who applied to Şanlıurfa Training and Research Hospital between 2021-2022 and underwent lumbar MRI were included in the study. The criteria for inclusion of patients in the study were the detection of a pars interarticularis defect on MRI, the ability to be evaluated by direct radiography or CT, and the ability to monitor the femoral head and sacrum in a way that PI could be measured. PI angle measurement was performed, confirmed by CT. The relationship between PID, spondylolisthesis and PI was examined.

Results: Of the 118 patients participating in the study, 77 (65.3%) were women and 41 (34.7%) were men. Pars defect was most commonly seen at the L5 level (67.8%). The average pelvic incidence angle is 64.2 ± 8.6 . Half of the patients were calculated as Meyerding grade 0 and 95.8% were treated medically. The median pelvic incidence angle value of patients without spondylolisthesis was found to be 58.0, the median pelvic incidence angle value of patients with a Meyerding grading of one was found to be 68.0, and the median value of the pelvic incidence angle of patients with a Meyerding grading of one was found to be 78.0 ($p < 0.001$).

Conclusion: In this study, we detected patients with PID with MRI and revealed that there is a significant relationship between high PI degree and PID and spondylolisthesis. When high PI is detected in patients with PID, predicting that spondylolisthesis may develop in these patients is an important finding that will shape follow-up and treatment.

Keywords: Pars interarticularis, spondylolisthesis, pelvic incidence

INTRODUCTION

Pars interarticularis is located between the superior and inferior articular facet. Pars interarticularis defect (PID) is a problem that is seen in 3-10% of the population and frequently causes low back pain and radiculopathy.¹ Its incidence varies with age, gender, genetic factors and activity. Its incidence increases with age, and it is 2-3 times more common in men than in women. While its incidence in the Eskimo population can reach 50%, it can be seen in 47% of athletes presenting with back pain.² It can be unilateral or bilateral. In studies, it was most frequently detected at the L5 level.¹ Microtraumas during repetitive lumbar extension have an important place in its pathophysiology.³

Radiography, computed tomography (CT) and magnetic resonance imaging (MRI) are radiological methods frequently used to detect PID. Anteroposterior and

lateral radiographs have lower sensitivity than CT. MRI has similar sensitivity to CT.^{1,4} The fact that CT does not show radiation exposure and soft tissues as well as MRI is one of the reasons why MRI is preferred more frequently in patients presenting with low back pain and radiculopathy. In addition, MRI shows bone marrow edema better in the early stages.^{5,6}

While PID does not cause listhesis in 30-50% of patients, isthmic spondylolisthesis can be seen in 50-70% of patients.³ Many pelvic parameters have been investigated, but strong evidence has been presented that there is a relationship between pelvic incidence (PI) and PID and spondylolisthesis. PI is a personal and fixed pelvic parameter that determines lumbar lordosis and pelvic orientation.⁷ In those with high PI degrees, it is expected that the force on the pars interarticularis during extension will increase due to hyperlordosis and more PID will

Corresponding Author: Atakan BESNEK, atakanbesnek80@gmail.com



occur. This causes isthmic spondylolisthesis to be more common.⁸ The relationship between spondylolisthesis and pelvic parameters has been examined in many publications in the literature, but there are few studies examining PID and spondylolisthesis and pelvic parameters. With this study, we wanted to contribute to the literature by examining PID and spondylolisthesis detected by MRI and the relationship between these findings and PI in patients presenting with low back pain and radiculopathy.

METHODS

The study was approved by the Harran University Clinical Researches Ethics Committee (Date: 13.11.2023, Decision No: HRÜ/23.21.16) and because the study was designed retrospectively, no written informed consent form was obtained from patients. All procedures were carried out in accordance with the ethical rules and the principles of the Declaration of Helsinki.

The study was planned as a retrospective cohort study. The data of the patients who applied to the Neurosurgery outpatient clinic of Şanlıurfa Training and Research Hospital between 2021-2022 and who underwent lumbar MRI due to complaints of low back pain and radiculopathy were examined, and patients whose data were suitable were included in the study. 118 patients who applied to the outpatient clinic between 2021-2022 were included in our study. The criteria for inclusion of patients in the study were the detection of a pars interarticularis defect on MRI, the ability to be evaluated by direct radiography or CT, and the ability to monitor the femoral head and sacrum in a way that PI could be measured. Patients over the age of 18 were included in the study and the pediatric population was excluded.

Three stages were taken into account when investigating PID; early, progressive and terminal stages. Although there are different classifications, in this study the classifications were taken into account only when examining the images to prevent the pars defect from being overlooked, and no statistical information was created regarding this condition. In CT images, a thin fissure line and sharp boundaries were observed in the early stage, a wider fissure line was observed in the progressive stage, while the appearance of pseudoarthrosis was taken into account in the terminal stage. MRI is more effective in showing defects that cannot be detected by CT at a very early stage, but since STIR sequence or fat-suppressed sequence was not performed in all patients in our study, information on this subject could not be provided. In the early stages of the defect, low signal intensity is observed in the T1 sequence and higher signal intensity in the T2 sequence, while as fracture healing progresses, low signal intensity is observed in both sequences.

PI (the angle between the line drawn from the center of the femoral head to the midpoint of the sacral endplate and the line drawn perpendicularly from the midpoint of the sacrum) was evaluated by lateral radiography. If the femoral head could not be evaluated clearly and appeared bilateral, the midpoint of the line drawn from the midpoint of both femoral heads was taken into account. Meyerding grading was used in the grading of spondylolisthesis. Since no Meyerding grade 4 patients were identified, they were examined by grouping them as Meyerding 0 (no spondylolisthesis), 1, 2-3.

SPSS 29.0 program was used in statistical analysis. Descriptive analyzes were performed and continuous variables were presented as mean, standard deviation, median and 25-75th percentile values. Normal distribution analyzes of continuous variables were evaluated with Shapiro-Wilk analysis and it was determined that all of them did not comply with normal distribution. Three patients with pars defects detected in both L4 and L5 were included in the L5 group in statistical analysis. For statistical comparisons, the chi-square test was used for categorical variables and the Mann-Whitney U test was used for continuous variables. The change between pelvic incidence angle and Meyerding grading is shown with a boxplot graph. The limit of statistical significance was accepted as a p value of less than 0.05.

RESULTS

77 women (65.3%) and 41 men (34.7%) were included in the study. The average age of the participants is 46.5 ± 13.7 . Pars defect was most commonly seen at the L5 level (67.8%). The average pelvic incidence angle is 64.2 ± 8.6 . Half of the patients were calculated as Meyerding grade 0 and 95.8% were treated medically. The defect was found to be unilateral in only 4 of the patients participating in the study (Table 1).

No relationship was found between gender, pelvic incidence angle and pars defect level. The median age of patients with pars defects at the L3-L4 level was 56.0, while the median age of those with pars defects at the L5 level was 41.0. The detected difference is statistically significant ($p < 0.001$). Meyerding grade 2 or higher was detected in 5.7% of the patients with pars defects at the L3-4 level and 20.5% of the patients with the L5 level ($p = 0.046$) (Table 2).

The median pelvic incidence angle value of patients without spondylolisthesis was found to be 58.0, the median pelvic incidence angle value of patients with Meyerding grading 1 was 68.0, and the median value of the pelvic incidence angle was found to be 78.0 in patients with Meyerding grading 2 and above ($p < 0.001$) (Table 3). The change in pelvic incidence angle with the Meyerding grade is shown in Figure 1.

Table 1. Descriptive analyzes of the variables included in the study

Variables	n	%
Gender		
Female	77	65.3
Male	41	34.7
Age, years		
Mean±SD	46.5±13.7	
Median (25-75 p)	48.0 (36.0-58.25)	
Pars defect level		
L3	4	3.4
L4	31	26.3
L4 L5	3	2.5
L5	80	67.8
Pelvic incidence		
Mean±SS	64.2±8.6	
Median (25-75 p)	63.0 (58.0-70.0)	
Meyerding grade		
0	60	50.8
1	39	33.1
2	15	12.7
3	4	3.4
Treatment		
Surgical	5	4.2
Medical	113	95.8
Side		
Unilateral	4	3.4
Bilateral	114	96.6

Table 2. Comparison of variables with pars defect level

Pars defect level	L3-4		L5		p
	n	%	n	%	
Gender					
Female	23	65.7	54	65.1	0.946
Male	12	34.3	29	34.9	
Age, years					
Median (25-75 p)	56.0 (44.0-60.0)		41.0 (33.0-57.0)		<0.001
Pelvic incidence					
Median (25-75 p)	61.0 (56.0-67.0)		64.0 (58.0-72.0)		0.105
Meyerding grade					
0-1	33	94.3	66	79.5	0.046
2-3	2	5.7	17	20.5	
Meyerding grade					
0	18	51.4	42	50.6	0.091
1	15	42.9	24	28.9	
2-3	2	5.7	17	20.5	

Table 3. Relationship between pelvic incidence score and meyerding grade

Pelvic incidence	Median	25-75 p	p
Meyerding grade			<0.001
0	58.0	54.0-60.75	
1	68.0	65.0-70.0	
2-3	78.0	78.0-80.0	

Mann-Whitney U Test was used.

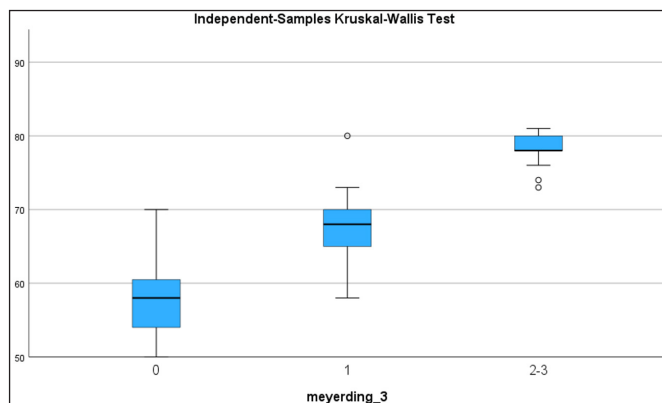


Figure 1. Pelvic incidence angle change with Meyerding grade

DISCUSSION

Pars interarticularis defect and spondylolisthesis is a problem whose prevalence in the population varies between 3-10%, and its frequency can reach 78% depending on activity participation. Although it is more common in men than women in studies, this is entirely related to activity, and in our study, the incidence was found to be higher in women (65.3%).^{1,9} Micheli et al.¹⁰ They recorded a 47% incidence rate in their study of athletes with back pain. Similar studies have shown that the incidence of pars defects increases with activity participation.¹ In the region where we conducted this study, women work as agricultural workers and, accordingly, it is detected more frequently in female gender. It is thought to have been done. Although the rate was higher in Sairyo et al.'s⁶ studies on CT, in a study they conducted on MRI, they detected a defect at the L5 level in 66.3% of the patients.^{5,11} In our study, similar to the literature, 67.8% of the patients had a defect. PID was detected at the L5 level in 32.2% of patients, and at L3 or L4 levels in 32.2%. The rate of unilateral PID was found to be 3.4%, which is similar to the literature.¹²

Many radiological methods are used in the diagnosis of PID. Although CT is better at showing bone tissue, it is not as sensitive as MRI in showing the processes of the nerve root, intervertebral disc and pars defect. However, there is high radiation exposure.^{6,13} Rush et al.¹⁴ In their study on 26 patients, they detected 36 PIDs with MRI, but they could not detect 3 PIDs that could be detected with CT. Saifuddin et al.¹⁵ found the sensitivities of MRI and CT to be similar in their study. Masci et al.¹⁶ in their study, the sensitivity of MRI; They found it to be 80% when compared with scintigraphy and 94.74% when compared to CT. When all these studies were examined; MRI has similar but lower sensitivity than CT and scintigraphy in diagnosing PID. In addition, it is an imaging method frequently used in polyclinics because it does not emit radiation and is successful in revealing other pathologies. We did not aim to reveal the sensitivity

of MRI or its differences with other imaging methods in our study. We wanted to diagnose a common problem in society with an imaging method that we frequently use and examine its relationship with PI. Therefore, only MRI examinations were examined, patients with PID were confirmed with CT, and their relationship with Meyerding grading and PI were examined through imaging.

PID, which occurs due to recurrent microtrauma or another reason, progresses naturally with pseudoarthrosis if there is no recovery. This condition causes instability and may progress to isthmic spondylolisthesis. Since high Meyerding grades are associated with mechanical instability, they increase the likelihood of symptoms and the need for surgery in the patient.^{17,18} Predicting which patients will develop spondylolisthesis after PID develops can play an important role in the follow-up and treatment of patients. Studies have been conducted on pelvic parameters, but no parameter other than PI has been shown to be related to PID and spondylolisthesis.^{19,20} In their study, Legaye et al.²¹ found that there was a relationship between spinal sagittal alignment and PI. Hanson et al.²² in their study, the mean PI was found to be 47.4° in the pediatric control group, 57° in the adult control group, 68.5° in the low-grade isthmic spondylolisthesis group, and 79.0° in the high-grade isthmic spondylolisthesis group. Significantly higher pelvic incidence values were detected in both the low-grade and high-grade isthmic spondylolisthesis groups than in the adult or pediatric control groups (P=0.001). The pelvic incidence of the high-grade group was found to be significantly higher than the low-grade group (P=0.007). In this study, spondylolisthesis was not detected in 50.8% of the patients. In our study, we found the mean PI value to be 64°. The average PI was 58° in patients without spondylolisthesis, 68° in low-grade listhesis patients, and 78° in high-grade listhesis patients. PI value was found to be significantly higher in patients with high-grade spondylolisthesis (P<0.001). PI values were found to be significantly lower in the patient group without spondylolisthesis (P<0.001). The rate of patients to whom we applied surgical treatment was found to be 4.2%.

The fact that we planned to study only by evaluating MRI is one of the limiting points of our study. However, we found this to be negligible, considering that it has similar sensitivity to CT and is a more frequently used method. The fact that thin-section MRI and fat-suppressed sequence were not performed in all patients may have caused patients with early-stage PID to be overlooked. To overcome this limitation, we included only the adult patient population in our study.

CONCLUSION

PID is a condition that is frequently detected incidentally in the population and can cause low back pain and radiculopathy. Most patients do not require surgical treatment. It can be detected with high sensitivity by CT and MRI. Sagittal spinopelvic balance directly affects all anatomical segments it is associated with. In this study, we demonstrated that there is a significant relationship between high PI degree and PID and spondylolisthesis. When high PI is detected in patients with PID, predicting that spondylolisthesis may develop in these patients is an important finding that will shape follow-up and treatment.

ETHICAL DECLARATIONS

Ethics Committee Approval: The study was carried out with the permission of Harran University Clinical Researches Ethics Committee (Date: 13.11.2023, Decision No: HRÜ/23.21.16).

Informed Consent: Because the study was designed retrospectively, no written informed consent form was obtained from patients.

Referee Evaluation Process: Externally peer-reviewed.

Conflict of Interest Statement: The authors have no conflicts of interest to declare.

Financial Disclosure: The authors declared that this study has received no financial support.

Author Contributions: All of the authors declare that they have all participated in the design, execution, and analysis of the paper, and that they have approved the final version.

REFERENCES

1. Linton AA, Hsu WK. a review of treatment for acute and chronic pars fractures in the lumbar spine. *Curr Rev Musculoskelet Med.* 2022;15(4):259-271.
2. Berger RG, Doyle SM. Spondylolysis 2019 update. *Curr Opin Pediatr.* 2019;31(1):61-68.
3. Sakai T, Goda Y, Tezuka F, et al. Clinical features of patients with pars defects identified in adulthood. *Eur J Orthop Surg Traumatol.* 2016;26(3):259-262.
4. Saifuddin A, White J, Tucker S, Taylor BA. Orientation of lumbar pars defects: implications for radiological detection and surgical management. *J Bone Joint Surg Br.* 1998;80(2):208-211.
5. Goda Y, Sakai T, Sakamaki T, Takata Y, Higashino K, Sairyo K. Analysis of MRI signal changes in the adjacent pedicle of adolescent patients with fresh lumbar spondylolysis. *Eur Spine J.* 2014;23(9):1892-1895.
6. Sairyo K, Katoh S, Takata Y, et al. MRI signal changes of the pedicle as an indicator for early diagnosis of spondylolysis in children and adolescents: a clinical and biomechanical study. *Spine.* 2006;31(2):206-211.
7. Labelle H, Roussouly P, Berthounaud E, Dimnet J, O'Brien M. The importance of spino-pelvic balance in L5-s1 developmental spondylolisthesis: a review of pertinent radiologic measurements. *Spine.* 2005;30(6S):S27-34.

8. Rajnics P, Templier A, Skalli W, Lavaste F, Illés T. The association of sagittal spinal and pelvic parameters in asymptomatic persons and patients with isthmic spondylolisthesis. *J Spinal Disord Tech*. 2002;15(1):24-30.
9. Fredrickson BE, Baker D, McHolick WJ, Yuan HA, Lubicky JP. The natural history of spondylolysis and spondylolisthesis. *J Bone Joint Surg Am*. 1984;66(5):699-707.
10. Micheli LJ, Wood R. Back pain in young athletes. significant differences from adults in causes and patterns. *Arch Pediatr Adolesc Med*. 1995;149(1):15-18.
11. Sakai T, Sairyo K, Takao S, Nishitani H, Yasui N. Incidence of lumbar spondylolysis in the general population in Japan based on multidetector computed tomography scans from two thousand subjects. *Spine*. 2009;34(21):2346-2350.
12. Park JS, Moon SK, Jin W, Ryu KN. Unilateral lumbar spondylolysis on radiography and MRI: emphasis on morphologic differences according to involved segment. *AJR Am J Roentgenol*. 2010;194(1):207-215.
13. Sakai T, Sairyo K, Mima S, Yasui N. Significance of magnetic resonance imaging signal change in the pedicle in the management of pediatric lumbar spondylolysis. *Spine*. 2010;35(14):E641-E645.
14. Rush JK, Astur N, Scott S, Kelly DM, Sawyer JR, Warner Jr WC. Use of magnetic resonance imaging in the evaluation of spondylolysis. *J Pediatr Orthop*. 2015;35(3):271-275.
15. Saifuddin A, Burnett SJ. The value of lumbar spine MRI in the assessment of the pars interarticularis. *Clin Radiol*. 1997;52(9):666-671.
16. Masci L, Pike J, Malara F, Phillips B, Bennell K, Brukner P. Use of the one-legged hyperextension test and magnetic resonance imaging in the diagnosis of active spondylolysis. *Br J Sports Med*. 2006;40(11):940-946.
17. Bhalla A, Bono CM. Isthmic lumbar spondylolisthesis. *Neurosurg Clin N Am*. 2019;30(3):283-290.
18. Cavalier R, Herman MJ, Cheung EV, Pizzutillo PD. Spondylolysis and spondylolisthesis in children and adolescents: I. Diagnosis, natural history, and nonsurgical management. *J Am Acad Orthop Surg*. 2006;14(7):417-424.
19. Danielson BI, Frennered AK, Irstam LK. Radiologic progression of isthmic lumbar spondylolisthesis in young patients. *Spine*. 1991;16(4):422-425.
20. Wiltse LL. The etiology of spondylolisthesis. *J Bone Joint Surg Am*. 1962;44(3):539-560.
21. Legaye J, Duval-Beaupère G, Hecquet J, Marty C. Pelvic incidence: a fundamental pelvic parameter for three-dimensional regulation of spinal sagittal curves. *Eur Spine J*. 1998;7(2):99-103.
22. Hanson DS, Bridwell KH, Rhee JM, Lenke LG. Correlation of pelvic incidence with low- and high-grade isthmic spondylolisthesis. *Spine*. 2002;27(18):2026-2029.