

## Evaluating the Effect of Childhood Obesity on Choroidal Structures

Serdar BİLİCİ<sup>1</sup>  , Tuba GÜLTEKİN-EROL<sup>1</sup> , Meliha Esra BİLİCİ<sup>2</sup> , Silay CANTÜRK-UĞURBAŞ<sup>1</sup> ,  
Suat Hayri UĞURBAŞ<sup>1</sup> 

<sup>1</sup>Zonguldak Bülent Ecevit University, Faculty of Medicine, Department of Ophthalmology, Zonguldak, Türkiye

<sup>2</sup>Zonguldak Bülent Ecevit University, Faculty of Medicine, Department of Child Health and Diseases,  
Department of Pediatric Endocrinology, Zonguldak, Türkiye

Cite this article as: Bilici S et al. Evaluating the effect of childhood obesity on choroidal structures. Turk J Diab Obes 2024;1: 6-12.

This study was presented as a poster at the 56th National Congress of the Turkish Ophthalmology Association, 2-6 November 2022, Antalya, Türkiye.

### ABSTRACT

**Aim:** To evaluate the effect of childhood obesity on choroidal structures with spectral-domain optical coherence tomography (SD-OCT).

**Material and Methods:** A total of 80 children (20 children per each group; healthy, overweight, obese, and morbid-obese) were included in the study. Accompanying comorbidities such as insulin resistance, dyslipidemia, and metabolic syndrome were recorded. The subfoveal choroidal thickness (SFCT) and choroidal vascularity index (CVI) measurements were obtained from SD-OCT images and compared between groups.

**Results:** No notable differences were found between groups regarding the means of age and axial length ( $p=0.504$ , and  $p=0.805$ , respectively). The SFCT medians (min-max) of healthy, overweight, obese, and morbid-obese children were 398.5 (319.0-453.5)  $\mu\text{m}$ , 299.0 (274.7-387.0)  $\mu\text{m}$ , 295.5 (257.0-385.0)  $\mu\text{m}$ , and 304.5 (272.2-386.0)  $\mu\text{m}$  respectively. Overweight and obese children had thinner choroid than non-obese healthy children ( $p=0.032$ ). Besides, no significant correlation was observed between the severity of obesity and SFCT ( $p=0.722$ ). In terms of CVI, total choroidal area, luminal area, and stromal area; no significant differences were found between groups ( $p=0.710$ ,  $p=0.452$ ,  $p=0.221$ , and  $p=0.863$ , respectively). Obese children with dyslipidemia had thinner SFCT than those not have dyslipidemia (292.0 (166-431)  $\mu\text{m}$  vs 348.0(173-491)  $\mu\text{m}$ ,  $p=0.003$ ), while insulin resistance and metabolic syndrome had no effect on SFCT ( $p=0.336$ , and  $p=0.211$ , respectively).

**Conclusion:** Childhood obesity and accompanying dyslipidemia led to a decrease in SFCT without any significant change in the CVI. However, the severity of obesity and having insulin resistance or metabolic syndrome had no effect on either SFCT or CVI. The thinning in the SFCT may be related to microvascular disorders due to childhood obesity and dyslipidemia.

**Keywords:** Childhood obesity, Choroidal vascularity index, Subfoveal choroidal thickness, Optical coherence tomography

## Çocukluk Çağı Obezitesinin Koroidal Yapılar Üzerine Etkisinin Değerlendirilmesi

### ÖZ

**Amaç:** Çocukluk çağı obezitesinin koroidal yapılar üzerindeki etkilerini spektral domain optik koherens tomografi ile değerlendirmek.

**Gereç ve Yöntemler:** Çalışmaya her gruptan (sağlıklı, fazla kilolu, obez ve morbid-obez) 20' şer toplamda 80 çocuk dahil edildi. Olguların insülin direnci, dislipidemi ve metabolik sendrom gibi komorbiditelerinin varlığı kaydedildi. Olguların optik koherens tomografi görüntülerinden elde edilen subfoveal koroid kalınlığı (SFCK) ve koroid vaskülarite indeksi (KVI) değerleri karşılaştırıldı.

**Bulgular:** Gruplar yaş ve aksiyel uzunluk ortalamaları açısından benzer bulundu (sırasıyla  $p=0,504$  ve  $p=0,805$ ). Sağlıklı, fazla kilolu, obez ve morbid-obez çocuklarda medyan (min-maks) SFCK sırasıyla 398,5 (319,0-453,5)  $\mu\text{m}$ , 299,0 (274,7-387,0)  $\mu\text{m}$ , 295,5 (257,0-385,0)  $\mu\text{m}$  ve 304,5 (272,2-386,0)  $\mu\text{m}$  idi. Fazla kilolu ve obez çocuklarda SFCK sağlıklı çocuklara göre daha incedi ( $p=0,032$ ). Ancak

ORCID: Serdar Bilici / 0000-0003-1346-0850, Tuba Gültekin-Erol / 0000-0001-8712-9170, Meliha Esra Bilici / 0000-0002-9262-7200, Silay Cantürk-Uğurbaş / 0000-0002-6288-0467, Suat Hayri Uğurbaş / 0000-0002-8992-8838

Correspondence Address / Yazışma Adresi:

Serdar BİLİCİ

Zonguldak Bülent Ecevit University, Faculty of Medicine, Department of Ophthalmology, Zonguldak, Türkiye  
Phone: +90 (372) 261 20 25 • E-mail: drserdarbilici@gmail.com

DOI: 10.25048/tudod.1400388

Received / Geliş tarihi : 05.12.2023

Revision / Revizyon tarihi : 08.04.2024

Accepted / Kabul tarihi : 08.04.2024

obezite şiddeti ile SFKK istatistiksel olarak ilişkili bulunmadı ( $p=0,722$ ). Gruplar arasında KVİ, toplam koroid alanı, luminal alan ve stromal alan açısından anlamlı fark yoktu (sırasıyla  $p=0,710$ ,  $p=0,452$ ,  $p=0,221$  ve  $p=0,863$ ). Dislipidemi olan obez çocuklarda SFKK, dislipidemi olmayanlara göre daha düşük bulundu ( $292,0(166-431)$   $\mu\text{m}$  vs  $348,0(173-491)$   $\mu\text{m}$ ,  $p=0,003$ ). Eşlik eden insülin direnci ve metabolik sendrom varlığının ise SFKK üzerine etkisi gözlenmedi ( $p=0,336$  ve  $p=0,211$ , sırasıyla).

**Sonuç:** Çocukluk çağı obezitesi ve eşlik eden dislipidemi varlığı, KVİ'de herhangi bir anlamlı değişiklik yapmadan SFKK'de azalmaya yol açmaktadır. Ancak obezite şiddeti ve eşlik eden insülin direnci veya metabolik sendroma sahip olmanın SFKK veya KVİ üzerinde etkisi gözlenmemiştir. SFKK parametresinde incelmeye görülmesi çocukluk çağı obezitesi ve dislipidemi varlığına bağlı mikrovasküler bozukluklar ile ilişkili olabilir.

**Anahtar Sözcükler:** Çocukluk çağı obezitesi, Koroid vaskülarite indeksi, Subfoveal koroid kalınlığı, Optik koherens tomografi

## INTRODUCTION

Childhood obesity is a global health problem that affects the whole world, regardless of gender and ethnicity. It is estimated that around 10% of children younger than 5 years of age worldwide are overweight and obese (1). Obese individuals are at serious risk for certain comorbidities such as diabetes mellitus type 2, cardiovascular disease, metabolic syndrome etc. (2-4). Those comorbidities, especially DM, have been shown by optic coherence tomography (OCT) to affect retinal layers (5-7).

The vascular network is an important system affected by obesity, both morphologically and functionally (8). Ocular vasculature and blood flow are also affected by obesity-related potential endothelial dysfunction and vascular damage (9). Therefore, assessing the choroid—one of the body's most vascularized tissues—might be an essential measure of the microvascular changes associated with obesity. Thus far, the impact of obesity on the choroid has been assessed through changes in subfoveal choroidal thickness (SFCT) (10-15). Nevertheless, SFCT is influenced by a variety of circumstances and is unable to offer comprehensive details regarding the choroid's vascular and stromal organization (16,17). Recently, a more solid biomarker called the choroidal vascularity index (CVI) has been introduced. It is based on the binarization of enhanced depth imaging (EDI) mode of spectral domain-optical coherence tomography (SD-OCT) images and provides details on the proportional alteration of the choroid's stromal and luminal vascular components (18). Thus, the current study is designed to evaluate the effect of childhood obesity on choroidal vascular structures for the first time in the literature.

## MATERIAL and METHODS

This prospective cross-sectional study was conducted in compliance with the principles of the Declaration of Helsinki at the Ophthalmology and Pediatric Endocrinology Departments of Zonguldak Bulent Ecevit University Faculty of Medicine after the approval of the Ethics Committee

of Zonguldak Bulent Ecevit University (2022/06-09). Informed consent and oral assent were received from the legal guardians of the participants.

The children examined in the Department of Pediatric Endocrinology between March and July 2022 were included in the study. A scale and a stadiometer (Seca, Chino, CA) were used to measure body weight and height with patients wearing light clothes. Body mass index was computed by division of the weight by the square of the height ( $\text{kg}/\text{m}^2$ ) and the body mass index standard deviation score (BMI-SDS) was categorized using the age and sex-adjusted standard growth charts of Turkish children (19). According to BMI-SDS values children were classified into 4 groups: non-obese group if the BMI-SDS is between -1 and 1; overweight group if the BMI-SDS is between 1-2; obese group if the BMI-SDS is between 2-3; and morbid-obese group if the BMI-SDS is  $>3$ . The study group consists of overweight, obese, and morbidly obese groups while the non-obese group was accepted as the control group. 20 children per each BMI-SDS group were referred to Ophthalmology Department.

Blood pressure measurements of the children were taken while seated following of 5-minute rest period. Obese children underwent blood sample collection in the morning following an overnight fasting period. These samples were then analyzed for serum insulin levels, plasma glucose levels, and plasma lipid profiles. According to homeostasis model assessment of insulin resistance (HOMA-IR), a HOMA-IR score of  $>2$  was accepted to indicate insulin resistance (20). Endocrine Society Clinical Practice Guideline was used to determine dyslipidemia (21). Metabolic syndrome (MS) was diagnosed according to International Diabetes Federation criteria for children (22).

All children underwent a complete ophthalmic examination between 9-11 am by the same ophthalmologist (TGE) including axial length measurement with optical biometer (Optical Biometer AL-Scan, Nidek Co., Japan) and EDI mode of OCT imaging with the SD-OCT device (Spectralis, Heidelberg Engineering, Heidelberg, Germany).

Children with systemic diseases such as diabetes mellitus and autoimmune diseases or significant ophthalmological diseases, amblyopia, BCVA < 20/20, poor image quality, and young children unable to cooperate for OCT were among the exclusion criteria for this study.

Binarization of EDI-OCT images was performed using the method reported by Tan et al. (23). ImageJ 1.51 program (National Institutes of Health, Bethesda, MD, USA) was used for analyzing horizontal subfoveal EDI-OCT images. The distance from the lower margin of the retinal pigment epithelium (RPE) to the scleral border at the subfoveal region was recorded as the SFCT. A perpendicular line overlay was drawn through the fovea's center using the line tool. A total choroidal area (TCA) was defined by drawing two 750  $\mu\text{m}$  lines from the fovea's center to both sides, covering a total of 1500  $\mu\text{m}$ . The polygon's three vertices were positioned on the TCA's upper and below borders. The TCA's lower boundary was traced at the choroid-scleral junction, whereas its upper border was traced along the lower margin of RPE (Figure 1A). The EDI-OCT picture/image was first converted to an 8-bit format and then thresholded using Niblack's thresholding approach to binarize the images (Figure 1B). After that, the image was converted back to red, green, and blue. Black pixels, which represent the luminal (vascular) region (LA), were then demarcated with the color threshold tool. White pixels, representing the stromal area (SA), were generated by computing the differences between the TCA and LA. Lastly, the ratio of LA to TCA was used for determining CVI.

### Statistical Analysis

Data analysis was performed with IBM SPSS 23.0 software (SPSS Inc. Chicago, USA). Descriptive statistics were used to summarize the data. For categorical variables, frequencies and percentages were utilized, while for continuous variables, mean  $\pm$  standard deviation and median with minimum-maximum value were reported. The normalcy of the data was assessed using the Kolmogorov-Smirnov test. When comparing independent groups of continuous

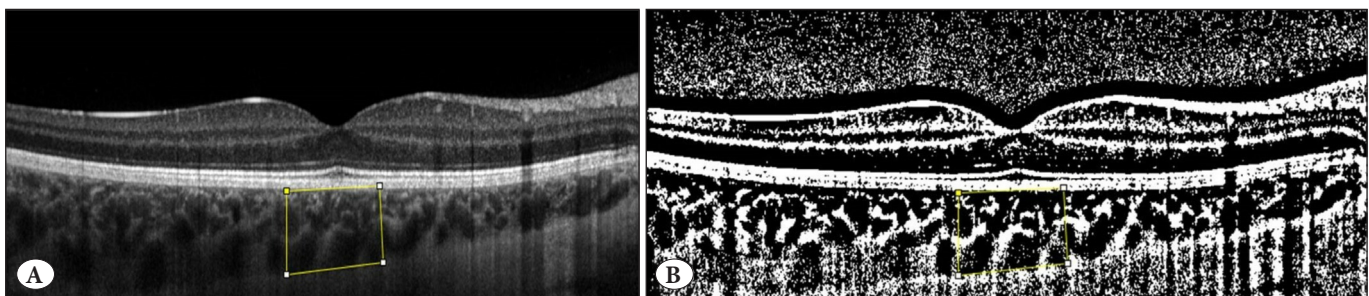
variables, data with a normal distribution were analyzed using one-way ANOVA, while data with non-normal distributions were subjected to the Kruskal Wallis test. The categorical variables were compared between groups using the Chi-Square test. If necessary, pairwise comparisons were made using the Mann-Whitney U test and evaluated using the Bonferroni correction. Statistical significance was defined as  $p < 0.05$ . G-Power 3.1.9.7 software was used for a power analysis, which revealed a power of 81.1% to detect an effect size of  $f = 0.3$  with a total sample size of 80 for the four groups.

### RESULTS

The demographic, anthropometric, and ocular characteristics of the children in control and study groups (20 children for each SDS group) are shown in Table 1. No statistically significant differences between groups were found in terms of age, gender distribution, and axial length ( $p = 0.504$ ,  $p = 0.493$ , and  $p = 0.805$  respectively). Of the children in the study group, 44 (73%) had insulin resistance, 25 (41%) had dyslipidemia, and 15 (25%) had metabolic syndrome. The distribution of comorbidities in obese children is shown in Table 2.

Measurements of choroidal structural parameters are shown in Table 3. The medians (min-max) of SFCT in healthy, overweight, obese, and morbid-obese children were 398.5 (319.0-453.5)  $\mu\text{m}$ , 299.0 (274.7-387.0)  $\mu\text{m}$ , 295.5 (257.0-385.0)  $\mu\text{m}$ , and 304.5 (272.2-386.0)  $\mu\text{m}$  respectively. Children in the study group had thinner SFCT compared to non-obese healthy children ( $p = 0.032$ ). There was no statistical correlation between the severity of obesity and SFCT ( $p = 0.722$ ). The groups showed no significant differences regarding CVI, TCA, LA, and SA ( $p = 0.710$ ,  $p = 0.452$ ,  $p = 0.221$ , and  $p = 0.863$ , respectively).

The effects of comorbidities on choroidal parameters in obese children are shown in Figure 2 and Figure 3. Obese children with dyslipidemia had lower SFCT than those without dyslipidemia ( $292.0$  (166-431)  $\mu\text{m}$  vs  $348.0$  (173-491)  $\mu\text{m}$ ,  $p = 0.003$ ), while neither IR nor MS had



**Figure 1:** Representative of an EDI-OCT image binarization. A) EDI-OCT image of a participant, B) Binarized image with the area of interest outlined.

**Table 1:** Demographic and anthropometric data of participants.

	Control Group		Study Group		P
	Healthy (n=20)	Overweight (n=20)	Obese (n=20)	Morbid-obese (n=20)	
Age, years±SD	10.5±0.7	11.0±5.6	11.0±2.1	11.82±5.6	<b>0.504*</b>
Gender					
Female	10	12	14	11	<b>0.493**</b>
Male	10	8	6	9	
Weight, kg±SD	42.1±16.6	52.3±13.4	65.6±13.9	81.6±22.3	<b>&lt;0.001*</b>
Height, cm±SD	146.6±18.5	149.7±9.8	151.0±11.0	151.9±9.6	<b>0.393*</b>
BMI-SDS±SD	0.1±0.7	1.6±0.2	2.5±0.1	3.3±0.4	<b>&lt;0.001*</b>
Axial length, mm±SD	22.96±0.9	23.11±0.1	23.30±0.6	23.10±0.06	<b>0.805*</b>

BMI-SDS: Body mass index standard deviation score, \*ANOVA test, \*\*Chi-square test.

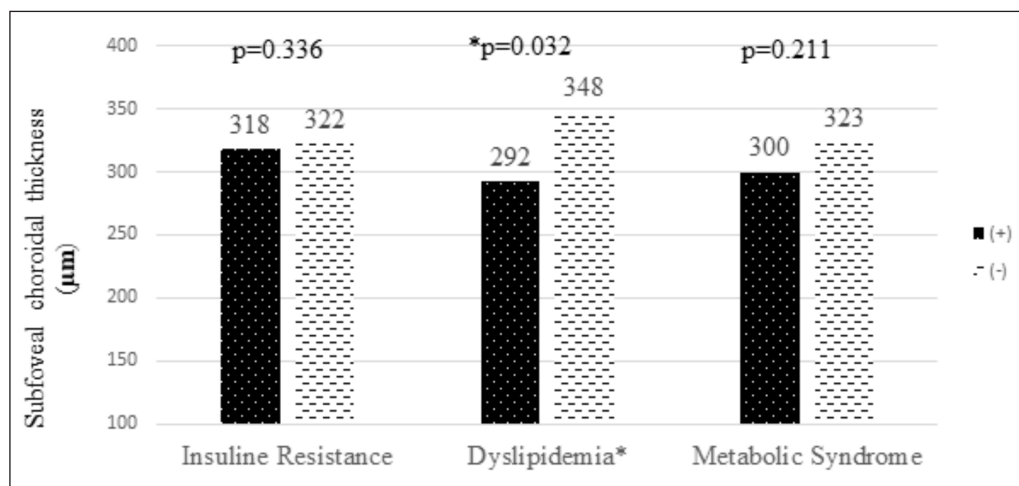
**Table 2:** Frequencies of comorbidities in the study group.

Comorbidities	Overweight (n=20)	Obese (n=20)	Morbid-Obese (n=20)	Total (n=60)
Insulin Resistance	15 (75%)	16 (80%)	12 (60%)	43 (73%)
Dyslipidemia	8 (40%)	9 (45%)	8 (40%)	25 (41%)
Metabolic Syndrome	7 (35%)	4 (20%)	2 (10%)	13 (21%)

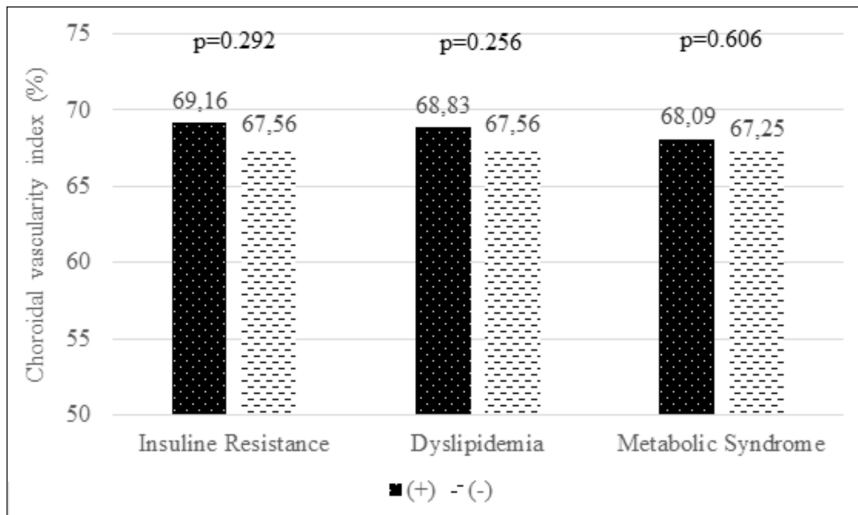
**Table 3:** Choroidal parameters according to the obesity severity.

	Control Group		Study Group		p*
	Healthy (n=20)	Overweight (n=20)	Obese (n=20)	Morbid-obese (n=20)	
SFCT, $\mu\text{m}$	398.50 (319.0-453.5)	299.00 (274.7-387.0)	295.50 (257.0-385.0)	304.50 (272.2-386.0)	0.032
CVI (%)	67.61 (66.5-70.5)	66.87 (64.1-69.1)	67.85 (64.2-71.0)	67.56 (66.2-69.5)	0.714
TCA, $\text{mm}^2$	0.47 (0.45-0.60)	0.45 (0.38-0.52)	0.51 (0.42-0.60)	0.49 (0.46-0.57)	0.456
LA, $\text{mm}^2$	0.32 (0.30-0.39)	0.30 (0.25-0.34)	0.35 (0.29-0.38)	0.33 (0.30-0.38)	0.224
SA, $\text{mm}^2$	0.14 (0.13-0.20)	0.15 (0.11-0.19)	0.15 (0.12-0.19)	0.16 (0.14-0.20)	0.862

SFCT: Subfoveal choroidal thickness, CVI: Choroidal vascularity index, TCA: Total choroidal area, LA: Luminal area, SA: Stromal area, \*Kruskal Wallis test.

**Figure 2:** Effect of comorbidities on subfoveal choroidal thickness. Participants with dyslipidemia had lower subfoveal choroidal thickness. Having insulin resistance or metabolic syndrome had no effect on subfoveal choroidal thickness.

+: Having the co-morbidity; -: Not having the co-morbidity. Mann-Whitney U test



**Figure 3:** Effect of comorbidities on choroidal vascularity index. None of the comorbidities had a significant effect on the choroidal vascularity index in the study group.

+: Having the co-morbidity; -: Not having the co-morbidity. Mann-Whitney U test

a significant effect on SFCT ( $p=0.336$ ,  $p=0.211$ , respectively) (Figure 2). The presence of IR, dyslipidemia, or MS also had no significant effect on CVI in the study group ( $p=0.472$ ,  $p=0.253$ , and  $p=0.602$ , respectively) (Figure 3).

## DISCUSSION

The present study found that overweight and obese children have thinner SFCT compared to healthy children. However, there was no relationship between the severity of obesity and SFCT. In addition, no significant differences in CVI, TCA, LA, and SA were observed between groups.

Obesity is a multifactorial condition and affects several organ systems. It has been reported that atherosclerotic changes in the macrovascular system such as increased intima-medial thickness and arterial stiffness begin even in childhood (24,25). Takiuchi et al. also revealed that obesity-associated microvascular and macrovascular alterations are related (26). Structural changes in the retinal vasculature of obese people without hypertension and diabetes were also documented in the Blue Mountains Eye Study (27). The same microvascular deterioration was also observed in obese children (28, 29). Tenlik et al. also revealed that thicknesses of macular ganglion cell-inner plexiform layer and the retinal nerve fiber layer were inversely correlated with the severity and duration of childhood obesity (30).

In addition to retinal vasculature, the choroid had been also evaluated to reflect microvascular changes in obesity but the results are controversial. The Copenhagen Child Cohort 2000 Eye Study showed that SFCT increased with height in both boys and girls, and with weight in girls only, but no correlations were observed between SFCT and BMI (31).

In contrast, some recent studies revealed that compared to healthy controls, obese children's choroids were noticeably thinner (12-14). Our results also showed significant choroidal thinning in obese children in comparison to healthy subjects.

Sympathetic and parasympathetic mechanisms play a pivotal role in regulating of the choroidal circulation (32). High BMI is known to disrupt these vasoregulation mechanisms by increasing vasoconstrictor molecules such as angiotensin-II and endothelin-1, and reducing vasodilators such as NO (33,34). The decrease in NO levels can lead to increased choroidal vascular resistance, reduced blood flow, and ultimately decreased choroidal thickness (35-37). The other proposed histopathological theory for microvascular damage is based on the oxidative stress phenomenon, in which the overproduction of free oxygen radicals due to increased mitochondrial and peroxisomal fatty acid oxidation results in interaction with proteins, large molecules like DNA, and ultimately results in vascular endothelial cell impairment (38).

In the current study, it's found that obese children had lower SFCT than healthy controls. In addition to the possible mechanisms written above having comorbidities such as IR and dyslipidemia may also affect the results. Esmalpour et al. showed a significant SFCT thinning in diabetic adults without retinopathy, suggesting that diabetic choroidopathy may begin before diabetic retinopathy (39). We also found that obese children with dyslipidemia, which is another atherosclerotic risk factor, had thinner SFCT. In our cohort, a significant proportion of obese children had IR (73%) and dyslipidemia (41%). By this aspect, these comor-

bidities may have an additional effect on choroidal thinning in obese children.

There are few studies evaluating the association between CVI and obesity and they both revealed no significant change in CVI with rapid weight loss with surgery in morbidly obese patients (40,41). Similarly, the present study showed no significant change in the CVI by obesity and its degree. Although a notable decrease was observed in SFCT, the lack of significant changes in TCA and LA suggests that the vascular region in the choroid is affected at a similar rate to the stromal region.

This study has a number of limitations. First, even though the sample size is sufficient to make statistical inferences, it may be relatively small to apply the findings to all obese children. More comprehensive investigations with larger study populations and epidemiological data may produce more reliable findings. Second, OCT measurement variability and imperfections could introduce bias. Therefore, more sophisticated methods are required to study choroidal tissue. Finally, due to the cross-sectional design of the present study, a prospective investigation with a longer follow-up time might yield more accurate results and implications for the future.

To our knowledge, this is the first study to investigate the effects of childhood obesity on CVI. These results, showing a decrease in SFCT without a significant change in CVI despite varying obesity severity, are important for understanding how childhood obesity affects choroidal structure and vascularization.

#### Acknowledgments

Special thanks to Dr. Esra Gultekin for the statistical analysis.

#### Author Contributions

Study design: **Serdar Bilici, Meliha Esra Bilici**, Data collection: **Tuba Gültekin-Erol, Meliha Esra Bilici**, Data analysis: **Serdar Bilici, Tuba Gültekin-Erol**, Reviewing of the literature: **Serdar Bilici**; Writing: **Serdar Bilici, Tuba Gültekin-Erol, Meliha Esra Bilici**, Critical revision: **Silay Cantürk-Uğurbaşı, Suat Hayri Uğurbaşı**.

#### Conflict of Interest

We declare that we have no conflict of interest.

#### Financial Support

No financial support was received.

#### Ethical Approval

This study was approved by Zonguldak Bülent Ecevit University Ethics Committee (2022/06-09).

#### Peer Review Process

Extremely and externally peer-reviewed and accepted.

## REFERENCES

1. Kosti RI, Panagiotakos DB. The epidemic of obesity in children and adolescents in the world. *Cent Eur J Public Health*. 2006;14:151-159.
2. Jiang SZ, Lu W, Zong XF, Ruan HY, Liu Y. Obesity and hypertension. *Exp Ther Med*. 2016;12:2395-2399.
3. Ortega FB, Lavie CJ, Blair SN. Obesity and cardiovascular disease. *Cir Res*. 2016;118:1752-1770.
4. Tutunchi H, Naeini F, Ebrahimi-Mameghani M, Mobasseri M, Naghshi S, Ostadrahimi A. The association of the steatosis severity, NAFLD fibrosis score and FIB-4 index with atherogenic dyslipidaemia in adult patients with NAFLD: A cross-sectional study. *Int J Clin Pract*. 2021;75:14131.
5. Alim S, Demir AK. Diyabetik Maküla Ödemi Tedavisinde Serum HbA1c Düzeyinin İntravitreal Anti-VEGF Tedavisine Etkisi. *Turk J Diab Obes*. 2019;3:79-83.
6. Küçük N, Alpay A. The Effect of Dexamethasone Implant on Retinal Nerve Fiber Layer and Optic Nerve Cup-to-Disk Ratio in Patients with Diabetic Macular Edema. *Turk J Diab Obes*. 2022;6:143-148.
7. Bilici S, Selçuk N, Gültekin-Erol T, Uğurbaşı SH. COVID-19 Karantina Sürecinin Diyabetik Maküla Ödemi Tedavisine Etkileri. *Turk J Diab Obes*. 2023;7:122-127.
8. Ciccone MM, Miniello V, Marchioli R, Scicchitano P, Cortese F, Palumbo V, Primitivo SG, Sassara M, Ricci G, Carbonara S, Gesualdo M, Diaferio L, Mercurio G, De Pergola G, Giordano P, Favale S. Morphological and functional vascular changes induced by childhood obesity. *Eur J Cardiovasc Prev Rehabil*. 2011;18(6):831-835.
9. Barton M, Baretella O, Meyer MR. Obesity and risk of vascular disease: importance of endothelium-dependent vasoconstriction. *Br J Pharmacol*. 2012;165:591-602.
10. Bulus AD, Can ME, Baytaroglu A, Can GD, Cakmak HB, Andiran N. Choroidal Thickness in Childhood Obesity. *Ophthalmic Surg Lasers Imaging Retina*. 2017;48:10-17.
11. Aydemir GA, Aydemir E, Asik A, Bolu S. Changes in ocular pulse amplitude and choroidal thickness in childhood obesity patients with and without insulin resistance. *Eur J Ophthalmol*. 2022;32:2018-2025.
12. Topcu-Yilmaz P, Akyurek N, Erdogan E. The effect of obesity and insulin resistance on macular choroidal thickness in a pediatric population as assessed by enhanced depth imaging optical coherence tomography. *J Pediatr Endocrinol Metab*. 2018;31:855-860.
13. Erşan I, Battal F, Aylanç H, Kara S, Arıkan S, Tekin M, Gencer B, Tufan HA. Noninvasive assessment of the retina and the choroid using enhanced-depth imaging optical coherence tomography shows microvascular impairments in childhood obesity. *JAAPOS*. 2016;20:58-62.
14. Uslu Dogan C, Culha D. Subfoveal choroidal thickness and peripapillary retinal nerve fiber layer thickness in young obese males. *Eur J Ophthalmol*. 2021;31:3190-3195.

15. Öncül H, Çağlayan M, Fuat Alakus M, Yılmaz Öncül F, Dag U, Arac E, Metin K. Evaluation of the subfoveal choroidal and outer retinal layer thickness in obese women. *Clin Exp Optom*. 2021;104:178-186.
16. Gupta P, Jing T, Marziliano P, Cheung CY, Baskaran M, Lamoureux EL, Wong TY, Cheung CM, Cheng CY. Distribution and determinants of choroidal thickness and volume using automated segmentation software in a population-based study. *Am J Ophthalmol*. 2015;159:293-301.
17. Sansom LT, Suter CA, McKibbin M. The association between systolic blood pressure, ocular perfusion pressure and subfoveal choroidal thickness in normal individuals. *Acta Ophthalmol*. 2016;94:157-158.
18. Iovino C, Pellegrini M, Bernabei F, Borrelli E, Sacconi R, Govetto A, Vagge A, Di Zazzo A, Forlini M, Finocchio L, Carnevali A, Triolo G, Giannaccare G. Choroidal Vascularity Index: An In-Depth Analysis of This Novel Optical Coherence Tomography Parameter. *J Clin Med*. 2020;9:595.
19. Bundak R, Furman A, Gunoz H, Darendeliler F, Bas F, Neyzi O. Body mass index references for Turkish children. *Acta Paediatr*. 2006;95:194-198.
20. Matthews DR, Hosker JP, Rudenski AS, Naylor BA, Treacher DF, Turner RC. Homeostasis model assessment: insulin resistance and beta-cell function from fasting plasma glucose and insulin concentrations in man. *Diabetologia*. 1985;28:412-419.
21. Styne DM, Arslanian SA, Connor EL, Farooqi IS, Murad MH, Silverstein JH, Yanovski JA. Pediatric Obesity-Assessment, Treatment, and Prevention: An Endocrine Society Clinical Practice Guideline. *J Clin Endocrinol Metab*. 2017;102(3):709-757.
22. Zimmet P, Alberti KG, Kaufman F, Tajima N, Silink M, Arslanian S, Wong G, Bennett P, Shaw J, Caprio S; IDF Consensus Group. The metabolic syndrome in children and adolescents - an IDF consensus report. *Pediatr Diabetes*. 2007;8:299-306.
23. Tan KA, Laude A, Yip V, Loo E, Wong EP, Agrawal R. Choroidal vascularity index - a novel optical coherence tomography parameter for disease monitoring in diabetes mellitus? *Acta Ophthalmol*. 2016;94:612-616.
24. Järvisalo MJ, Jartti L, Näntö-Salonen K, Irjala K, Rönnemaa T, Hartiala JJ, Celermajer DS, Raitakari OT. Increased aortic intima-media thickness: a marker of preclinical atherosclerosis in high-risk children. *Circulation*. 2001;104(24):2943-2947.
25. Armstrong KR, Cote AT, Devlin AM, Harris KC. Childhood obesity, arterial stiffness, and prevalence and treatment of hypertension. *Curr Treat Options Cardiovasc Med*. 2014;16:339.
26. Takiuchi S, Kamide K, Miwa Y, Tomiyama M, Yoshii M, Matayoshi T, Horio T, Kawano Y. Diagnostic value of carotid intima-media thickness and plaque score for predicting target organ damage in patients with essential hypertension. *J Hum Hypertens*. 2004;18(1):17-23.
27. Wang JJ, Taylor B, Wong TY, Chua B, Rochtchina E, Klein R, Mitchell P. Retinal vessel diameters and obesity: a population-based study in older persons. *Obesity (Silver Spring)*. 2006;14(2):206-214.
28. Taylor B, Rochtchina E, Wang JJ, Wong TY, Heikal S, Saw SM, Mitchell P. Body mass index and its effects on retinal vessel diameter in 6-year-old children. *Int J Obes (Lond)*. 2007;31(10):1527-1533.
29. Kurniawan ED, Cheung CY, Tay WT, Mitchell P, Saw SM, Wong TY, Cheung N. The relationship between changes in body mass index and retinal vascular caliber in children. *J Pediatr*. 2014;165:1166-1171.
30. Tenlik A, Kulak AE, Güler E, Totan Y, Güragaç FB, Boyraz M. Evaluation of Ganglion Cell-Inner Plexiform and Retinal Nerve Fiber Layer Thicknesses in Obese Children and Their Associations with Obesity Severity and Duration. *Turk J Diab Obes*. 2018;2:29-34.
31. Li XQ, Jeppesen P, Larsen M, Munch IC. Subfoveal choroidal thickness in 1323 children aged 11 to 12 years and association with puberty: the Copenhagen Child Cohort 2000 Eye Study. *Invest Ophthalmol Vis Sci*. 2014;55:550-555.
32. Nilsson SF. Nitric oxide as a mediator of parasympathetic vasodilation in ocular and extraocular tissues in the rabbit. *Invest Ophthalmol Vis Sci*. 1996;37:2110-2119.
33. Stapleton PA, James ME, Goodwill AG, Frisbee JC. Obesity and vascular dysfunction. *Pathophysiology*. 2008;15:79-89.
34. Kamide K. Role of Renin-Angiotensin-Aldosterone System in Metabolic Syndrome and Obesity-related Hypertension. *Curr Hypertens Rev*. 2014 Aug 12. Epub ahead of print.
35. Sekaran S, Cunningham J, Neal MJ, Hartell NA, Djamgoz MB. Nitric oxide release is induced by dopamine during illumination of the carp retina: serial neurochemical control of light adaptation. *Eur J Neurosci*. 2005;21:2199-2208.
36. Schmetterer L, Krejcy K, Kastner J, Wolzt M, Gouya G, Findl O, Lexer F, Breiteneder H, Fercher AF, Eichler HG. The effect of systemic nitric oxide-synthase inhibition on ocular fundus pulsations in man. *Exp Eye Res*. 1997;64(3):305-312.
37. Reitsamer HA, Zawinka C, Branka M. Dopaminergic vasodilation in the choroidal circulation by d1/d5 receptor activation. *Invest Ophthalmol Vis Sci*. 2004;45:900-905.
38. Murata T, Nagai R, Ishibashi T, Inomuta H, Ikeda K, Horiuchi S. The relationship between accumulation of advanced glycation end products and expression of vascular endothelial growth factor in human diabetic retinas. *Diabetologia*. 1997;40:764-769.
39. Esmaelpour M, Považay B, Hermann B, Hofer B, Kajic V, Hale SL, North RV, Drexler W, Sheen NJ. Mapping choroidal and retinal thickness variation in type 2 diabetes using three-dimensional 1060-nm optical coherence tomography. *Invest Ophthalmol Vis Sci*. 2011;52(8):5311-5316.
40. Agarwal A, Saini A, Mahajan S, Agrawal R, Cheung CY, Rastogi A, Gupta R, Wang YM, Kwan M, Gupta V; OCTA Study Group. Effect of weight loss on the retinochoroidal structural alterations among patients with exogenous obesity. *PLoS One*. 2020;15(7):e0235926.
41. Ozelcik-Kose A, Imamoglu S, Aktekin A, Balci S, Yıldız MB, Ozturk Y, Yenerel NM. Effect of bariatric surgery on macular and peripapillary choroidal structures in young patients with morbid obesity. *Can J Ophthalmol*. 2022;57(6):370-375.