




Evaluation of Symmetry of Ventrodorsal Pelvic Radiographs in Dogs; A Retrospective Study

İsmail Gökçe YILDIRIM^{1*} 

¹Aydın Adnan Menderes University, Faculty of Veterinary Medicine, Department of Anatomy, Aydın, TÜRKİYE

ABSTRACT

Pelvic radiographs in dogs have been used for assessments of pelvic bone, hip joint, and sacral bone in orthopaedic examinations. Thus, symmetric radiographs must be a goal to minimise medical errors. Despite the importance of symmetric radiographs, ventrodorsally pelvic radiographs are routinely evaluated using the symmetric appearance of the obturator foramen and wing of the ilium. This retrospective study was performed to evaluate the symmetry of pelvic radiographs in dogs. For this purpose, 100 pelvic radiographs were reevaluated by linear, area, and circumference measurements. The differences in percentages were remarkable for width and area values for both the ilium and obturator foramen between the left and right sides. In terms of the difference in the percentage of iliac wing width, two-thirds of radiographs showed asymmetry up to 20% and higher in the remaining one-third of radiographs. The findings of this research indicate that completely symmetrical positioning on pelvic radiographs is often not obtained.

Keywords: dog, pelvic asymmetry, pelvic radiograph, symmetry evaluation

Köpeklerde Ventrodorsal Pelvik Radyografilerin Simetrisinin Değerlendirilmesi; Retrospektif Bir Çalışma

ÖZET

Köpeklerde pelvik radyografiler ortopedik muayenede pelvik kemik, kalça eklemi ve sakral kemiğin değerlendirilmesinde kullanılmaktadır. Bu nedenle tıbbi hataları en aza indirmek için simetrik radyografiler hedef olmalıdır. Simetrik radyografilerin önemine rağmen, ventrodorsal pelvik radyografiler rutin olarak foramen obturatum ve ala osis ili'nin simetrik görünümlerinin karşılaştırılması ile değerlendirilir. Bu retrospektif çalışma köpeklerde pelvik radyografilerin simetrisini değerlendirmek amacıyla yapıldı. Bu amaçla 100 pelvik radyografi lineer, alan ve çevre ölçüleriyle yeniden değerlendirildi. Sol ve sağ taraflar arasında hem foramen obturatum hem de ala osis ili'nin genişlik ve alan değerleri açısından yüzdelerdeki farklılıklar dikkat çekiciydi. Ala osis ili'nin genişliği arasındaki farka bakıldığında radyografilerin üçte ikisinde %20'ye varan asimetri ve geri kalan üçte birinde daha yüksek asimetri görüldü. Bu araştırmanın bulguları, pelvik radyografilerde tam simetrik konumlandırmanın sıklıkla elde edilemediğini göstermektedir.

Anahtar kelimeler: köpek, pelvik asimetri, pelvik radyografi, simetri değerlendirmesi

*Corresponding author: İsmail Gökçe YILDIRIM, Aydın Adnan Menderes University, Faculty of Veterinary Medicine, Department of Anatomy, Aydın, TÜRKİYE. gyildirim@adu.edu.tr

Received Date: 13.12.2023 - Accepted Date: 14.03.2024

DOI: 10.53913/aduveterinary.1404484

Introduction

Radiographic measurements are commonly employed to assess both normal and abnormal skeletal relationships (Rowe and Yochum, 2005). Primarily, ventrodorsal pelvic radiographs are utilized for evaluating pelvic bone structures (Schrader, 1986; Dyce et al., 2001; Thompson et al., 2007; Renwick et al., 2011), hip joint conditions (Rasmussen et al., 1998; Tomlinson and Johnson, 2000; Doskarova et al., 2010), and the sacrum (Pare et al., 2001; Breit et al., 2002). Ventrodorsal images of the pelvis are frequently employed for diagnostic purposes, especially in cases of hip dysplasia (Dennis, 2012). Ventrodorsal pelvic radiographs serve as a valuable tool for clinicians, orthopaedic specialists, and veterinary professionals. Their detailed visualization aids in identifying skeletal abnormalities and guiding appropriate treatment strategies.

Some conditions significantly impact the symmetry and structural integrity of the pelvis. Juvenile pubic symphysiodesis (JPS), a surgical procedure, induces pelvic changes that become evident through radiography in adult dogs (Boiocchi et al., 2013). Additionally, lumbosacral transitional vertebrae (LTV) are commonly observed in German shepherd dogs and can disrupt the pelvis's normal structure (Komsta et al., 2015). Following an LTV, asymmetrical hip conformation may occur, potentially exacerbating genetically influenced canine hip dysplasia (Flückiger et al., 2017). These alterations, affecting pelvic symmetry and structure, hold clinical significance. However, it's essential to recognize that even in healthy pelvis radiographs without observable conditions, asymmetric images due to positioning can lead to potential misdiagnosis.

Radiographic pelvic views must adhere to precise positioning rules to ensure high-quality images for medical analysis (Ginja et al., 2010). Quantitative measurements obtained from radiographs can be influenced by various factors, including accurate positioning, variations in canine body conformation, image quality, sharpness, identification of reference points, and the observer's experience (Thrall, 2018). Consequently, the risk of errors in quantifying radiographic assessments is multifactorial. Therefore, achieving symmetric radiographs becomes essential to minimize medical inaccuracies (Dennis, 2012).

Conventional ventrodorsal hip extended radiographs are widely used worldwide (James et al., 2020). Despite the emphasis on symmetry, ventrodorsal pelvic radiographs are routinely evaluated based on the symmetrical appearance of the obturator foramen and the ilium's wing (Delanuay et al., 1997; Renberg et al., 2000; Tomlinson and Johnson, 2000; Breit et al., 2002).

The main aim of this retrospective study is to re-evaluate canine ventrodorsal radiographs, with a special focus on pelvic symmetry. To achieve this, a series of linear, area, and circumferential measurements of the pelvis were used. The aim is not to investigate quantitative differences between the two sides of the pelvis; rather, it is an elucidation of the symmetry present in canine pelvic

radiographs. By doing this, attention can be drawn to potential variations that could affect diagnostic accuracy.

Materials and Methods

The study primarily utilized X-rays from mostly German shepherd dogs, representing nine different breeds. These dogs were medium to large-sized, with an average weight of 30.24 kg (SD 6.54). Most were at least 7 months old, except for one Labrador retriever, which was 5 months old. The gender distribution was 43% female and 57% male (Table 1).

In this study, standard ventrodorsal hip radiographs were used from the archives of Aydin Adnan Menderes University Faculty of Veterinary Medicine (compiled between 2010 and 2013). To ensure consistent conditions, the same surgeon and technician performed all radiographs without the use of anaesthesia. 100 radiographs were selected that showed no signs of hip dysplasia or similar orthopaedic diseases from the archived collection. Selection criteria were including two key factors: symmetrical views of both the obturator foramen and ilial wings, and the absence of radiographic evidence of degenerative joint disease in the hips. Priority was also given to excluding diseases that could cause asymmetry or structural deterioration in the pelvis. This approach aimed to minimize defects that might impact pelvic symmetry and result in an asymmetrical appearance.

The radiographs were scanned (Mustek A3 II T) and transferred to the personal computer as JPEG images, with fixed scale and resolution. On these images, four landmark points were marked on the cranial margin of sacroiliac joint and cranial acetabular rim (Urban et al., 2011) of both sides using Corel Draw software. Then, two axes were drawn between these points to standardize ilial wing width (IWW) and dorsal acetabular width (DAW) measurements. Width, length, circumference, and area measurements were taken after millimetric calibration by using Vet Eickemeyer® Medizintechnik für Tierärzte (EIVIS). Measurements are given in table 2 and figure 1. All images were analyzed by the same person (IGY).

Statistical analysis was performed using the SPSS statistical package program (SPSS version 20.0 SPSS, IBM, NY, USA). Mean values (MV) and standard deviations (SD) were calculated as descriptive statistics.

The greater values of ilial wing width from each radiograph were pooled and named as the wide sides while the other side of the same radiograph was named as the narrow side. Two sides were compared with the paired-t test. Additionally, four groups were formed according to percentage differences between wide and narrow sides of ilial wing width: 0-10% (group 1), 10.1-20% (group 2), 20.1-30% (group 3), and higher than 30.1% (group 4). The values of these groups were subjected to one-way analysis of variance (ANOVA). When intergroup differences were statistically significant, the Duncan test was used to determine from which group differences originated. P values <0.05 were considered significant for all analyses.

Table 1. Some descriptive characteristics of the dogs

Breed	n	Sex		Weight (kg)			Age (month)		
		male	female	Mean (SD)	min.	max.	Mean (SD)	min.	max.
German Shepherd	54	32	22	32.01(4.28)	25	40	22.78 (3.07)	7	103
Labrador Retriever	21	12	9	30.00 (7.63)	14	42	17.15 (2.05)	5	38
Belgian Malinois	9	5	4	24.11 (4.51)	18	32	21.33 (4.39)	9	50
Pointer	6	2	4	19.16 (4.53)	12	25	33.67 (10.34)	7	63
Anatolian Shepherd	3	2	1	40.00 (8.00)	32	48	52.33 (22.45)	26	97
English Setter	3	2	1	29.33 (7.09)	23	37	39.50 (18.50)	21	58
Doberman Pinscher	2	1	1	33.00 (5.65)	29	37	33.00 (15.00)	18	48
Rottweiler	1	-	1	32.00 (0.00)	-	-	24.00 (0.00)	-	-
Boxer	1	1	-	27.00 (0.00)	-	-	27.00 (0.00)	-	-
Total	100	57	43	30.24 (6.54)	12	48	23.77 (19.70)	5	103

Table 2. The descriptive of the measurements studied

Trait	Abbreviation	Units	Description
Iliac wing width	IWW	mm	Iliac width on the axis between cranial margin of the sacroiliac joint
Dorsal acetabular width	DAW	mm	Acetabular width on the axis between cranial acetabular rim
Ischial width	IW	mm	Ischial width between lateral ischiatic tuberosity and caudal end of ischiatic symphysis
Foramen obturatum width	FOW	mm	Widest width of obturator foramen, perpendicular to the FOL
Foramen obturatum length	FOL	mm	Longest length of obturator foramen
Area of obturator foramen	FOA	mm ²	Foramen obturatum area
Area of ilium	IA	mm ²	Os ilium area
Circumference of obturator foramen	FOC	mm	Foramen obturatum circumference
Circumference of ilium	IC	mm	Os ilium circumference

Table 3. Comparison of measurements between wide and narrow sides (mean and standard deviation)

Measurements	Units	n	Wide side	Narrow side	Differences (%)	t	P
Iliac wing width	mm	100	29.89 (4.75)	24.95 (4.72)	16.18	13.543	<0.0001
Dorsal acetabular width	mm	100	26.07 (2.53)	24.77 (2.37)	4.59	6.148	<0.0001
Length of obturator foramen	mm	100	39.15 (4.46)	40.31 (4.74)	-3.12	-4.970	<0.0001
Width of obturator foramen	mm	100	20.99 (3.21)	24.03 (3.25)	-15.91	-9.871	<0.0001
Ischial width	mm	100	73.23 (6.99)	76.21 (6.84)	-4.34	-6.156	<0.0001
Area of ilium	mm ²	100	3020.38 (579.03)	2595.84 (548.56)	13.66	12.031	<0.0001
Area of obturator foramen	mm ²	100	628.83 (149.91)	737.66 (175.33)	-18.64	-9.516	<0.0001
Circumference of ilium	mm	100	303.90 (28.49)	299.13 (28.50)	1.57	7.757	<0.0001
Circumference of obturator foramen	mm	100	99.18 (11.52)	104.11 (12.32)	-5.12	-8.161	<0.0001

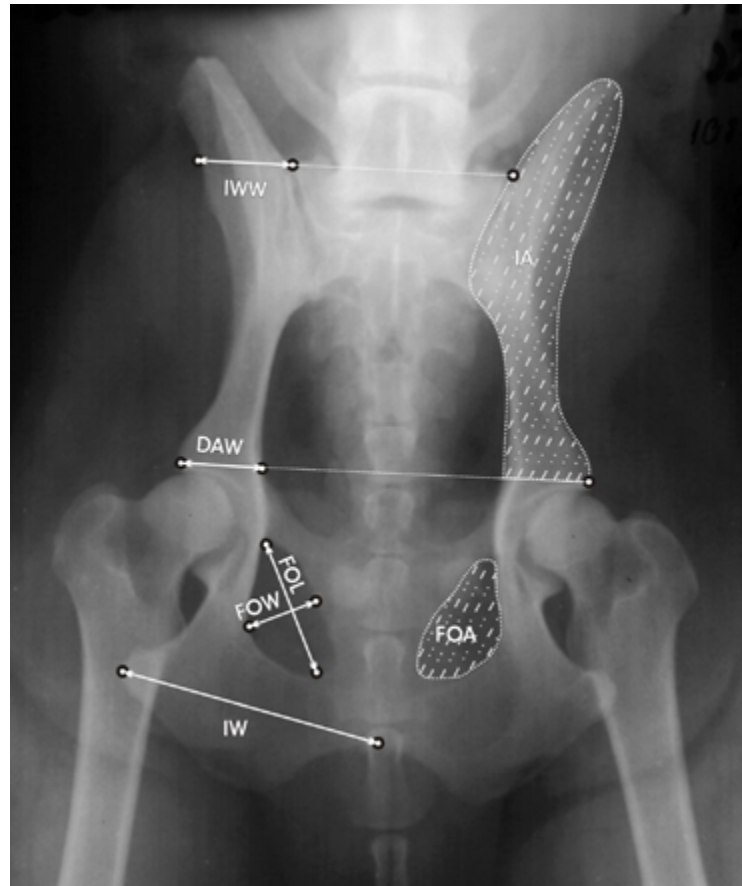


Figure 1: Measurement axes and variables of radiograph. Abbreviations are the same in Table 2

Table 4. Comparison of measurements among four groups (*) according to differences of percentage of ilial wing width (mean and standard deviation)

Measurements	Units	n	Group 1	n	Group 2	n	Group 3	n	Group 4	P
Iliac wing width	mm	34	4.50 (3.18) ^a	32	15.00 (2.81) ^b	21	24.81 (3.43) ^c	13	35.71 (3.26) ^d	<0.0001
Dorsal acetabular width	mm	34	1.56 (9.69) ^a	32	3.46 (5.82) ^{ab}	21	7.40 (10.07) ^{bc}	13	10.79 (4.31) ^c	<0.003
Length of obturator foramen	mm	34	-2.48 (5.65)	32	-1.47 (3.64)	21	-5.43 (10.22)	13	-5.12 (7.86)	<0.123
Width of obturator foramen	mm	34	-6.75(14.90) ^a	32	-13.48(15.33) ^a	21	-24.25(13.03) ^b	13	-32.38(10.95) ^b	<0.0001
Ischial width	mm	34	-1.88 (4.46) ^a	32	-4.54 (5.05) ^a	21	-4.92 (10.47) ^a	13	-9.30 (4.07) ^b	<0.006
Area of ilium	mm ²	34	3.71 (6.45) ^a	32	12.59 (4.99) ^b	21	21.25 (5.77) ^c	13	30.04 (6.12) ^d	<0.0001
Area of obturator foramen	mm ²	34	-8.15(15.67) ^a	32	-17.20(18.70) ^a	21	-27.91(17.70) ^b	13	-34.66(17.35) ^b	<0.0001
Circumference of ilium	mm	34	0.18 (1.40) ^a	32	1.86 (1.37) ^b	21	2.38 (1.61) ^{bc}	13	3.14 (2.88) ^c	<0.0001
Circumference of obturator foramen	mm	34	-2.78 (5.78) ^a	32	-3.93 (5.54) ^a	21	-7.79 (5.94) ^b	13	-9.83 (6.67) ^b	<0.0001

* The groups represent the percentage differences between the wide and narrow sides of ilial wing width: 0-10% (group 1), 10.1-20% (group 2), 20.1-30% (group 3) and higher than 30.1% (group 4).

^{a,b,c,d}: Different letters in the same line are statistically significant (P<0.05).

Results

The obturator foramen and ilial wing looked the same on all 100 radiographs, so they were all thought to be symmetrical when the radiographs selected. However, in 99 of those 100 radiographs, the ilial wing width (IWW) value was different on the right and left sides. The right side had a greater value in 67 radiographs compared to 32 radiographs on the left side ($P < 0.001$). In only one radiograph, both sides had the same value, indicating perfect symmetry for this measurement.

The data in the tables is presented based on the IWW (ilial wing width) value rather than distinguishing between right and left sides. Regardless of side, all obtained values were categorized as either wide or narrow edges, corresponding to large and small IWW values. Notably, various variables showed significant differences between the wide and narrow sides. Specifically, acetabular and ilial values were higher on the wide side, while ischial and obturator values were smaller. The reverse pattern was observed on the narrow side. Percentage differences in IWW, obturator foramen width (FOW), obturator foramen area (FOA), and ilium area (IA) values were particularly remarkable (Table 3).

By analyzing the percentage differences in IWW (ilial wingspan) between wide and narrow edges, it was notable that two-thirds of the radiographs exhibited asymmetry of up to 20%. In the remaining one-third of radiographs, this percentage was notably higher, especially ranging from 30.27% to 41.88% in 13 cases. A mere 10% difference in IWW between the wide and narrow sides led to distinct variations in IA (ilium area) and IWW values. Additionally, FOW (obturator foramen width), FOC (circumference of obturator foramen), DAW (dorsal acetabular width), and IC (circumference of ilium) values were significantly affected by more than 20% of the difference. The significant difference in ischial width (IW) value was not observed until a 30% difference. The obturator foramen length (FOL) remained unchanged and did not exhibit significant differences among the four groups (Table 4).

Discussion

The enchondral growth period of a puppy's pelvis is typically completed by the 40th week (von Pfeil and DeCamp, 2009). During this phase, excessive body weight can lead to increased loading forces, potentially causing skeletal malformations (Riser, 1975; Hawthorne et al., 2004). Additionally, it may result in asymmetric pelvis development, as seen in cases of juvenile pubic symphysiodesis and lumbosacral transitional vertebrae (Boiocchi et al., 2013; Komsta et al., 2015). While it is true that possible morphometric defects can impact image symmetry, it's important to note that a perfectly symmetrical pelvic structure may not always appear symmetric on radiographs. These situations should be considered when evaluating pelvic image symmetry in radiographs obtained from dogs presumed to be morphometrically healthy.

In the study, measurements taken from both the right

and left sides consistently showed a higher IWW (ilial wing width) value, particularly in the 67 radiographs on the right side compared to the 32 radiographs on the left side. These elevated values, more pronounced on the right side, suggest greater pelvic rotation in that direction. Possible reasons include differential force application during X-rays or the technician's right-handed dominance. The superior position of the right side aligns with axial rotation of the pelvis, where inadvertent force may have been applied to the dog's left side by a right-handed technician.

The impossibility of absolutely standardized radiographic positioning in the ventrodorsal projection of the pelvis confirmed that all measurements were statistically different between wide and narrow sides (Gibbs, 1997). The values obtained from cranial to acetabulum were greater, while the values for caudal to acetabulum were smaller, and vice versa. This is a characteristic result of pelvic geometry. Because the anatomic structures of the cranial to acetabulum are in a sagittal position, in contrast to those in the horizontal position, Therefore, increasing ilial and acetabular values and decreasing ischial and obturator values should be expected in the case of the asymmetric position of the pelvis. The differences between wide and narrow sides were noticeable in the widths and areas of the ilial wing and obturator foramen, located cranially and caudally, respectively. This finding confirms that regularly assessing pelvic symmetry is best achieved by monitoring the obturator foramen width and ilial wing width as suggested by Martins et al (2016).

The changes in symmetry of ilial wing width caused changes in all variables except the obturator foramen length. The sequence of degrees of these changes occurred in dorsal acetabular width, ilial circumference, width, area, circumference of the obturator foramen, and ischial width. In this circumstance, two findings were noteworthy: firstly, the values obtained from cranial to acetabulum were more affected than those of caudal to acetabulum, and secondly, the values of the obturator foramen did not show any statistical difference until a 20% difference in ilial wing width.

It has been reported that various measurements such as Norberg angle (Gibbs, 1997), hip dysplasia score (Martins et al., 2016), acetabular version angle, and acetabular tilt angle (Cross and Newell, 2000) may be inaccurate in asymmetric pelvic radiographs. However, the distraction index measurement may remain relatively unaffected until a 15° asymmetry is present on pelvic radiographs (Smith et al., 1990). More than one-third of the radiographs were not suitable for measuring the angles and index based on ilial flap width. Width measurements of the obturator foramen and ilium were deemed appropriate for the symmetrical evaluation of the caudal and cranial halves of the pelvis, respectively.

It is reported that quantitative measurements obtained from radiographs can be affected by various factors such as precise positioning, differences in the body structure of dogs, radiographic quality, sharpness of the image, positioning of standard reference points and the

experience of the observer (Thrall, 2018). It is important to obtain symmetrical radiographs to minimize errors (Dennis, 2012). Study findings show that it is difficult to achieve symmetry in ventrodorsal pelvis radiographs. For this purpose, it has been observed that holding devices have been developed that can help obtain standard and symmetrical images in pelvic radiographs (Santana et al., 2020). It can be thought that similar assistive devices may be useful in increasing standardization in vendor x-rays of the pelvis and preventing position-related asymmetries. Because achieving perfect symmetry on standard ventrodorsal pelvic radiographs appears to be an elusive goal.

The study was performed on films obtained from routine clinical radiographs. Because the aim was to evaluate the standard positions evaluated in clinics and the images obtained from them. Special imaging methods and positions should be used, or cadavers should be preferred, if the aim is to evaluate only pelvic symmetry.

Limitation of this study: This is a preliminary study that evaluates the achievability of symmetry in the images arising from routine shooting techniques in ventrodorsal pelvis radiographs. Although it represents a common situation, detailed multidisciplinary planning should be considered.

Conclusion

It is thought that symmetry assessment should be done objectively, and methodological studies are also necessary to determine the relationship between the degree of asymmetry and the existing diagnostic angles on pelvic radiographs of dogs.

Acknowledgments

This research was carried out using the education and research archives of Aydin Adnan Menderes University, Faculty of Veterinary Medicine, Animal Hospital. I am grateful to Prof. Murat SARIERLER and retired Professor M. Kamil OCAL for their guidance and support throughout the research.

The study summary was presented orally at the IX. National Veterinary Anatomy Congress, Kayseri, TÜRKİYE.

Conflict of interest

The author declare that they have no conflict of interest in this study.

Ethics Statement

No specific ethical and welfare committee approval was necessary because data were collected from existing hospital X-Ray records, requiring no interventions on animals.

References

- Boiocchi, S., Vezzoni, L., Vezzoni, A., Bronzo, V., & Rossi, F. (2013). Radiographic changes of the pelvis in Labrador and Golden Retrievers after juvenile pubic symphysiodesis: objective and subjective evaluation. *Veterinary and comparative orthopaedics and traumatology: V.C.O.T.*, 26(3), 218–225. <https://doi.org/10.3415/VCOT-12-06-0074>
- Breit, S. M., Knaus, I. M., & Künzel, W. W. (2002). Use of routine ventrodorsal radiographic views of the pelvis to assess inclination of the wings of the sacrum in dogs. *American Journal of Veterinary Research*, 63(9), 1220–1225. <https://doi.org/10.2460/ajvr.2002.63.1220>
- Cross, A. R., & Newell, S. M. (2000). Definition and determination of acetabular component orientation in cemented total hip arthroplasty. *Veterinary Surgery: VS*, 29(6), 507–516. <https://doi.org/10.1053/jvet.2000.17855>
- Delaunay, S., Dussault, R. G., Kaplan, P. A., & Alford, B. A. (1997). Radiographic measurements of dysplastic adult hips. *Skeletal Radiology*, 26(2), 75–81. <https://doi.org/10.1007/s002560050197>
- Dennis, R. (2012). Interpretation and use of BVA/KC hip scores in dogs. *In Practice*, 34(4), 178–194. <https://doi.org/10.1136/inp.e2270>
- Dyce, J., Wisner, E. R., Schrader, S. C., Wang, Q., & Olmstead, M. L. (2001). Radiographic evaluation of acetabular component position in dogs. *Veterinary Surgery: VS*, 30(1), 28–39. <https://doi.org/10.1053/jvet.2001.20343>
- Flückiger, M. A., Steffen, F., Hässig, M., & Morgan, J. P. (2017). Asymmetrical lumbosacral transitional vertebrae in dogs may promote asymmetrical hip joint development. *Veterinary and comparative orthopaedics and traumatology: V.C.O.T.*, 30(2), 137–142. <https://doi.org/10.3415/VCOT-16-05-0072>
- Gibbs C. (1997). The BVA/KC scoring scheme for control of hip dysplasia: interpretation of criteria. *The Veterinary Record*, 141(11), 275–284.
- Ginja, M. M., Silvestre, A. M., Gonzalo-Orden, J. M., & Ferreira, A. J. (2010). Diagnosis, genetic control and preventive management of canine hip dysplasia: a review. *Veterinary journal (London, England : 1997)*, 184(3), 269–276. <https://doi.org/10.1016/j.tvjl.2009.04.009>
- Graehler, R. A., Weigel, J. P., & Pardo, A. D. (1994). The effects of plate type, angle of ilial osteotomy, and degree of axial rotation on the structural anatomy of the pelvis. *Veterinary Surgery: VS*, 23(1), 13–20. <https://doi.org/10.1111/j.1532-950x.1994.tb00437.x>
- Hawthorne, A. J., Booles, D., Nugent, P. A., Gettinby, G., & Wilkinson, J. (2004). Body-weight changes during growth in puppies of different breeds. *The Journal of nutrition*, 134(8 Suppl), 2027S–2030S. <https://doi.org/10.1093/jn/134.8.2027S>
- Jacobson, A., & Schrader, S. C. (1987). Peripheral nerve injury associated with fracture or fracture-dislocation of the pelvis in dogs and cats: 34 cases (1978-1982). *Journal of The American Veterinary Medical Association*, 190(5), 569–572.
- James, H. K., McDonnell, F., & Lewis, T. W. (2020). Effectiveness of Canine Hip Dysplasia and Elbow Dysplasia Improvement Programs in Six UK Pedigree Breeds. *Frontiers in veterinary science*, 6, 490. <https://doi.org/10.3389/fvets.2019.00490>
- Komsta, R., Łojczyk-Szczepaniak, A., & Dębiak, P. (2015). Lumbosacral transitional vertebrae, canine hip dysplasia, and sacroiliac joint degenerative changes on ventrodorsal radiographs of the pelvis in police working German shepherd dogs. *Topics in companion animal medicine*, 30(1), 10–15. <https://doi.org/10.1053/j.tcam.2015.02.005>
- Martins, J., Colaço, B. J., Ferreira, A. J., & Ginja, M. M. (2016). Analysis of pelvic rotation on the standard hip ventrodorsal extended radiographic view. *Veterinary and Comparative Orthopaedics and Traumatology: V.C.O.T.*, 29(1), 68–74. <https://doi.org/10.3415/VCOT-15-02-0025>
- Paré, B., Gendreau, C. L., & Robbins, M. A. (2001). Open reduction of sacral fractures using transarticular implants at the articular facets of L7-S1: 8 consecutive canine patients (1995-1999). *Veterinary Surgery: VS*, 30(5), 476–481. <https://doi.org/10.1053/jvet.2001.25876>
- Rasmussen, L. M., Kramek, B. A., & Lipowitz, A. J. (1998). Preoperative variables affecting long-term outcome of triple pelvic osteotomy for treatment of naturally developing hip dysplasia in dogs. *Journal of the American Veterinary Medical Association*, 213(1), 80–85.
- Renberg, W. C., Johnston, S. A., Carrig, C. B., Budberg, S. C., Ye, K., & Veit, H. P. (2000). Evaluation of a method for experimental induction of osteoarthritis of the hip joints in dogs. *American Journal of Veterinary Research*, 61(5), 484–491. <https://doi.org/10.2460/ajvr.2000.61.484>
- Riser W. H. (1975). The dog as a model for the study of hip dysplasia. Growth, form, and development of the normal and

- dysplastic hip joint. *Veterinary Pathology*, 12(4), 234–334. <https://doi.org/10.1177/030098587501200401>
- Santana, A., Alves-Pimenta, S., Martins, J., Colaço, B., & Ginja, M. (2020). Hands-Free Conventional Radiographic Ventrodorsal Hip Extended View. *Frontiers in veterinary science*, 7, 286. <https://doi.org/10.3389/fvets.2020.00286>
- Schrader S. C. (1986). Triple osteotomy of the pelvis and trochanteric osteotomy as a treatment for hip dysplasia in the immature dog: the surgical technique and results of 77 consecutive operations. *Journal of the American Veterinary Medical Association*, 189(6), 659–665.
- Smith, G. K., Biery, D. N., & Gregor, T. P. (1990). New concepts of coxofemoral joint stability and the development of a clinical stress-radiographic method for quantitating hip joint laxity in the dog. *Journal of the American Veterinary Medical Association*, 196(1), 59–70.
- Swainson, S. W., Conzemius, M. G., Riedesel, E. A., Smith, G. K., & Riley, C. B. (2000). Effect of pubic symphysiodesis on pelvic development in the skeletally immature greyhound. *Veterinary Surgery: VS*, 29(2), 178–190. <https://doi.org/10.1111/j.1532-950x.2000.00178.x>
- Thompson, R., Roe, S. C., & Robertson, I. D. (2007). Effects of pelvic positioning and simulated dorsal acetabular rim remodeling on the radiographic shape of the dorsal acetabular edge. *Veterinary Radiology & Ultrasound: The Official Journal of the American College of Veterinary Radiology and the International Veterinary Radiology Association*, 48(1), 8–13. <https://doi.org/10.1111/j.1740-8261.2007.00196.x>
- Thrall, D. E. (2018). Textbook of Veterinary Diagnostic Radiology. Chapter 1: Radiation Protection and Physics of Diagnostic Radiology. Seventh Edition. Elsevier, USA. 16-22.
- Tomlinson, J. L., & Johnson, J. C. (2000). Quantification of measurement of femoral head coverage and Norberg angle within and among four breeds of dogs. *American Journal of Veterinary Research*, 61(12), 1492–1500. <https://doi.org/10.2460/ajvr.2000.61.1492>
- Urban, J. E., Weaver, A. A., Theivendran, K., & Stitzel, J. D. (2011). Acetabular rim profile measurement in femoroacetabular impingement patients - biomech 2011. *Biomedical Sciences Instrumentation*, 47, 118–123.
- von Pfeil, D. J., & DeCamp, C. E. (2009). The epiphyseal plate: physiology, anatomy, and trauma. *Compendium (Yardley, PA)*, 31(8), E1–E12.
- Yochum T. R. & Rowe L. J. (2005). *Yochum and rowe's essentials of skeletal radiology* (3rd ed.). Lippincott/Williams & Wilkins. 197-256.