



## RESEARCH ARTICLE

### The Effect of Single Dose Teriparatide Administration on the Early Healing Period of Bone Defects Created in the Rat Mandibular

Muhammed Fatih ÇİÇEK, DDS, PhD, Cansu Gül EFEÖĞLU KOCA, DDS, PhD

Usak University, Dentistry Faculty, Department of Oral and Maxillofacial Surgery, Turkey

#### Abstract

##### Introduction

Bone grafts are widely used in the repair of bone tissue. In recent years, studies on the use of biomaterials have become popular in order to increase the efficiency of bone grafts. In this study, the effects of local teriparatide used in different doses on bone healing were evaluated.

##### Materials - Methods

In this study, 30 male Sprague-Dawley rats were used and they were divided into 5 groups, 6 each. A critical sized defect of 5 mm in diameter was created in the mandible. Defects in Group 1 were left empty. Particulate autograft was applied to the defects in Group 2. Group 3 was applied allograft. In Groups 4 and 5, 20 µg and 40 µg teriparatide were administered with the allograft, respectively. At the postoperative 4th week, the anesthesia dose was doubled and euthanasia was performed. The samples were taken out in one piece and evaluated histomorphometrically.

##### Results

While the amount of newly formed bone tissue ( $0.28 \pm 0.01$  mm<sup>2</sup>) and the number of osteoblasts ( $41.67 \pm 1.56$ ) were significantly lower in Group 1, these values were found in Group 5 ( $0.79 \pm 0.01$  mm<sup>2</sup>), ( $77.72 \pm 3.06$ ) is significantly higher. The findings in Group 4, in which teriparatide was used ( $0.72 \pm 0.01$  mm<sup>2</sup>,  $72 \pm 4.26$ ), were significantly higher than Group 3 and Group 2. The amount of new bone formation ( $0.48$  mm<sup>2</sup>) and the number of osteoblasts ( $54.17 \pm 1.99$ ) were significantly higher in Group 3 than Group 2 ( $0.39 \pm 0.01$  mm<sup>2</sup>,  $50 \pm 1.4$ ).

##### Conclusion

As a result, it was observed that teriparatide, which was used locally in two different doses, significantly increased bone healing.

**Keywords:** bone healing, teriparatide, rat mandible

#### Introduction

Bone tissue is the only tissue that heals without scarring. Organic components make up 35% of the bone matrix. Its intermediates consist of Glycosaminoglycans, Glycoproteins. Bone glycoproteins are responsible for initiating matrix calcification.<sup>1</sup>

Since the matrix of the bone tissue is hard, it does not allow diffusion, so nutrition is through channels. These rings form a regular circular structure, 3-7 µm thick and usually around the bone canal. The nutrient transfer from the innermost layer of the bone tissue to the outermost layer is achieved with these lamellae. It consists of intertwined circular structures around the Haversian canal with a diameter of 20-100 µm and containing vascular structure.<sup>2,3</sup>

Bone formation occurs by two different mechanisms, intramembranous and chondral ossification. While flat bones ossify intramembranous, short and long bones are formed by chondral ossification.<sup>4,5</sup> As a result of the deterioration of the anatomical integrity of the bone tissue, bone healing occurs with a series of complex electrical, chemical and mechanical mechanisms. Bone healing consists of 3 stages.<sup>6</sup>

In the inflammatory phase, the occurrence of vascular endothelial damage causes platelet aggregation and secretion of vascular endothelial growth factor in the region. While the hematoma formed in the region contributes to the stabilization of the fracture line with the pressure it creates, it also initiates the necessary mechanism for healing thanks to the thrombocyte and macrophages in it. The hematoma is organized after 48 hours. The fibrin network formed

**Corresponding Author:** Muhammed Fatih ÇİÇEK

**Address:** Usak University, Dentistry Faculty, Department of Oral and Maxillofacial Surgery, 64200, Merkez, Usak, Turkey

**Phone:** +90(553) 048 00 35

**E-mail:** mmffatihcc@gmail.com ORCID: 0000-0001-9446-3433

important factor for healing thanks to the periosteum and endosteum-derived precursor cells and the framework it forms.<sup>6</sup>

One of the factors that act as a chemotactic agent for monocytes and macrophages is ESM. This environment is well suited for the function of polymorphous core leukocytes and macrophages. Since the anastomosis is disturbed between the fracture ends, circulation in this region is disturbed and necrotic areas are formed. Osteocytes undergo lysis in the region. This helps the capillary fibroblasts to form the intermediate and collagen by feeding. There is a sudden increase in the number of osteoblasts and chondroblasts coming from the endosteum and periosteum, and osteogenesis begins in the later stages.<sup>6</sup>

The repair phase begins after the fracture occurs, but manifests itself 7-12 days later. In areas close to the fracture line, blood vessels and osteogenic cells are densely located. As it moves away from the fracture ends, vascularization decreases and chondroblasts begin to appear. Gradual differentiation of the cells, accumulation of the substances they secrete and callus formation begin with the formation of ESM.<sup>6</sup>

The task of the callus is to stabilize the fracture site. The callus is soft at first and is not visible on the radiograph. Chondrocytes in the areas of cartilage tissue transform into hypertrophic chondrocytes and cartilage matrix secretion begins. Vascular development begins in the empty lacunae.<sup>6</sup>

Without calcification, there is no vascularization. Bone cells begin to migrate to the region with vascularization. With the formation of internal and external callus, the bone ends become much more stable. The formation of hard callus means that most of the healing has taken place at the fracture site.<sup>6</sup>

In remodeling, the remodeling of bone tissue takes place according to Wolff's law. As I said at the beginning of my presentation, bone healing is the only tissue that heals without scarring. Various graft materials are used to support bone formation in bone defects larger than the critical size defect. Autograft, allograft, xenograft and alloplastic bone are examples of these graft materials.<sup>6</sup>

Bone graft materials affect new bone formation at the defect site in many ways. Osteogenesis is the formation of bone in the recipient area by cellular elements in the graft material. Osteoinduction is the stimulation of pluripotent cells to transform into osteoblasts or chondroblasts by the growth factors in the graft material, and Osteoconduction is the progression of the vascular structures in the recipient area using the graft material as a skeleton and moving into it. Autografts are accepted as the gold standard because they have all of the bone graft acceptance mechanisms mentioned in graft materials. Besides, the unpredictable resorption of autografts is a serious disadvantage and many biomaterials or agents are used with graft materials to support bone formation, including autografts.<sup>7</sup>

Many biomaterials such as CMP, Collagen, fibroblastic growth

factor and hyaluronic acid have been developed to be used in the repair of bone defects, and studies on this subject continue.<sup>8</sup> In case of intermittent administration of teriparatide, anabolic change begins in the bone tissue by affecting the osteoblastic activity.<sup>9</sup> Conversely, if the frequency of administration increases, in other words, if it is given continuously, not intermittently, it will affect the osteoclastic activity and change in the direction of resorption in the bone tissue. It increases bone resorption by affecting balance.<sup>10</sup>

## Materials and Methods

30 male Sprague-Dawley rats with complete skeletal development were used in the study.

The block autograft obtained during defect creation in the rat mandible was ground with a bone grinder and applied in the form of particles. Bovine demineralized freeze-dried bone particle graft was used as allograft.

**Table 1.** Distribution of Study Groups

GROUPS	N	KULLANILAN MATERYAL
Group 1	1	Defect left blank (negative control group)
Group 2	2	Autograft
Group 3	3	Allograft
Group 4	4	Allograft + 20µg Teriparatide
Group 5	5	Allograft + 40µg Teriparatide



**Figure 1:** Teriparatide agent (Forsteo, Eli Lilly and Company, France) used in many defect areas

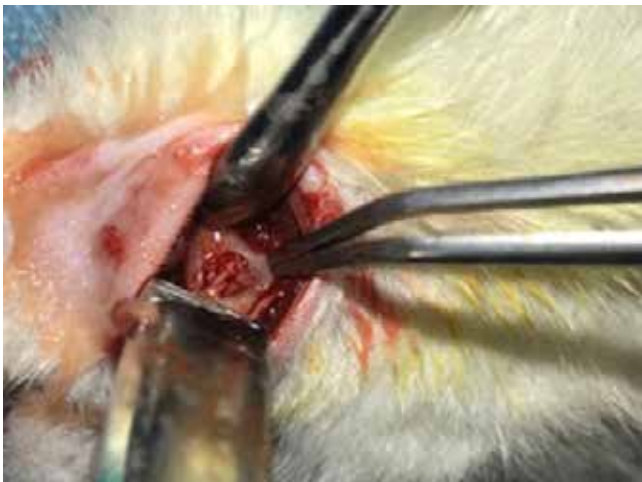In order to provide general anesthesia, 90 mg/kg Ketamine HCl (Alfamime Ege-Vet, Turkey) and Xylazine HCl2 (Alfazyne Ege-Vet, Turkey) were injected intraperitoneally to all animals. The depth of general anesthesia was controlled by pedal reflex. After providing anesthesia, the right half of the mandible was preferred as the operation site in all animals. The surgical site

was wiped using iodine solution and shaved.

In order to reduce the force on the mandible during the surgical procedure and to ensure its stabilization, the rats were fixed on the foam block with a 10 cc injector tip from the nape of the neck. By palpating the lower edge of the mandible, an 11 mm long longitudinal incision was made approximately 3 mm above and parallel to the lower edge of the mandible. The lateral aspect of the ramus was exposed so that the posterior edge of the mandible, its inferior edge, and the sigmoid notch were visible.

The region where the defect will be created; It was determined to be 3 mm away from the inferior and posterior margins of the mandible. A bicortical critical size defect of 5 mm in diameter was created in the determined area. After the defect was created, material was applied to the defect area according to the groups or the defect area was left empty.

In this study, the same amount of allograft was used to fill the defect area in 3 groups, groups 3-4-5, and only allograft was applied in group 3. In group 4-5, after allograft was applied, tp was applied to the defect area by dropping 20 mkg for group 4 and 40 mkg for group 5 in one go.



**Figure 2:** Particulate BLC placed in the surgical field.

Muscle and skin tissues were sutured separately with 4/0 vicryl using the continuous locking suture technique. For infection and pain control, intramuscular 5mg/kg/day amikacin sulfate (Amikozit, Eczacıbaşı, Turkey) and intraperitoneal ketoprofen (Profenid ampul, Senifi Aventis İstanbul, Turkey) were administered on the day of surgery and for 2 days postoperatively.

At the end of the postoperative 4th week, the anesthesia dose was doubled and the experimental animals were sacrificed. Mandible samples were taken by stripping the muscle and dermal tissue.

Bone tissue samples fixed in 10% buffered formaldehyde for histomorphometric analysis were cleaned of excess parts before analysis. After fixation, all the material was decalcified

in the prepared solution by taking 1 scale from 50% formic acid and 20% sodium citrate solutions.

After the decalcification process was completed, the bone tissue samples were embedded in paraffin blocks after washing in running tap water, passing through increasing degrees of ethanol series (50%-99%) and xylene series, followed by melted paraffin infiltration at 62°. 5-7 µm thick sections from paraffin blocks were placed on slides with a microtome (Leica RM2245).

These sections were stained with the hematoxylin–eosin staining method and evaluated. Stained sections were examined and photographed using a Nikon Ci-S light microscope, Nikon DS-Fi3 camera and NIS-Elements D image analysis system (Nikon Corporation, Tokyo, Japan).

Osteoblast counts in all samples included in the study were calculated by taking the average of 3 different unit areas (200 µm). All measurements and analyzes were performed twice by a single pathologist.

## Results


No complications such as infection or fracture were observed during or after the experiments that would cause the subjects to be excluded from the study.

At the end of the 4th postoperative week, proliferation in the bone tissue was observed in all groups by histopathological analysis.

High vascularization was detected in all groups in the newly formed granulation tissue in the defect area.

**Table 2.** Comparison of the amount of bone tissue area formed between the groups

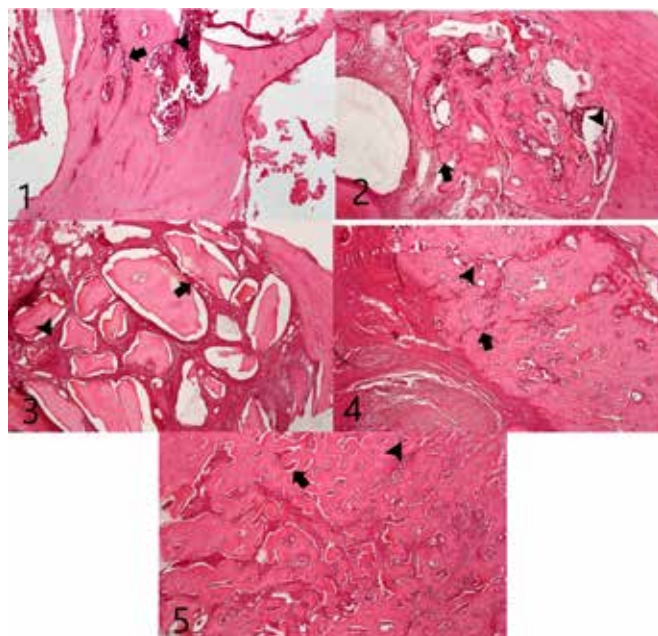
Groups	N	Ort±Ss	Min-Max (Median)	p
Group 1	6	0,28±0,01 mm <sup>2</sup>	0,27-0,29 (0,28)	0,001
Group 2	6	0,39±0,01 mm <sup>2</sup> <sup>b</sup>	0,38-0,39 (0,39)	
Group 3	6	0,48±0 mm <sup>2</sup> <sup>c</sup>	0,47-0,48 (0,48)	
Group 4	6	0,72±0,01 mm <sup>2</sup> <sup>d</sup>	0,7-0,73 (0,72)	
Group 5	6	0,79±0,01 mm <sup>2</sup> <sup>e</sup>	0,78-0,8 (0,79)	



**Figure 3:** The histomorphometric view of the defect area at the postoperative 4th week of the groups. The blue area shows the newly formed bone tissue.

**Table 3.** Comparison of osteoblast counts between groups

Grups	N	Ort±Ss	Min-Max (Median)	p
Group 1	6	41,67±1,56 <sup>a</sup>	39-43 (42)	0,001
Group 2	6	50±1,4 <sup>b</sup>	48,67-52,33 (49,67)	
Group 3	6	54,17±1,99 <sup>c</sup>	51,67-57,67 (53,84)	
Group 4	6	72±4,26 <sup>d</sup>	66,67-76,67 (73)	
Group 5	6	77,72±3,06 <sup>e</sup>	74,67-81,67 (76,67)	



**Figure 4:** The histomorphometric view of the defect area at the postoperative 4th week of the groups. Black arrow indicates osteoblast cells, black arrowhead shows organized collagen tissue.

### Discussion

Today, as a result of the use of bone grafts, completely satisfactory results cannot be obtained in the regeneration of bone tissue. For this reason, bone tissue regeneration still constitutes an important clinical problem in the field of oral and maxillofacial surgery. In recent years, it can be stated that studies on the use of biomaterials have accelerated with the aim of increasing the efficiency of bone grafts used.<sup>3</sup>

The main task of an ideal graft material/biomaterial is to play a role in the healing of the defect area in the applied area as soon as possible and by guiding the newly formed tissues. It has been observed in studies that the osteogenic potential of bone cells in the iliac crest is less than the osteogenic potential of bone cells in the mandible.<sup>3</sup>

The effects of external factors affecting bone metabolism, such as bisphosphonate-induced osteonecrosis or osteoradionecrosis, on osteogenic cells originating from the femur and mandible differ from each other. Hormones that regulate calcium metabolism, such as calcitonin and PTH, are known to directly and indirectly affect bone tissue in terms of strength, integrity, and functionality. The minimum size defect that the body cannot repair on its own is defined as CBD.<sup>12</sup>

Apart from these studies, it is seen in the literature that defects with a diameter of 5 mm in the rat mandibula are considered to be CBD. Another factor that determines the contribution of applied materials on bone healing is time. reported that the findings in the week could be evaluated as significant. The fact that the number of osteoblasts and the amount of newly formed bone tissue area of Group 1, which is the defect group that was left blank in this study, were significantly lower than the other groups, which is consistent with the literature and is an expected finding.

In Group-2, the number of osteoblasts and the amount of newly formed bone tissue area were found to be significantly lower than the data of other study groups. On the other hand, it was observed that the number of osteoblasts and the amount of newly formed bone tissue area of Group 3 were significantly lower than only Group 4 and Group 5 data. Autograft has been accepted as the gold standard in the literature.

Zandi et al.<sup>13</sup> and Koca et al.<sup>10</sup> reported that low dose use had a positive effect on bone tissue in their studies. It has been stated that it has an anabolic effect on the bone tissue if it is used intermittently, and a catabolic effect if it is used continuously. It was observed that the amount of newly formed bone in the group administered continuously was significantly less than the group given intermittently.

As a result of the study, it was shown that teriparatidine plays a role in the increase of both newly formed bone tissue and total bone tissue volume. This issue is important because the extent to which topically applied teriparatidine enters the systemic circulation is not fully known. It was stated that the amount of newly formed bone tissue per day did not differ.

New bone formation was evaluated in the 4th and 8th weeks postoperatively, and it was reported that the amount of new



bone area in the teriparatide groups was significantly higher in all time periods. The number of osteoblasts and the amount of newly formed bone tissue area of Group-4 and Group 5, which are the groups in which teriparatide was used, were significantly higher than the other groups.

Yu et al. reported in their study that teriparatidine accelerates and supports bone tissue healing by increasing vascularity and reducing fibrotic tissue formation.<sup>14</sup>

One of the studies in which teriparatidine was applied locally in the rat mandible was done by Koca et al. The researchers created a 3 mm diameter defect in the rat mandible and applied different doses of teriparatidine, 20 µg and 40 µg, locally and did not use any graft material or ground material together. evaluated the effect of teriparatidine on bone healing and masseter muscle at 1 week. Researchers reported that bone healing was statistically significantly higher in the groups using teriparatide compared to the null defect group, but there was no difference between the groups using teriparatide.<sup>15</sup>

Koca et al. created a 3 mm diameter defect in the mandible of the rat and applied teriparatidine locally at different doses, 20 µg and 40 µg, without using any graft material or ground material.<sup>15</sup>

Shiraki et al. evaluated the effects of a single-dose injection of teriparatidine on bone turnover markers and calcium mechanisms in postmenopausal female patients.<sup>16</sup>

## Conclusion

There are 2 main factors that determine the efficacy of teriparatidine: the dose of use and the frequency of administration. Bone defects show different healing stages in different time periods. Therefore, the effect of locally applied teriparatide on bone healing can be evaluated in more than one different and critical time period.

## Source of Finance

None declared.

## Conflicting Interests

None declared.

## Authorship of Contributions

Muhammed Fatih Çiçek , Cansu Gül Efeoğlu Koca

## References

1. Anderson HC. Vesicles associated with calcification in the matrix of epiphyseal cartilage. *Journal of Cell Biology*. 1969;41:59-72.
2. Saito S, Shimizu N. Stimulatory effects of low-power laser irradiation on bone regeneration in midpalatal suture during expansion in the rat. *American Journal of Orthodontics and Dentofacial Orthopedics*. 1997;111(5):525-532.
3. Bar-Shavit Z. The osteoclast: a multinucleated, hematopoietic-origin, bone-resorbing osteoimmune cell. *J Cell Biochem*. 2007 Dec 01;102(5):1130-9.
4. Shapino F. Bone development and its relation to fracture repair. The role of mesenchymal osteoblasts and surface osteoblasts. *European Cells and Materials*, 2008;1;58-73.
5. Koca CG, Komerik N, Ozmen O. Comparison of efficiency of hyaluronic acid and/or bone grafts in healing of bone defects. *Nigerian Journal of Clinical Practice*. 2019; 22; 754-762.
6. Acocella A, Bertolai R, Ellis E 3rd, et al. Maxillary alveolar ridge reconstruction with monocortical fresh-frozen bone blocks: a clinical, histological and histomorphometric study. *J Craniomaxillofac Surg* 2012;40(6):525-33.
7. Kökden A, Türker M. Bone grafts and biomaterials used in oral and maxillofacial surgery, Cumhuriyet University Faculty of Dentistry Journal 1999
8. Zandi M, Dehghan A, Gheysari F, Rezaeian L, Mohammad Gholi Mezerji N: Evaluation of teriparatide effect on healing of autografted mandibular defects in rats. *Craniomaxillofac Surg* 47: 120e126, 2019
9. Koca C.G., Sanaz S., Asker H., Çiçek M. F., Kösehasanoğulları M., Kaya G., Effects of the different administration frequencies of teriparatide (PTH [1-34]) on new bone formation of expanded midpalatal sutures in rats: A histomorphometric and microcomputed tomography analysis. *Orthodontics And Craniofacial Research*. 202. DOI: 10.1111/ocr.12512
10. Chaichanasakul T, Mandible versus long bone marrow stromal cells. A Dissertation Submitted in partial Satisfaction of The Requirements For The Degree Doctor of philosophy In Oral Biology. 2012; 1-22.
11. Awadeen MA, Al-Belasy FA, Ameen LE, Helal ME, Grawish ME. Early therapeutic effect of platelet-rich fibrin combined with allogeneic bone marrow-derived stem cells on rats' critical-sized mandibular defects. *World Journal of Stem Cells*. 2020; 12(1): 55-69.
12. Henrickson SE, Ruffner MA, Kwan M. Unintended Immunological Consequences of Biologic Therapy. *Curr Allergy Asthma Rep*. 2016 Jun;16(6):46. doi: 10.1007/s11882-016-0624-7
13. Zandi M, Dehghan A, Gheysari F, Rezaeian L, Mohammad Gholi Mezerji N, Evaluation of teriparatide effect on healing of autografted mandibular defects in rats, *Journal of Cranio-Maxillofacial Surgery*, <https://doi.org/10.1016/j.jcms.2018.11.015>.
14. Yu YY, Lieu S, Hu D, Miclau T, Colnot C: Site specific effects of zoledronic acid during tibial and mandibular fracture repair. *PLoS One* 7: 31771, 2012
15. Koca CG, Kösehasanoğulları M, Yıldırım B, Kaya I, Yuce E, Çiçek MF. Effect of Single-Dose and Locally Applied Teriparatide on Masseter Muscle Thickness and Early Mandibular Healing. *Van Med J*. 2021; 28(1): 151-158
16. Shiraki M, Sugimoto T, Nakamura T. Effects of a single injection of teriparatide on bone turnover markers in postmenopausal women. *Osteoporos Int*. 2013 Jan;24(1):219-26. doi: 10.1007/s00198-012-2159-7.