

## Radiological and Thermographic Diagnosis of Myositis Ossificans in A Shepherd Hybrid Dog

Ayşe Başak KAPÇAK<sup>1a</sup>, Elif DOĞAN<sup>1b</sup>

1. Kastamonu Üniversitesi, Veteriner Fakültesi, Cerrahi Anabilim Dalı, Kastamonu, Türkiye.  
basakkapcak@kastamonu.edu.tr, ORCID ID: 0000-0002-5796-5298<sup>a</sup>

1. Kastamonu Üniversitesi, Veteriner Fakültesi, Cerrahi Anabilim Dalı, Kastamonu, Türkiye.  
elifdogan@kastamonu.edu.tr, ORCID ID: 0000-0002-3321-8116<sup>b</sup>

Received  
19.05.2023

Accepted  
10.06.2023

Published  
20.06.2023

**Bu makaleye atıfta bulunmak için/To cite this article:**

**Kocaman Y:** Radiological and Thermographic Diagnosis of Myositis Ossificans in A Shepherd Hybrid Dog, Atatürk University J. Vet. Sci., 3(1): 16-19, 2023.

**Abstract:** In this case report, the thermographic and radiological diagnosis of myositis ossificans circumscripta case in a 13-year-old male Shepherd cross dog is described. The animal was brought to our clinic with the complaint of chronic lameness after a traffic accident. On physical examination, a prominent swelling was observed in the left anterior extremity. The patient had no signs of paralysis. On palpation, the swellings were found to be harder as it progressed from the distal parts of the left anterior extremity to the proximal part. A firm, well-defined swelling the size of a tennis ball was also noted on the medial part of the humerus. It was decided to perform thermographic imaging as a clinical auxiliary pre-diagnosis tool. After the measurements, temperature differences were detected between the two front legs, especially in the proximal 2/3 parts of the humerus. Radiological evaluation was deemed appropriate for definitive diagnosis. After examination, the swelling was defined as a case of myositis ossificans circumscripta originating from the proximal 2/3 of the humerus. For the treatment of the case, methylprednisolone treatment and regular follow-up of the patient were recommended. This case constitutes the few reports of myositis ossificans circumscripta of the anterior extremity in dogs diagnosed using thermographic and radiological diagnostic techniques.

**Keywords:** Dogs, Extremity, Myositis Ossificans Circumscripta, Thermography.

### INTRODUCTION

**E**xtra-osseous and non-neoplastic growth of new bone in connective tissue other than muscle is called Fibrodysplasia ossificans.

Myositis ossificans is a separate term used to describe heterotopic bone formation within the muscle.<sup>1</sup> These forms of ectopic ossification should be distinguished from ectopic mineralization, in which silicate, phosphate, calcium salts and other minerals accumulate in abnormal places<sup>2</sup>. Myositis ossificans circumscripta or ossifying myopathy is heterotopic bone formation in muscle and is generally classified among idiopathic myopathies.

The localized (limited) form is characterized by heterotopic and non-neoplastic bone formation in one or more muscles due to the metaplastic evolution of a fibrotic contracture or myopathy<sup>4</sup>.

The disease, which is predominantly defined in horses and dogs, was also detected and reported in

a kangaroo by Huenerfauth et al.<sup>5</sup>. Generally, the caudal muscles of the femur, especially the biceps femoris, semitendinosus, semimembranosus, gracilis, sartorius and gluteal muscles, are typically localized in the coxofemoral joint region<sup>6</sup>. Intense exercise, trauma or intramuscular injections play a role in the formation of the disease<sup>3, 4, 6</sup>. The form, also known as progressive ossifying fibrodysplasia or generalized ossifying myositis, is more common in young to middle-aged cats<sup>3, 7, 8</sup>. Recent reports have described the condition of myositis ossificans circumscripta in other dog breeds, but few reports of myositis ossificans circumscripta occur in the forelimb muscles<sup>9, 10</sup>.

In this case report, myositis ossificans circumscripta, which is rarely encountered in the front legs of dogs, is discussed.

### CASE PRESENTATION

In this case report, a case of Myositis ossificans circumscripta encountered in the proximal

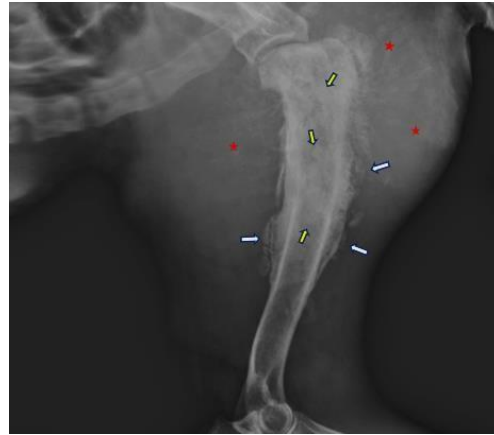
part of the left fore-extremity in a 13-year-old male shepherd crossbreed dog was discussed. The patient, who did not respond to conservative treatment and was brought to the Animal Hospital of our Faculty with the complaint of lameness lasting for one month, was recorded in the anamnesis of the lameness that occurred after the traffic accident.

There was no general condition disorder in the clinical examination. However, on inspection, a diffuse swelling of the left forelimb, increasing from distal to proximal, was detected. While edema was detected in the distal parts of the left anterior extremity on palpation, these swellings were found to harden as it progressed proximally. In addition, a hard swelling as hard as a tennis ball was detected in the Triceps brachii muscle at the humerus level (Figure 1).



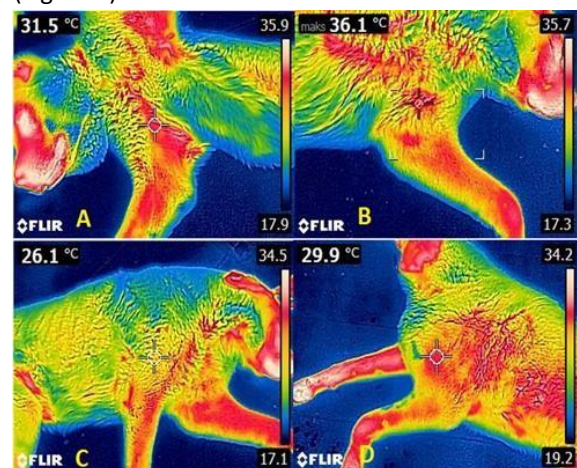
**Figure 1.** Image of the swelling in the patient's anterior left leg.

Radiographic examination revealed multiple mineralized densities with irregular borders in the muscle tissue lateral to the caput humerus, proliferative growths protruding beyond the cortex in the proximal 2/3 of the humerus, and irregular radiolucent areas in the medulla (Figure 2).



**Figure 2.** Radiographic view of the case. White arrow: Proliferative growths beyond the cortex, Yellow arrow: Radiolucent areas in the medulla, Red star: Indicates increases in opacity in muscle tissue.

In thermographic imaging, measurements were made on the basis of two symmetrical points and the evaluation was made by comparing the measurements between the two points. As a result of the thermographic evaluation of the forelegs, measurements taken from the symmetrical points revealed high temperature in the proximal part of the left foreleg where hard swellings were intense. While the medial and lateral temperature values in the healthy leg were 31.5°C and 26.1°C, respectively, these values were 36.1°C and 29.9°C in the sick leg (Figure 3).



**Figure 3.** Thermographic images taken from the case. A: Medial of the intact extremity, B: Medial of the sick leg, C: Lateral of the healthy leg, D: Lateral of the sick leg. Temperature increases in both the medial and lateral sides of the patient's leg are remarkable.

The patient diagnosed with myositis ossificans circumscripta was treated 1-3-7. 1 cc (local application at two different points as 0.5) Methylprednisolone (PREDNOL-L 20 mg inj.) treatment at a dose of 40 mg once a week was recommended.

#### **DISCUSSION and CONCLUSION**

Myositis ossificans circumscripta is a reactive lesion of tissues adjacent to the bone. It is caused by trauma and contains abundant atrophic or necrotic muscle tissue. The disease is characterized by bone metaplasia or proliferative fibrous connective tissue that responds to damage<sup>11</sup>. Myositis ossificans circumscripta presents clinically as a painful swelling that rapidly increases in size. Pain and inflammatory symptoms disappear spontaneously after approximately 2-6 weeks, and the mass stabilizes or decreases<sup>12</sup>. The patient, who was brought to our clinic after approximately 30 days, did not experience any pain response in the areas of swelling in the palpation examination. Myositis ossificans circumscripta is a very important pathology in human medicine due to its confusion with osteosarcoma, and this has led medical practitioners to make radical decisions such as chemotherapy and amputation<sup>13</sup>. The fact that it has been reported very little in the field of veterinary medicine can be associated with the fact that the disease is generally not life-threatening<sup>14</sup>. The fact that our case had a chronic history and that the case of Myositis ossificans circumscripta was detected late is in line with the literature.

In the differential diagnosis of myositis ossificans circumscripta, irregularity of proliferative growths is expressed as an important finding used to distinguish the lesion from the tumor<sup>15</sup>. In our radiographic evaluation, we observed irregular proliferative growths protruding beyond the cortex, which excluded our case from the diagnosis of tumor. In cases of Myositis ossificans circumscripta, mineralization has been reported on radiographs two to four weeks after lesion formation. It has been reported that calcification in the region progresses from the periphery to the center and it takes approximately 14 weeks for the lesion to fully develop<sup>16</sup>(pp550-553). It is not known how the

disease progressed in our case, who had been presenting with lameness for more than a month, since controls could not be performed at the early stage. However, the presence of mineralization in the area of swelling in the radiographic evaluations supports the literature. Radiographically, there is an initial follicular calcification that progresses to mature lamellar bone. The intermediate zone contains osteoid and some areas of immature bone, and at the periphery there is mature trabecular bone with osteoclastic resorption and remodeling. Over time, the entire lesion may ossify, regress, or resorb. Bilateral lesions in the gluteal region in two German shepherds, in the rectus femoris muscle in a Dalmatian and around the triceps insertions in a Siamese cat, have diagnostic pathological and radiographic appearances similar to those seen in humans. There is no invasion into surrounding soft tissues<sup>17</sup>. In our case, bilateral firm swellings were observed in the triceps brachii and biceps brachii muscles. In our radiographic evaluation, multiple mineralized densities with irregular edges in the muscle tissue around the caput humeri, proliferative growths protruding beyond the cortex in the proximal 2/3 of the humerus, and irregular radiolucent areas in the medulla, which support the literature, support our diagnosis. Ectopic ossification can be confused with the ectopic mineralization that occurs in myositis circumscripta. This condition is seen radiographically as an irregular calcified mass, usually located in the periarticular region, with clear borders and is frequently diagnosed in German shepherd dogs<sup>16</sup>(pp550-553). Absence of irregular calcified masses in the periarticular region in our radiographic imaging constitutes our differential diagnosis.

Early diagnosis and differentiation of Myositis ossificans circumscripta, which is a tumor-like proliferative lesion, will positively affect the treatment process of the disease. Although myositis ossificans in dogs has been previously described in the hind legs, this case of myositis ossificans circumscripta diagnosed in the triceps muscle suggests that it may also occur in the forelimb muscles.

**CONFLICT of INTEREST**

The authors declare that they have no conflict of interest.

**REFERENCES**

1. De Paolo M, Gracis M, Lacava G, Vapniarsky N, Arzi B. Management of bilateral pterygoid myositis ossificans-like lesion in dogs. *Frontiers in Veterinary Science*. 2022; 1341.
2. Jubb K V F, Kennedy P C, Palmer N., Bones and joints. In: *Pathology of Domestic Animals*, Vol 1, 4th edn. Academic Press, San Diego. pp 14-16, 1993.
3. LeCouter RA. Neuropathies, junctionopathies and myopathies of dogs and cats. *Proceedings of the 2nd Annual Veterinary Neurology Symposium*; 2005 July 24; (University of California) Davis, California, USA.
4. Taylor J, Tangner CH. Acquired muscle contractures in the dog and cat. A review of literature and case report. *Vet Comp Orthop Traumatol* 2007; 20: 79-85.
5. Huenerfauth EI, Molnár V, Rosati M, Ciurkiewicz M, Söbbeler FJ, Harms O, Hildebrandt R, Baumgärtner W, Tipold A, Volk HA and Nessler J, Case Report: Unable to Jump Like a Kangaroo Due to Myositis Ossificans Circumscripta. *Front. Vet. Sci.* 2022; 9:886495. doi: 10.3389/fvets.2022.886495.
6. Vilar JM, Ramirez G, Spinella G, et al. Kinematic characteristics of myositis ossificans of the semimembranosus muscle in a dog. *Can Vet J* 2010; 51: 289–292.
7. Yabuzoe A, Yokoi S, Sekiguchi M, et al. Fibrodysplasia ossificans progressiva in a Maine Coon cat with prominent ossification in dorsal muscle. *J Vet Med Sci* 2009; 71: 1649–1652.
8. Asano K, Sakata A, Shibuya H, et al. Fibrodysplasia ossificans progressiva-like condition in a cat. *J Vet Med Sci* 2006; 68: 1003-1006.
9. Ramírez Romero R, Nevárez Garza AM, Rodríguez Tovar LE, et al. A case of myositis ossificans circumscripta-like condition in a dog. *Vet Méx* 2008; 39: 451-456.
10. Wittschen P, Wiegand U, Gruber AD. Uncommon location of myositis ossificans in a nine-year-old female German Shepherd dog. A case report. *Tierarztl Prax Ausg K Kleintiere Heimtiere* 2008; 36: 200-204.
11. Vanden Bossche L, Vanderstraeten G. Heterotopic calcification: a review. *J Rehabil Med* 2005; 37:129-36.
12. Cren, PY., Penel, N., Cordoba, A. et al. Myositis ossificans circumscripta after surgery and radiotherapy and during sunitinib treatment: a case report. *J Med Case Reports*. 2022; 16,454.
13. Ragananthan N, Sugavanam C. Pseudomalignant myositis ossificans mimicking osteosarcoma: a case report. *J Orthop Surg (Hong Kong)* 2006; 14:219-221.
14. Pool RR, Thompson KG. Tumors of joints In: Meuten DJ, editor. *Tumors in Domestic Animals*. 4th ed. Ames, Iowa: Iowa State Press, 2002: 199-243
15. Leonardo L, Tumor-like Lesions of the Musculoskeletal System, *Bone Tumors in Domestic Animals*, 2022; 10.1007/978-3-030-90210-03, (157-166).
16. Guilliard M J. *Journal of Small Animal Practice*. 2001;42,550-553.
17. Roudebush P, Maslin W R, Cooper R C. Canine tumoral calcinosis. *Compendium on Continuing Education for the Practicing Veterinarian*. 1988; 10, 1162-1164.