

# Evaluation of the morphological and morphometric characteristics of the acetabulum in the Anatolian population

Melike Taşci , Büşra Pirinç , Betül Sevindik , Nadire Ünver Doğan 

Department of Anatomy, Faculty of Medicine, Selçuk University, Konya, Türkiye

## Abstract

**Objectives:** The aim of our study was to investigate the shape, variations and dimensions of the acetabulum, which has an important place in the structure of the hip joint and is of great importance in terms of surgical interventions and compliance with hip joint prostheses, in the Anatolian population.

**Methods:** A total of 45 coxal bones, 24 right-sided and 21 left-sided, were evaluated. The anterior ridge of the acetabulum was classified into four types: straight, curved, angular and irregular. The transverse diameter (TD), posteroinferior-vertical diameter (VD), acetabular depth (AD) and width of the acetabular notch (WAN) were measured using a digital caliper.

**Results:** Seven (15.6%) acetabula had straight, 23 (51.1%) had curved, 9 (20%) had angular and 6 (13.3%) had an irregular anterior ridge. The measurements were as follows; TD: 52.3±4.7 mm; VD: 54±4.4 mm; WAN: 26.3±3.6 mm; and AD: 25.3±3 mm. There was no significant difference between the right and left sides for any of the morphometric measurements.

**Conclusion:** Our study revealed that the most common anterior acetabular ridge shape was curved on both sides of the coxal bone and showed that acetabular morphometry did not vary by side.

**Keywords:** acetabulum; dry bone; morphology; morphometry

Anatomy 2023;17(1):34–40 ©2023 Turkish Society of Anatomy and Clinical Anatomy (TSACA)

## Introduction

The acetabulum is a structure formed at the junction of the ilium, ischium and pubis in the coxal bone. It articulates with the femoral head to form hip joint. Thus, it plays a role in the connection and force transmission between the pelvis and lower limbs.<sup>[1,2]</sup>

Knowing the morphometric properties of the acetabulum is important for radiologists and orthopedic surgeons in diagnosis and surgical planning.<sup>[2]</sup> Antevert and shallow orientation of the acetabulum is associated with acetabular dysplasia, while increased depth may be associated with femoroacetabular impingement and other orthopedic problems.<sup>[3]</sup> Even small anatomical incongruities in the structure of the acetabulum can increase susceptibility to degenerative changes in the joint.<sup>[4]</sup>

During preoperative planning for total hip arthroplasty (THA), differences in bone structure between individuals make it difficult to use uniform materials and

standardized methods.<sup>[5]</sup> Knowledge of variations in the diameter and depth of the acetabulum is also important in the surgical treatment of acetabular fractures.<sup>[6]</sup> In this context, it is important to know the acetabular morphometry to ensure an optimal fit between the femoral head and acetabulum.

Another clinically important factor in THA is the degree of anteversion, which is necessary for proper implant placement and prevention of dislocation. The morphology of the anterior ridge of the acetabulum also affects the degree of anteversion and therefore its variations are considered important. Since the posterior margin of the acetabulum is usually a simple semicircle, only the anterior margin types have been classified.<sup>[7,8]</sup>

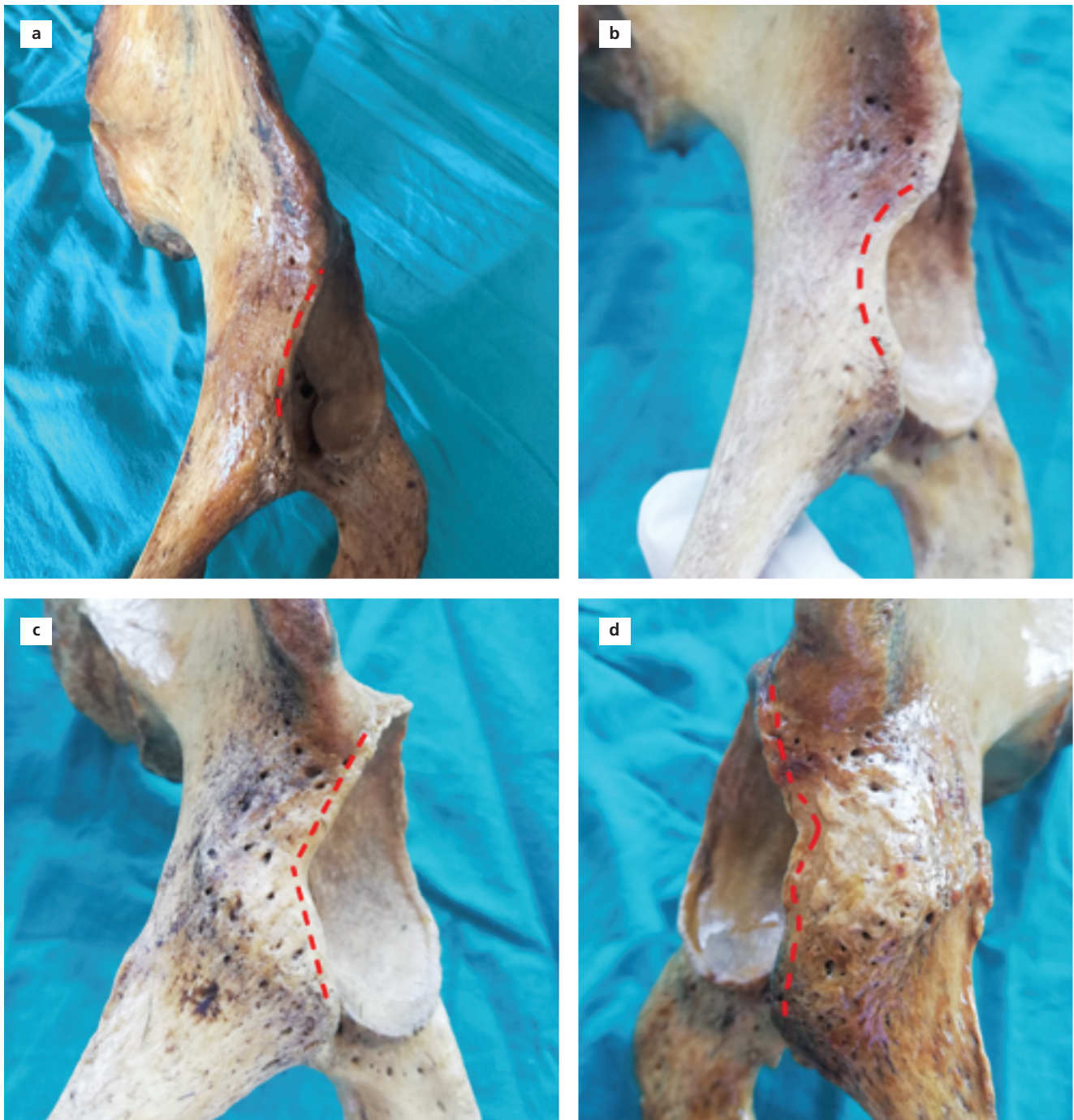
With our study, we aimed to contribute to the literature on the morphology and morphometric characteristics of the acetabulum in Anatolian population.

## Materials and Methods

The study included 45 dry coxal bones from our anatomy laboratory with unknown sex and age. The bones were unilateral from different individuals and did not belong to the pelvis as a whole. There were 24 coxal bones from the right side and 21 from the left side, and

the bones reflected the Anatolian population in terms of their origin. The morphology of the anterior margin of the acetabulum was classified into four groups: straight, curved, angular and irregular, in accordance with the literature (Figure 1).<sup>[9]</sup>

For manual morphometric measurements, a digital caliper with a measurement range of 0–150 mm and a



**Figure 1.** Acetabular anterior ridge types. (a) straight; (b) curved; (c) angular; (d) irregular.

precision of 0.03 mm was used. The measurements were repeated twice by the same researcher and the average of the measurements was given as the result. Following parameters were evaluated by measurements:

- Vertical (posteroinferior) diameter (VD) was measured along the axis passing through the anterior superior iliac spine and ischial tuberosity (**Figure 2a**).<sup>[10]</sup>
- The transverse diameter (TD) of the acetabulum is measured as the maximum distance between the anterior and posterior edges of the acetabular cavity (**Figure 2b**).<sup>[2]</sup>
- The width of the acetabular notch (WAN) is measured as the distance between the two edges of the lunata surface (**Figure 2c**).<sup>[7]</sup>
- Acetabular depth (AD) is measured as the perpendicular distance from the deepest point of the acetabular fossa to the horizontal plane passing through the sides of the acetabulum (**Figure 2d**).<sup>[6]</sup>

Statistical analyses were performed using BM SPSS Statistics Standard Concurrent User v. 22 (IBM Corp., Armonk, NY, USA). Whether the data conformed to the normal distribution was evaluated according to the kurtosis and skewness values. Independent sample t-test was

applied for the comparison between right and left sides. A p-value of <0.05 was considered statistically significant.

## Results

Of the 45 bones evaluated, 24 were right and 21 were left. Regarding the evaluation of the anterior acetabular ridge types: in the right coxae there were 4 straight (16.6%), 12 curved (50%), 3 angular (12.5%) and 5 irregular types (20.8%). The bones on the left side had 3 flat (14.2%), 11 curved (52.3%), 6 angular types (28.5%) and 1 irregular type (4.7%). In the whole sample, there were 7 flat types (15.6%), 23 curved types (51.1%), 9 angular types (20%) and 6 irregular types (13.3%) (**Table 1**).

When the average values of all bones were considered, TD was  $52.3 \pm 4.7$  mm; VD was  $54 \pm 4.4$  mm; WAN was  $26.3 \pm 3.6$  mm; AD was  $25.3 \pm 3$  mm. TD was  $51.8 \pm 3.8$  mm on the right and  $52.9 \pm 5.5$  mm on the left. VD was  $54.1 \pm 3.5$  mm on the right and  $53.9 \pm 5.4$  mm on the left. WAN was  $26.1 \pm 3.4$  mm on the right and  $26.6 \pm 3.9$  mm on the left. AD was  $24.9 \pm 3.07$  mm on the right and  $25.8 \pm 3$  mm on the left (**Table 2**). No significant differences were found for any of the morphometric assess-

**Table 1**

Frequencies of morphological types of anterior acetabular ridge.

Ridge type	Right	Left	Total
Straight	4 (16.6%)	3 (14.2%)	7 (15.6%)
Curved	12 (50%)	11 (52.3%)	23 (51.1%)
Angular	3 (12.5%)	6 (28.5%)	9 (20%)
Irregular	5 (20.8%)	1 (4.7%)	6 (13.3%)
Total	24 (100%)	21 (100%)	45 (100%)

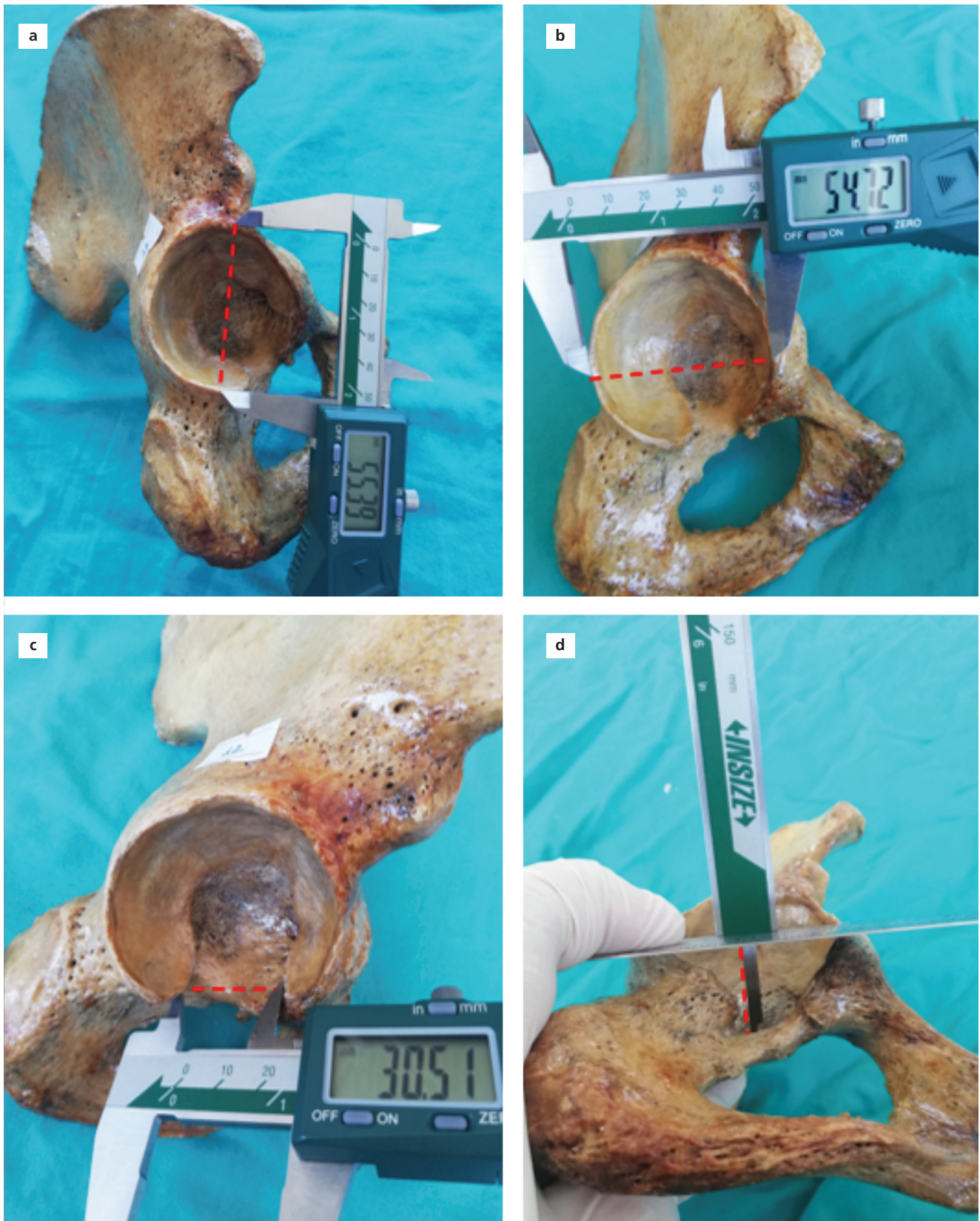
**Table 2**

Mean acetabular morphometric measurements according to side.

	Side	Mean±SD (mm)	p-value
TD	Right	$51.8 \pm 3.8$	0.42
	Left	$52.9 \pm 5.5$	
VD	Right	$54.1 \pm 3.5$	0.86
	Left	$53.9 \pm 5.4$	
WAN	Right	$26.1 \pm 3.4$	0.66
	Left	$26.6 \pm 3.9$	
AD	Right	$24.9 \pm 3.1$	0.33
	Left	$25.8 \pm 3.0$	

AD: acetabular depth; SD: standart deviation; TD: transverse acetabular diameter; VD: vertical (posteroinferior) acetabular diameter; WAN: width of the acetabular notch.





**Figure 2.** Measurements taken with a digital caliper. (a) vertical (posteroinferior) acetabular diameter (VD); (b) transverse acetabular diameter (TD); (c) width of the acetabular notch (WAN); (d) acetabular depth (AD).

ments between the right and left sides (for TD  $p=0.42$ , for VD  $p=0.86$ , for WAN  $p=0.66$ , and for AD  $p=0.33$ ).

## Discussion

In our study, we evaluated the morphologic features of the acetabulum on right and left sides. And no significant difference was found between the right and left sides in terms of TD, VD, WAN and AD. When other studies on this subject were examined; in a dry bone study conducted by Ukoha et al.<sup>[2]</sup> no significant difference was found between the right and left sides in terms of TD, VD and AD. Likewise, Sreedevi et al.<sup>[7]</sup> reported that there was no significant difference between right and left sides in terms of VD, AD and WAN in a dry bone study on Indian population. In another the dry bone study conducted by Vyas et al.<sup>[4]</sup> on Indian population, no significant difference was found between right and left sides in terms of TD and AD. In the study of Yugesh et al.<sup>[11]</sup> on dry bones in Indian population, no statistically significant relationship was found between right and left sides for TD, WAN and AD. Both our study and results of other studies emphasize that the morphometric properties of the acetabulum do not differ significantly between the sides.

Both the studies of Vyas et al.<sup>[4]</sup> and Yugesh et al.<sup>[11]</sup> were conducted on the Indian population; however, it is noteworthy that they found significantly different values for WAN,  $22.2\pm 2.9$  mm and  $30.8\pm 0.42$  mm, respectively (Table 3). The different results in the studies conducted on

the same population and using the same method may be attributed not only to ethnicity but also to factors such as age, sex and body weight of the individuals to which the bones belonged. Furthermore, different results may also be related to ethnic diversity among individuals living in the same country.

In our study, the gender of the individuals to whom the bones belonged is not known. However, there are some studies in the literature evaluating according to gender: Indurjeeth et al.<sup>[10]</sup> in South Africa reported that acetabular diameter, acetabular depth and acetabular notch width were significantly higher in males than females. In a study conducted by Chauhan et al.<sup>[12]</sup> in India on a total of 48 cadavers (36 males and 12 females) aged 50–70 years in India, acetabular diameter was larger in males (right:  $47.10\pm 2.90$  mm, left:  $47.48\pm 3.05$ ) compared to females (right:  $44.38\pm 3.01$  mm, left:  $46.0\pm 2.28$  mm) and there was a significant difference between genders. Zeng et al.<sup>[3]</sup> performed a CT study on 50 men and 50 women in a Chinese population with a mean age of  $48.2\pm 8.47$  years and did not show a significant difference between the sexes. However, acetabular width (for male; right  $55.2\pm 3.11$  mm, left  $56.0\pm 3.33$  mm- for female; right  $51.4\pm 2.38$  mm, left  $51.4\pm 2.07$  mm) and depth (for male; right  $19.3\pm 2.48$  mm, left  $19.4\pm 2.21$  mm- for female; right  $17.3\pm 1.68$  mm, left  $17.4\pm 1.58$  mm) were significantly lower in women. In studies conducted in various populations, there are findings showing that acetabular parameters are larger in men.

**Table 3**  
Results of studies in the literature on acetabular morphometrics.

Study	Ethnic origin	Side	Number of bones	TD (mm)	VD (mm)	WAN (mm)	AD (mm)
Ukoha et al. <sup>[2]</sup>	Nigerian	Right	44	$53.9\pm 0.3$	$55.8\pm 0.3$		$29.7\pm 0.3$
		Left	56	$53.2\pm 0.3$	$54.6\pm 0.3$		$30.2\pm 0.3$
Indurjeeth et al. <sup>[10]</sup>	South African (black race)	Right	44		$54.84\pm 4.18$	$21.72\pm 2.98$	$31.30\pm 3.18$
		Left	56				
Sreedevi et al. <sup>[7]</sup>	Indian	Right	39		$49.4\pm 3.5$	$22.2\pm 2.9$	$24.0\pm 2.6$
		Left	41		$48\pm 5.6$	$22.5\pm 2.4$	$25.1\pm 2.8$
Vyas et al. <sup>[4]</sup>	Indian	Right	74	$47.9\pm 3.5$			$27.1\pm 2.7$
		Left	78	$48.3\pm 3.1$			$26.5\pm 3.4$
Yugesh et al. <sup>[11]</sup>	Indian	Right	60	$47.4\pm 0.27$		$30.8\pm 0.42$	$29.9\pm 0.21$
		Left		$48.0\pm 0.37$		$31.1\pm 0.72$	$29.7\pm 0.23$
Aksu et al. <sup>[6]</sup>	Anatolian		154		$54.29\pm 3.8$		$29.49\pm 4.2$
Uzun et al. <sup>[11]</sup>	Anatolian	Right	50	50.57		18.08	24.87
		Left	46	51.44		20.25	22.85
Current study	Anatolian	Right	24	$51.8\pm 3.8$	$54.1\pm 3.5$	$26.1\pm 3.4$	$24.9\pm 3.07$
		Left	21	$52.9\pm 5.5$	$53.9\pm 5.4$	$26.6\pm 3.9$	$25.8\pm 3.0$

AD: acetabular depth; SD: standart deviation; TD: transverse acetabular diameter; VD: vertical (posteroinferior) acetabular diameter; WAN: width of the acetabular notch.

When the results of the study conducted by Uzun et al.<sup>[1]</sup> on Anatolian population were compared with the results of our study, very similar results were obtained for TD and AD. However, our study showed larger values for WAN. In terms of VD, our present study presented similar values to Aksu et al.<sup>[6]</sup> Although there is a difference in the mean value for AD, the standard deviation values show that the results are not significantly different (**Table 3**). The study of Uzun et al.<sup>[1]</sup> was performed with 96 bones without specifying gender and age characteristics, while the study of Aksu et al.<sup>[6]</sup> was performed with 154 bones without specifying gender and age characteristics. Despite similar limitations in our study, both studies had larger sample sizes compared to ours.

When the morphometric findings of our study were compared with the mean and standard deviation values of other populations, it was observed that our measurements were similar for TD and VD. However, in terms of WAN, we found higher values compared to both the study by Indurjeeth et al.<sup>[10]</sup> in a South African population and the study by Uzun et al.<sup>[1]</sup> in an Anatolian population, and lower values compared to the study by Yugesh et al.<sup>[11]</sup> in an Indian population. The differences observed in studies in the same population may be related not only to race but also to parameters such as gender and age that may affect morphometry.

In our study, in terms of the shape of the acetabular anterior margin, 7 of 45 coxal bones were classified as straight type (15.6%), 9 as angular type (20%) and 6 as irregular type (13.3%). The most common type was the curved type observed in 23 bones (51.1%). Among other studies conducted in Anatolian population, Aksu et al.<sup>[6]</sup> found curved type in 46.1% of their samples, Govsa et

al.<sup>[9]</sup> found it in 43.3% samples and curved type was the most common type in these studies. In the study by Uzun et al.<sup>[1]</sup> the curved type was seen with a frequency of 28.1%, while the straight type was found to be 42.7%. The type of anterior prominence may be a parameter influenced by the observer, and the higher prevalence of the straight type in the study of Uzun et al.<sup>[1]</sup> compared to our study and other studies may indicate a discrepancy related to the bones included in the study and the observer. The effect of age and gender characteristics of the bones was not evaluated in our study and related studies, so their effect on ridge type could not be evaluated.

In studies conducted on the Indian population, the curved type was the most common type with a rate of 37.5% in the study by Vyas et al.,<sup>[4]</sup> 43.7% in the study by Sreedevi et al.<sup>[7]</sup> and 61% in the study by Parmara et al.<sup>[13]</sup> The higher rate in the Indian population in the study of Parmara et al.<sup>[13]</sup> compared to other studies may be due to the fact that angular type was not included in their classification. In the study conducted by Ukoha et al.<sup>[2]</sup> in the Nigerian population, the curved type was the most common type with a rate of 35%. Maruyama et al.<sup>[8]</sup> also found that the curved type was the most common with a rate of 60.5%. In a study conducted by Indurjeeth et al.<sup>[10]</sup> in Africa, the angular type was found to be the most common type with a rate of 41%. Considering that the study was conducted on black population, it can be assumed that the angular type is relatively higher in this population. In addition, although types were defined for genders in the study, a gender-based comparison was not made (**Table 4**).

Limitations of our study include the limited number of bones in our sample and the lack of information on

**Table 4**

A comparison of frequencies of anterior acetabular ridge shapes among various studies in the literature (%).

	Ethnic Origin	Number of Bones	Straight (%)	Curved (%)	Angular (%)	Irregular (%)
Ukoha et al. <sup>[2]</sup>	Nigerian	100	23	35	33	9
Indurjeeth et al. <sup>[10]</sup>	South African (black race)	100	14	22	41	23
Maruyama et al. <sup>[8]</sup>	American/ African-American	200	9 (4.5%)	121 (60.5%)	51 (25.5%)	19 (9.5%)
Sreedevi et al. <sup>[7]</sup>	Indian	80	22	35	18	5
Parmara et al. <sup>[13]</sup>	Indian	100	20	61		19
Vyas et al. <sup>[4]</sup>	Indian	152	48	57	19	28
Govsa et al. <sup>[9]</sup>	Anatolian	226	27	98	64	37
Aksu et al. <sup>[6]</sup>	Anatolian	154	36	71	26	21
Uzun et al. <sup>[1]</sup>	Anatolian	96	41	27	20	8
Current study	Anatolian	45	7	23	9	6



the sex, age and body weight of the individuals to whom the bones belonged. Also, the demographic characteristics of the bones are not known. Therefore, the study data are reported to reflect the characteristics of the Anatolian population according to their origin.

## Conclusion

Understanding the morphologic and morphometric properties of the acetabulum is very important because of its contribution to the structure of the hip joint. Our study emphasized that the morphometric characteristics of the acetabulum did not differ significantly between the parties. It also showed that the most common shape of the anterior acetabular margin is the curved type. Therefore, our study contributes to the literature on the characteristics of the acetabulum in Anatolian population.

## Conflict of Interest

The authors declare that they have no conflict of interest.

## Author Contributions

MT: data collection, data analysis, manuscript writing; BP: project development, manuscript writing and editing; BS: project development, manuscript editing; NUD: project development, manuscript editing.

## Ethics Approval

All procedures performed in this study involving human participants were in accordance with the ethical standards of the institutional and/or national research committee and with the 1964 Helsinki declaration and its later amendments or comparable ethical standards. Ethical approval was given by the Non-Intervention Clinical Research Ethics Committee of the Medical Faculty (Approval No: 2023/372).

## Funding

This research did not receive any specific grant from funding agencies in the public, commercial, or not-for-profit sectors.

## References

1. Uzun GB, Değermenci M, İlyas U, Arslan A, Nisari M. Morphometric evaluation of acetabulum. *Journal of Surgery and Medicine* 2020;4:555–7.
2. Ukoha UU, Umeasalugo KE, Okafor JL, Ndukwe GU, Nzeakor HC, Ekwunife DO. Morphology and morphometry of dry adult acetabula in Nigeria. *Revista Argentina Anatomia Clinica* 2014;6:150–5.
3. Zeng Y, Wang Y, Zhu Z, Tang T, Dai K, Qiu S. Differences in acetabular morphology related to side and sex in a Chinese population. *J Anat* 2012;220:256–62.
4. Vyas K, Shroff B, Zanzrukiya K. An osseous study of morphological aspect of acetabulum of hip bone. *International Journal of Research in Medicine* 2013;2:78–82.
5. Solomon LB, Howie DW, Henneberg M. The Variability of the volume of os coxae and linear pelvic morphometry. considerations for total hip arthroplasty. *J Arthroplasty* 2014;29:769–76.
6. Aksu FT, Çeri NG, Arman C, Tetik S. Morphology and morphometry of the acetabulum. *Dokuz Eylül Üniversitesi Tıp Fakültesi Dergisi* 2006;20:143–8.
7. Sreedevi G, Sangam MR. The study of morphology and morphometry of acetabulum on dry bones. *International Journal of Anatomy and Research* 2017;5:4558–62.
8. Maruyama M, Feinberg JR, Capello WN, D'Antonio JA. Morphologic features of the acetabulum and femur: anteversion angle and implant positioning. *Clin Orthop Relat Res* 2001;(393):52–65.
9. Govsa F, Ozer MA, Ozgur Z. Morphologic features of the acetabulum. *Arch Orthop Trauma Surg* 2005;125:453–61.
10. Indurjeeth K, Ishwarkumar S, De Gama BZ, Ndrazi Z, Pillay P. Morphometry and morphology of the acetabulum within the black African population of South Africa. *Int J Morphol* 2019;37:971–6.
11. Yugesh K, Kumar SS. Morphometric analysis of acetabulum and its clinical correlation in South Indian population. *International Journal of Advanced Research* 2016;2:1011–4.
12. Chauhan R, Paul S, Dhaon B. Anatomical parameters of North Indian hip joints: cadaveric study. *J Anat Soc India* 2002;51:39–42.
13. Parmara G, Rupareliab S, Patele S, Patell S, Jethvaa N. Morphology and morphometry of acetabulum. *International Journal of Biological and Medical Research* 2013;4:2924–6.

### ORCID ID:

M. Taşci 0000-0001-9428-1189;  
B. Pirinç 0000-0002-6927-1306;  
B. Sevindik 0000-0003-1287-5544;  
N. Ünver Doğan 0000-0001-5696-5547

deomed®

### Correspondence to:

Büşra Pirinç, PhD  
Department of Anatomy, Faculty of Medicine,  
Selçuk University, 42130, Konya, Türkiye  
Phone: +90 332 224 38 49  
e-mail: busrapirinç2016@gmail.com

*Conflict of interest statement:* No conflicts declared.

This is an open access article distributed under the terms of the Creative Commons Attribution-NonCommercial-NoDerivs 4.0 Unported (CC BY-NC-ND4.0) Licence (<http://creativecommons.org/licenses/by-nc-nd/4.0/>) which permits unrestricted noncommercial use, distribution, and reproduction in any medium, provided the original work is properly cited. *How to cite this article:* Taşci M, Pirinç B, Sevindik B, Ünver Doğan N. Evaluation of the morphological and morphometric characteristics of the acetabulum in the Anatolian population. *Anatomy* 2023;17(1):34–40.