

## Evaluation of Cold Conization Indications and Results

### Soğuk Konizasyon Endikasyonlarının ve Sonuçlarının Değerlendirilmesi

<sup>1</sup>Sinem TEKİN

<sup>1</sup>Department of Obstetrics and Gynecology, Haseki Training and Research Hospital, Istanbul; Türkiye

Sinem Tekin: <https://orcid.org/0000-0003-4183-6472>

#### ABSTRACT

**Objective:** The aim of this study was to determine the efficiency and indications of cold knife conization in the treatment of high-grade cervical lesions.

**Materials and Methods:** This study included patients with high-grade cervical lesions treated with cold knife conization (CKC) within 9 years. Histopathological correlation analyses were carried out among the smear, colposcopic biopsy (CBx), CKC results, and total hysterectomy specimens available.

**Results:** One hundred thirty-one cold knife cone biopsy cases were analyzed for this study. The most common pathology was cervical intraepithelial neoplasia (CIN) II–III, with a frequency of 64 (48.9%). Other conization results in order of frequency were as follows: CIN I at a rate of 29 (22.1%), Carcinoma (Ca) at 19 (14.5%), cervicitis at 14 (10.7%), and negative results at 5 (3.8%).

**Conclusions:** CKC remains an acceptable option in the treatment of CIN and microinvasive carcinoma of the cervix, and the excellent diagnostic and therapeutic efficacy of CKC is well-known and confirmed. When properly performed, the procedure has a low risk of complications and provides an accurate histological representation of the disease process. It is also curative in most cases. Of course, excellent clinical results still require careful, long-term, and attentive follow-up.

**Keywords:** Cervical intraepithelial neoplasia, cervical smear, cold knife conization

#### ÖZ

**Amaç:** Bu çalışmanın amacı yüksek dereceli servikal lezyonların tedavisinde soğuk konizasyonunun etkinliğini ve endikasyonlarını belirlemektir.

**Materyal ve Metot:** Bu çalışmaya 9 yıllık süreçte yüksek dereceli servikal lezyonu olan ve soğuk konizasyon ile tedavi edilen hastalar dahil edildi. Smear, kolposkopik biyopsi, soğuk konizasyon sonuçları ve mevcut total histerektomi spesimenleri arasında histopatolojik korelasyon yapıldı.

**Bulgular:** Yüz otuz bir soğuk koni biyopsisi bu çalışma için analiz edildi. En sık görülen patoloji 64 (%48,9) ile CIN II-III idi. Diğer konizasyon sonuçları sıklık sırasına göre şöyledir; CIN I 29 (%22,1), Karsinom (Ca) 19 (%14,5), servisit 14 (%10,7), negatif 5 (%3,8).

**Sonuç:** Soğuk konizasyon, serviks servikal intraepitelyal neoplazi (CIN) ve mikroinvaziv karsinomunun tedavisinde kabul edilebilir bir seçenek olmaya devam etmekte ayrıca tanısal ve terapötik etkinliği iyi bilinmektedir. Uygun şekilde yapıldığında, doğru bir histopatolojik tanı sağlar ve düşük komplikasyon riskine sahiptir; ayrıca çoğu vakada küratiftir. Elbette, mükemmel klinik sonuçlar yine de dikkatli, uzun süreli ve özenli bir takip gerektirmektedir.

**Anahtar Kelimeler:** Servikal intraepitelyal neoplazi, servikal smear, soğuk konizasyon

#### Sorumlu Yazar / Corresponding Author:

Sinem Tekin  
Department of Obstetrics and Gynecology, Haseki Training and Research Hospital, Sultangazi, İstanbul, Türkiye.  
Tel: +905057900571  
E-mail: drsinemtekin@gmail.com

#### Yayın Bilgisi / Article Info:

Gönderi Tarihi/ Received: 27/02/2024  
Kabul Tarihi/ Accepted: 27/07/2024  
Online Yayın Tarihi/ Published: 16/09/2024

**Atf / Cited:** Tekin S. Evaluation of Cold Conization Indications and Results. *Online Türk Sağlık Bilimleri Dergisi* 2024;9(3):224-231. doi: 10.26453/otjhs.1443698

## INTRODUCTION

Cervical health is recognized as a critical component of the female reproductive system, playing an important role in fertility and overall well-being. However, in certain cases, abnormal changes can occur in the cells of the cervix, a condition known as cervical intraepithelial neoplasia (CIN). CIN refers to precancerous changes in the epithelial cells of the cervix and is a significant health risk for women worldwide, potentially progressing to cervical cancer if left untreated.<sup>1</sup> CIN cases are histologically confirmed on a biopsy specimen and categorized as CIN I (mild dysplasia), CIN II (moderate dysplasia), or CIN III (severe dysplasia or carcinoma in situ). CIN II and CIN III patients must be treated since untreated cases have low spontaneous regression rates (32-43%) and a high risk of invasive cancer (5-22%).<sup>2</sup>

Surgical techniques are available for the treatment of high-grade CIN. Cold knife cervical conization (CKC), a conservative surgical approach for treating CIN II and CIN III, was first described by Lisfranc in 1815 and can be performed using a cold knife, CO2 laser, or electrical loop electrodes (LLETZ, i.e., loop electrosurgical excisional procedure, LEEP).<sup>3</sup>

In CKC surgery, a cone-shaped piece of the cervix is excised to remove a cervical lesion and the entire transformation zone.<sup>4</sup> CKC allows the histological confirmation of the lesion, the exclusion of invasive neoplasia, and the evaluation of resection margins. CKC provides more extensive tissue sampling for pathology than other procedures, but a wide and deep cervical cone excision can cause bleeding, infection, cervical stenosis, and mid-trimester pregnancy loss.<sup>5</sup> The rate of success (i.e., no residual disease at follow-up) of knife cone biopsy was reported to be 90% to 94% in non-randomized studies.<sup>6</sup>

We aimed to evaluate the indications and histopathological outcomes of Turkish women undergoing CKC for the treatment of CIN II/III.

## MATERIALS AND METHODS

**Ethic Committee Approval:** The Declaration of Helsinki was followed in the study. Our study was approved by the Non-Interventional Clinical Research Ethics Committee of Kartal Training and Research Hospital (Date:30.05.2017, decision no: 2017/514/108/7).

**Data collection:** Patient identification in Kartal Training and Research Hospital was accomplished by examining admission logs from accessible medical data. The data were obtained from the hospital information system by experienced research physicians.

**Study Design and Participants:** This retrospective study conducted at Kartal Training and Research

Hospital's Department of Obstetrics and Gynecology between 2008 and 2017 involved 131 patients who underwent CKC for diagnosed CIN II and CIN III based on cervical cytology or biopsy. Other indications for CKC included unsatisfactory colposcopy, positive endocervical curettage, and suspicion of microinvasive disease, while women with a history of hysterectomy, recent pregnancy, or other gynecologic malignancies were excluded from the study. Patients undergoing CKC underwent scalpel excisions under general or regional anesthesia. Colposcopic examination with 3% to 5% acetic acid to delineate the transformation zone, followed by a circumferential incision, was made with a long-handled scalpel. Starting posteriorly, the scalpel blade was placed at the desired depth and direction, and a conical portion of the cervix was then removed. Hemostasis was achieved using bilateral interrupted vertical sutures, and vaginal packing was inserted for 12 hours. Specimens were evaluated by experienced pathologists at our hospital's Pathology Department. Positive margins were defined by the presence of HSIL or cancer within  $\leq 1$  mm of the resection surface. Further surgery, including radical hysterectomy and pelvic lymphadenectomy, was performed for patients with cancerous margins or cases unsuitable for fertility preservation. For each patient, data were collected on age, preoperative cytology and colposcopy results, indication for conization, histology of cone specimen, and results of subsequent follow-up and management.

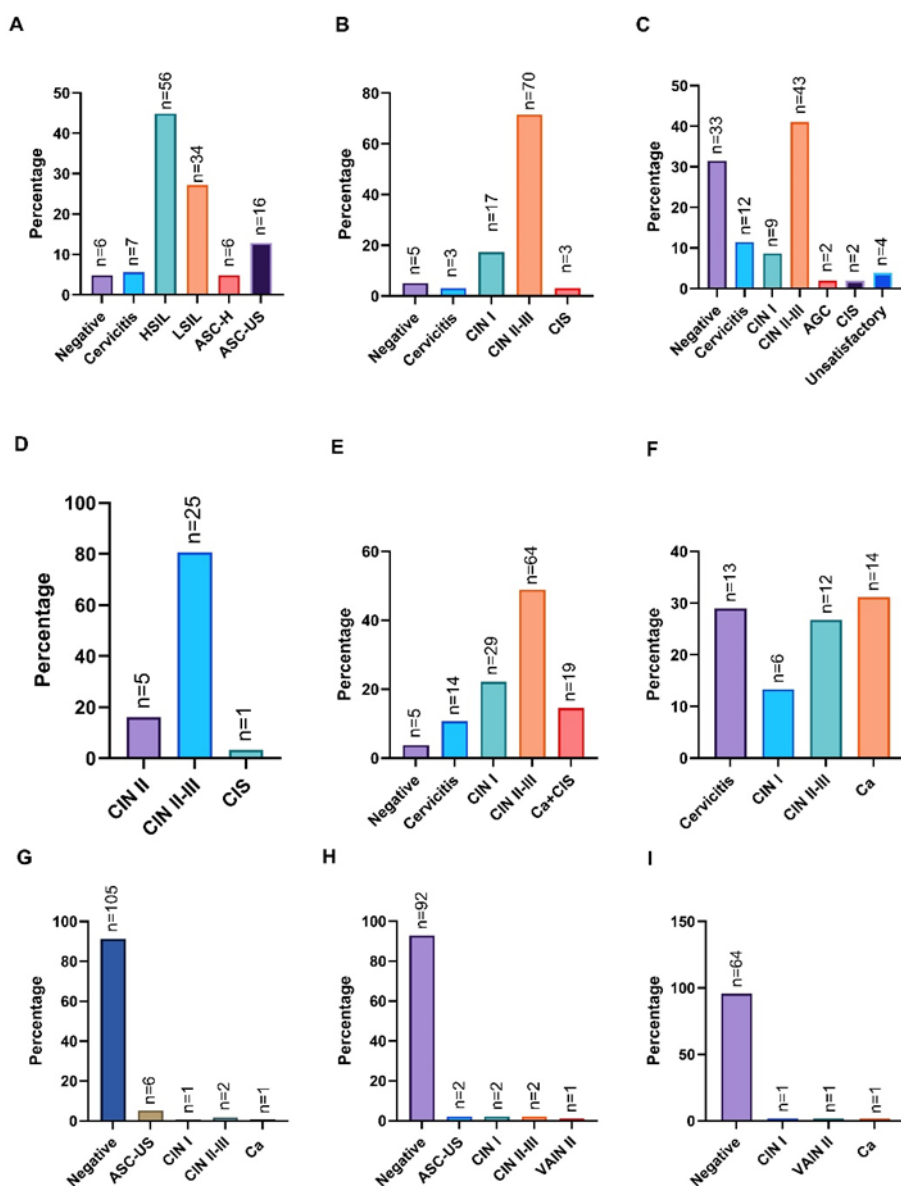
**Statistical Analysis:** The statistical analyses were performed using SPSS version 23.0 (IBM SPSS, USA) or GraphPad Prism 9.x (GraphPad, USA). Continuous variables were represented as mean (M)  $\pm$  standard deviation (SD); discrete variables were represented as frequency (n) and percentage distribution.

## RESULTS

131 CKC cases were analyzed in this study. First pap test results (FPRs) were available for 125 of these patients. Figure 1A shows the FPR of 125 cases assessed, and the results of 98 colposcopic biopsies (CBx) were available (Figure 1B). Figure 1C shows the distribution of pathologies in endocervical curettage (ECC) specimens of 105 cases and Figure 1D shows the results of 31 patients who underwent LEEP prior to conization. Conization findings for 131 patients are shown in Figure 1E. The most common pathology was CIN II-III with a frequency of 64 (48.9%). The highest mean age was 59.6 $\pm$ 13.60 years in the carcinoma (Ca)/carcinoma in situ (CIS) group. Hysterectomy was performed on 45 patients, with pathology outcomes depicted in Figure 1F. Ca emerged as the predominant pathology among hys-

terectomized women, accounting for 14 (31.1%). The depth of invasion was measured in 10 hysterectomized patients with Ca pathology: 3 mm in 2 patients, 8 mm in 2 patients, 9 mm in 1 patient, 10 mm in 2 patients, 12 mm in 1 patient, and 13 mm in 2 patients. The mean depth was  $8.9 \pm 3.60$  mm. Furthermore, radiotherapy was administered to 9 patients with Ca pathology identified post-hysterectomy. Patients who underwent CKC or subsequent hysterectomy were followed up with smear tests at 3, 6, and 9 months, coded as the first follow-up pap tests (FPTs), as shown in Figure 1G. One patient who had a type 2 hysterectomy for squamous

cell carcinoma had a 6-month follow-up smear showing carcinoma. The 2nd FPTs were performed for 1 year (Figure 1H). Among the 99 patients with 2nd FPTs, 92 (92.9%) had normal results. 2 (2%) patients had ASC-US, 2 (2%) patients had CIN I, 2 (2%) patients had CIN II-III, and 1 (1%) patient had VAIN II. The 3rd FPTs were performed between years 1 and 8. Most of the samples were taken in years 3 and 4. The results of the 3rd FPTs of 67 cases are shown in Figure 1I. 64 (95.5%) of these results were normal, 1 (1.5%) result was compatible with CIN I, 1 (1.5%) was compatible with VAIN II, and 1 (1.5%) was compatible with Ca.



**Figure 1.** A. Distribution of FPRs; B. Distribution of CBX; C. Distribution of pathologies of ECC specimens; D. Distribution of biopsy pathologies of LEEP cases; E. Distribution of pathology results of patients who underwent conization; F. Distribution of pathology results of patients who underwent hysterectomy; G. First FPT results; H. 2nd FPT results; I. 3rd FPT results.

Table 1 presents a comparison of CBx and FPRs. CBx results of two patients with negative Pap tests were CIN II-III. Of the 5 patients with seven cervicitis on their FPR, 4 had CIN II-III on CBx.

The comparison of the FPRs and conization results is shown in Table 2. The conization results of 2 patients with negative FPRs were CIN II-III. Three patients with cervicitis in their conization results were CIN II-III. Of the 56 patients whose FPRs were HSIL, 11 had Ca/CIS, 29 had CIN II-III, 9 had CIN I, 5 had cervicitis, and 2 were negative based on conization results. Of the 33 patients whose FPRs showed LSIL, 2 had Ca/ CIS, 19 had CIN II-III, 7 had CIN I, 3 had cervicitis, and 2 were negative based on conization results. Of the 6 patients whose FPRs indicated ASC-H, 1 had Ca/CIS, 2 had CIN II-III, 1 had CIN I, and 2 had cervicitis based on conization results.

Table 3 compares the results of CBx, LEEP, conization, and hysterectomy according to the results of the FPRs of the patients. Of the 6 patients whose FPRs were negative, two had CIN II-III, three had CIN I, and one had cervicitis detected in conization

performed for other reasons. One of them underwent a hysterectomy, and the result was CIN II-III. Of the 7 patients whose FPRs came back as cervicitis, 2 were found to have CIN II-III in the results of the conization procedures performed for other reasons. One of them underwent a hysterectomy, and the result was cervicitis. Of 56 patients with HSIL in their FPRs, 13 underwent LEEP, and 1 was found to have CIS. The pathology results of the conization outcomes were as follows: 11 Ca/CIS, 29 CIN II-III, 9 CIN I, 5 cervicitis, and 1 negative. Twenty-five of these cases underwent hysterectomies. The pathology results of their slides were Ca/CIS, 9 were CIN II-III, 3 were CIN I, and 5 were cervicitis. Among the 34 patients whose FPRs were LSIL, 2 had a conization result of Ca/CIS. Seven underwent hysterectomies, and 1 of them had a result of Ca/CIS. The conization result of 1 patient with ASC-H smear was Ca/CIS. Interestingly, the conization result of one patient whose FPR was ASC-US was Ca/CIS; this patient underwent a hysterectomy, and the pessary result was the same.

**Table 1.** Distribution of results of colposcopic biopsy and first Pap test results.

First Pap test	Biopsy				
	Negative n (%)	Cervicitis n (%)	CIN I n (%)	CIN II-III n (%)	Ca/CIS n (%)
Negative	2 (40.0)	0 (0)	2 (11.8)	2 (2.9)	0 (0)
Cervicitis	0 (0)	0 (0)	1 (5.9)	4 (5.9)	0 (0)
HSIL	1 (20.0)	1 (33.3)	3 (17.6)	33 (48.5)	1 (33.3)
LSIL	1 (20.0)	2 (66.7)	6 (35.3)	19 (27.9)	0 (0)
ASC-H	0 (0)	0 (0)	0 (0)	4 (5.9)	1 (33.3)
ASC-US	1 (20.0)	0 (0)	5 (29.4)	6 (8.8)	1 (33.3)
<b>Total</b>	<b>5 (100)</b>	<b>3 (100)</b>	<b>17 (100)</b>	<b>68 (100)</b>	<b>3 (100)</b>

HSIL: High-grade squamous intraepithelial lesion; LSIL: Low-grade squamous intraepithelial lesion; ASC-H: Atypical squamous cells -cannot exclude high-grade squamous intraepithelial lesion; ASC-US: Atypical squamous cells of undetermined significance; CIN: Cervical intraepithelial neoplasia; Ca/CIS: Carcinoma / Carcinoma in situ.

**Table 2.** Distribution of results of first Pap test results and conization.

First Pap test	Conization				
	Negative n (%)	Cervicitis n (%)	CIN I n (%)	CIN II-III n (%)	Ca/CIS n (%)
Negative	0 (0)	1 (7.7)	3 (10.3)	2 (3.2)	0 (0)
Cervicitis	1 (20.0)	1 (7.7)	2 (6.9)	3 (4.8)	0 (0)
HSIL	2 (40.0)	5 (38.5)	9 (31.0)	29 (46.8)	11 (73.3)
LSIL	2 (40.0)	3 (23.1)	7 (24.1)	19 (30.6)	2 (13.3)
ASC-H	0 (0)	2 (15.4)	1 (3.4)	2 (3.2)	1 (6.7)
ASC-US	0 (0)	1 (7.7)	7 (24.1)	7 (11.3)	1 (6.7)
<b>Total</b>	<b>5 (100)</b>	<b>13 (100)</b>	<b>29 (100)</b>	<b>62 (100)</b>	<b>15 (100)</b>

HSIL: High-grade squamous intraepithelial lesion; LSIL: Low-grade squamous intraepithelial lesion; ASC-H: Atypical squamous cells -cannot exclude high-grade squamous intraepithelial lesion; ASC-US: Atypical squamous cells of undetermined significance; CIN: Cervical intraepithelial neoplasia; Ca/CIS: Carcinoma / Carcinoma in situ.

**Table 3.** Comparison of CBx, LEEP, conization, and hysterectomy outcomes according to FPRs.

Biopsy under Colposcopic Observation	Negative n (%)	Cervicitis n (%)	HSIL n (%)	LSIL n (%)	ASC-H n (%)	ASC-US n (%)
<b>Negative</b>	2 (33.3)	0 (0)	1 (2.6)	1 (3.6)	0 (0)	1 (7.7)
<b>Cervicitis</b>	0 (0)	0 (0)	1 (2.6)	2 (7.1)	0 (0)	0 (0)
<b>CIN I</b>	2 (33.3)	1 (20)	3 (7.7)	6 (21.4)	0 (0)	5 (38.5)
<b>CIN II-III</b>	2 (33.3)	4 (80)	33 (84.7)	19 (67.9)	4 (80)	6 (46.2)
<b>AGC/CIS</b>	0 (0)	0 (0)	1 (2.6)	0 (0)	1 (20)	1 (7.7)
<b>LEEP</b>	Negative	Cervicitis	HSIL	LSIL	ASC-H	ASC-US
<b>CIN II</b>	0 (0)	1 (50)	2 (16.4)	2 (22.2)	0 (0)	0 (0)
<b>CIN II-III</b>	0 (0)	1 (50)	10 (76.0)	7 (77.8)	3 (100)	3 (100)
<b>Ca/CIS</b>	0 (0)	0 (0)	1 (7.6)	0 (0)	0 (0)	0 (0)
<b>Conization</b>	Negative	Cervicitis	HSIL	LSIL	ASC-H	ASC-US
<b>Negative</b>	0 (0)	1 (14.3)	2 (3.6)	2 (6.1)	0 (0)	0 (0)
<b>Cervicitis</b>	1 (16.7)	1 (14.3)	5 (8.9)	3 (9.1)	2 (33.3)	1 (6.3)
<b>CIN I</b>	3 (50)	2 (28.6)	9 (16.1)	7 (21.2)	1 (16.7)	7 (43.8)
<b>CIN II-III</b>	2 (33.3)	3 (42.9)	29 (51.8)	19 (57.6)	2 (33.3)	7 (43.8)
<b>CA/CIS</b>	0 (0)	0 (0)	11 (19.6)	2 (6.1)	1 (16.7)	1 (6.3)
<b>Hysterectomy</b>	Negative	Cervicitis	HSIL	LSIL	ASC-H	ASC-US
<b>Cervicitis</b>	0 (0)	1 (100)	5 (20)	4 (57.1)	1 (50)	1 (20)
<b>CIN I</b>	0 (0)	0 (0)	3 (12.2)	1 (14.3)	0 (0)	2 (40)
<b>CIN II-III</b>	1 (100)	0 (0)	9 (36.0)	1 (14.3)	0 (0)	1 (20)
<b>CA/CIS</b>	0 (0)	0 (0)	8 (32.0)	1 (14.3)	1 (50)	1 (20)

HSIL: High-grade squamous intraepithelial lesion; LSIL: Low-grade squamous intraepithelial lesion; ASC-H: Atypical squamous cells - cannot exclude high-grade squamous intraepithelial lesion; ASC-US: Atypical squamous cells of undetermined significance; CIN: Cervical intraepithelial neoplasia; Ca/CIS: Carcinoma / Carcinoma in situ.

**DISCUSSION AND CONCLUSION**

Cervical cancer is one of the most preventable and treatable malignancies. Yet, it is the fourth most diagnosed cancer in women of reproductive age worldwide, with the highest incidence in resource-limited countries. Cervical cancer can be diagnosed early with pap smear tests and Human papillomavirus (HPV) screening. HPV DNA testing in combination with cervical smear testing has been reported to increase the likelihood of detecting CIN II-III by %35.<sup>7,8</sup> We conducted this study to evaluate the results of CKC, a procedure we have performed more frequently in our clinic in the past.

The study was unable to evaluate HPV DNA due to the limited availability of HPV DNA testing at that time. In our study, the sensitivity and specificity of the cervical smear test alone, without HPV testing, were shown to be low. For example, one of the 14 patients with CIS had ASCUS in the first smear. This suggests that a single smear in management has low reliability and should be used in conjunction with HPV. This is why co-testing is increasingly preferred for screening.<sup>9</sup>

HSIL is a well-characterized precursor lesion of cervical invasive squamous cell carcinoma.<sup>10</sup> In this study, the FPRs of 11 of 15 (73.3%) patients with CA/CIS detected as a result of conization was HSIL. In a systematic review of 27 articles, the mean CIN2+ percentage in women with cytologically detected HSIL was %77.5.<sup>11</sup>

There have been some studies that have investigated the optimal cone size to reduce surgical field positiv-

ity. According to the results of these studies, there is no optimal cone size and depth that can be routinely applied to every patient.<sup>12</sup> Our study did not include data on the size of the cones removed, so the positive surgical margin could not be compared to the size and depth of the cones. In this study, all 131 patients had FPT for the first 3 years after conization and hysterectomy, if available. Only 1 patient who had a pathology of adenoid basal carcinoma showed malignant squamous cell carcinoma in her smear test in the 3rd year. One year after treatment, the smear test result was negative. Follow-up smear samples taken from all other patients were either ASC-US or negative, except for a few HSIL cases.

There are few articles on postoperative positive margins. A meta-analysis that included 1596 patients revealed that 200 patients (13%) had lesions at the surgical margins.<sup>13,14</sup> In this study, 25 patients (18.7%) had a positive surgical margin after conization. Compared to other studies, positive surgical margins were more prevalent in our study.<sup>15-17</sup> Among the 25 patients who had a positive surgical margin, two patients underwent re-conization, and 23 patients underwent type 1 or type 2 hysterectomy. In three of them, the conization results were CIN III, and because their surgical margins were positive, a hysterectomy was performed, and the hysterectomy pieces were identified as squamous cell carcinoma. Purut et al. studied the effects of HPV subtypes in patients with positive surgical margins after conization. In our study, HPV could not be evaluated, so we could not comment much on it.<sup>18</sup>

However, when we looked at the first smear test results of the patient, 19 of 25 (76%) patients had HSIL, 3 (12%) had ASC-US, 2 (8%) were negative, and 1 (4%) had ASC-H.

So far, many studies with cold conization have compared cold conization and Loop Electrosurgical Excision. The advantages and disadvantages of each have been compared.<sup>19-21</sup> On the other hand, in our study, we only evaluated cold conization. The status of the surgical margin in a pathological examination can be more appropriately determined by CKC. A thermal artefact remains the main concern of Loop Electrosurgical Excision.<sup>22</sup> It was reported that morbidity was significantly reduced in the Loop Electrosurgical Excision group, the operative time was shortened, blood loss was reduced, the infection rate decreased in the 2nd postoperative week, and the secondary bleeding rate decreased.<sup>23</sup> Thus, the conventional surgical technique has been recently replaced by laser conization and LEEP in many Western countries.<sup>24-26</sup>

Severe bleeding, especially in the postoperative period, is a major complication of CKC.<sup>27,28</sup> We achieved hemostasis with bilateral interrupted vertical sutures placed after packing the cervical crater with Oxycell. In two patients, postoperative bleeding developed, but it was stopped with transaminated tamponade. No additional procedure was required. CKC has the potential to cause cervical incompetence, which subsequently leads to abortion or preterm delivery during the following pregnancy.<sup>29,30</sup> In our study, two patients had a pregnancy after conization. The first one had a cesarean section at 38 weeks, and the other one had a vaginal delivery at 35 weeks with cerclage at 17 weeks.

A limitation of our study was the unavailability of HPV testing in our hospital during that period, resulting in the evaluation of patients solely by smears. As a result, it was not feasible to compare the outcomes of HPV and conization or to subsequently follow HPV. Additional limitations include the study's non-randomized and retrospective procedure, as well as the limited number of patients enrolled in the trial. To validate the effectiveness of this modified conization procedure, it is necessary to conduct a larger-scale, randomized, controlled research.

In conclusion, cold knife conization remains an acceptable option in the treatment of CIN and microinvasive carcinoma of the cervix, and the excellent diagnostic and therapeutic efficacy of cold knife conization is well-known and confirmed. When properly performed, the procedure has a low risk of complications and provides an accurate histological representation of the disease process. It is also curative in most cases. Of course, excellent clinical results still require careful, long-term, and attentive

follow-up.

**Ethics Committee Approval:** The Declaration of Helsinki was followed in the study. Our study was approved by the Non-Interventional Clinical Research Ethics Committee of Kartal Training and Research Hospital (Date:30.05.2017, decision no: 2017/514/108/7).

**Conflict of Interest:** No conflict of interest was declared by the authors.

**Author Contributions:** Concept – ST; Supervision – ST; Materials – ST; Data Collection and/or Processing –ST; Analysis and/or Interpretation – S.T; Writing – ST.

**Peer-review:** Externally peer-reviewed.

**Acknowledgement:** I am deeply grateful to my thesis advisor, the late Prof. Dr. Zehra Meltem Pirimoğlu, for guiding, supporting, and teaching me during my gynecology and obstetrics residency. Your teachings and inspiration continue to resonate in my life and work. Thank you endlessly.

## REFERENCES

1. Farzaneh F, Faghih N, Hosseini MS, Arab M, Ashrafganjoei T, Bahman A. Evaluation of neutrophil-lymphocyte ratio as a prognostic factor in cervical intraepithelial neoplasia recurrence. *Asian Pac J Cancer Prev.* 2019;20(8):2365-2372. doi:10.31557/APJCP.2019.20.8.2365
2. Santesso N, Mustafa RA, Wiercioch W, et al. Systematic reviews and meta-analyses of benefits and harms of cryotherapy, LEEP, and cold knife conization to treat cervical intraepithelial neoplasia. *Int J Gynaecol Obstet.* 2016;132(3):266-271. doi:10.1016/j.ijgo.2015.07.026
3. Van de Vijver A, Poppe W, Verguts J, Arbyn M. Pregnancy outcome after cervical conisation: a retrospective cohort study in the Leuven University Hospital. *BJOG.* 2010;117(3):268-273. doi:10.1111/j.1471-0528.2009
4. Gao Y, Wang H, Xiao Y. The effect of cold knife conization on pregnancy outcomes in patients with cervical lesions. *PLoS One.* 2022;17(12):e0278505. doi:10.1371/journal.pone.0278505
5. Martin-Hirsch PP, Paraskevaidis E, Bryant A, Dickinson HO. Surgery for cervical intraepithelial neoplasia. *Cochrane Database Syst Rev.* 2013;13(12):CD001318. doi:10.1002/14651858
6. Obut M, İskender CT, Kırdan A, et al. Factors affecting obstetric outcomes in patients who underwent cold-knife and loop electrosurgical excision procedure conization due to CIN 2 or CIN 3. *J Turk Ger Gynecol Assoc.* 2023. doi:10.4274/jtgg.galenos.2023-1-15
7. Ma X, Yang M. The correlation between high-risk HPV infection and precancerous lesions and

- cervical cancer. *Am J Transl Res.* 2021;13(9):10830-10836.
8. Pourroostaei Ardakani P, Abkhiz S, Sheykhi K, et al. Molecular investigation of the association among common interleukin-6 polymorphism and human papillomavirus genotypes with cervical cancer among Iranian women. *Monoclon Antib Immunodiagn Immunother.* 2023;42(4):125-131. doi:10.1089/mab.2022.0039
  9. Bhatla N, Singhal S. Primary HPV screening for cervical cancer. *Best Pract Res Clin Obstet Gynecol.* 2020;65:98-108. doi:10.1016/j.bpobgyn.2020.02.008
  10. Kurmyshkina OV, Dobrynin PV, Kovchur PI, Volkova TO. Sequencing-based transcriptome analysis reveals diversification of immune response- and angiogenesis-related expression patterns of early-stage cervical carcinoma as compared with high-grade CIN. *Front Immunol.* 2023;14:1215607. doi:10.3389/fimmu.2023.1215607
  11. Ruan Y, Liu M, Guo J, Zhao J, Niu S, Li F. Evaluation of the accuracy of colposcopy in detecting high-grade squamous intraepithelial lesion and cervical cancer. *Arch Gynecol Obstet.* 2020;302(6):1529-1538. doi:10.1007/s00404-020-05740-x
  12. Papoutsis D, Underwood M, Parry-Smith W, Tzavara C. Endocervical crypt involvement by high-grade cervical intraepithelial neoplasia and its association with high-grade histopathological recurrence after cervical excision in women with negative excision margins: a systematic review and meta-analysis. *Arch Gynecol Obstet.* 2024;309(3):939-948. doi:10.1007/s00404-023-07242-y
  13. Cai L, Huang Y, Lin C, et al. A comparison study of post-operative infection analysis of cold knife conization and loop electrosurgical excision procedure for cervical high-grade squamous intraepithelial lesion. *Transl Cancer Res.* 2020;9(2):949-957. doi:10.21037/tcr.2019.12.34
  14. A J, Lei H, Xie X, Sun P. An abnormal precone endocervical curettage result is an independent risk factor for positive margins in conization specimens. *Oncol Res Treat.* 2020;43(10):518-525. doi:10.1159/000509254
  15. Zeng Y, Jiang T, Zheng Y, et al. Risk factors predicting residual lesion in subsequent hysterectomy following cold knife conization (CKC) for high-grade squamous intraepithelial lesion (HSIL). *BMC Womens Health.* 2022;22(1):358. doi:10.1186/s12905-022-01939-z
  16. Mohamed-Noor K, Quinn MA, Tan J. Outcomes after cervical cold knife conization with complete and incomplete excision of abnormal epithelium: a review of 699 cases. *Gynecol Oncol.* 1997;67(1):34-8. doi:10.1006/gyno.1997
  17. Reich O, Lahousen M, Pickel H, Tamussino K, Winter R. Cervical intraepithelial neoplasia III: long-term follow-up after cold-knife conization with involved margins. *Obstet Gynecol.* 2002;99(2):193-6. doi:10.1016/s0029-7844(01)01683-0
  18. Purut YE, Giray B, Akis S, et al. Effect of Human Papillomavirus Subtype on the Rate of Positive Surgical Margin After Cervical Conization. *Int J Surg Pathol.* 2023;31(1):20-25. doi:10.1177/10668969221143460
  19. Kim YT, Kim JW, Kim DK, Song CH. Loop diathermy and cold knife conization in patients with cervical intraepithelial neoplasia: a comparative study. *J Korean Med Sci.* 1995;10(4):281-6. doi:10.3346/jkms.1995.10.4.281
  20. Cooper DB, Carugno J, Dunton CJ, Menefee GW. Cold knife conization of the cervix. 2023 Oct 26. In: StatPearls [Internet]. Treasure Island (FL): StatPearls Publishing; 2024.
  21. Jiang Y, Chen C, Li L. Comparison of cold-knife conization versus loop electrosurgical excision for cervical adenocarcinoma in situ (ACIS): A systematic review and meta-analysis. *PLoS One.* 2017;12(1):e0170587. doi:10.1371/journal.pone.0170587
  22. Baiocchi G, Diniz TP, Bovolim G, et al. Predictive factors for residual disease after conization in cervical cancer. *Ann Surg Oncol.* 2021;28(11):6673-6681. doi:10.1245/s10434-021-09656-x
  23. Cohen PA, Leung Y, Anderson L, et al. Excisional treatment comparison for in situ endocervical adenocarcinoma (EXCISE): A phase 2 pilot randomized controlled trial to compare histopathological margin status, specimen size and fragmentation after loop electrosurgical excision procedure and cold knife cone biopsy. *Gynecol Oncol.* 2020;159(3):623-629. doi:10.1016/j.ygyno.2020.09
  24. Ikeda M, Mikami M, Yasaka M, et al. Association of menopause, aging and treatment procedures with positive margins after therapeutic cervical conization for CIN 3: a retrospective study of 8,856 patients by the Japan Society of Obstetrics and Gynecology. *J Gynecol Oncol.* 2021;32(5):e68. doi:10.3802/jgo.2021.32.e68
  25. Mosseri J, Hocquemiller R, Mergui JL, Uzan C, Canlorbe G. Laser conization for cervical intraepithelial neoplasia: Effectiveness and obstetric outcomes. *J Gynecol Obstet Hum Reprod.* 2022;51(4):102341. doi:10.1016/j.jogoh.2022.102341
  26. Bogani G, DI Donato V, Sopracordevole F, et al. Recurrence rate after loop electrosurgical excision procedure (LEEP) and laser conization: A 5-year follow-up study. *Gynecol Oncol.* 2020;159(3):636-641. doi:10.1016/j.ygyno.2020.08.025

27. Bueno LR, Binda M, Monego H, et al. Randomized clinical trial comparing cold knife conization of the cervix with and without lateral hemostatic sutures. *Int J Surg.* 2015; 18:224-9. doi:10.1016/j.ijso.2015.04.081
28. Wang X, Li L, Bi Y, Wu H, Wu M, Lang J. The effects of different instruments and suture methods of conization for cervical lesions. *Sci Rep.* 2019 13;9(1):19114. doi:10.1038/s41598-019-55786-4
29. Song T, Seong SJ, Kim BG. Regeneration process after cervical conization for cervical intraepithelial neoplasia. *Obstet Gynecol.* 2016;128(6):1258-1264. doi:10.1097/AOG.0000000000001755
30. Zebitay AG, Güngör ES, İlhan G, et al. Cervical conization and the risk of preterm birth: A population-based multicentric trial of Turkish cohort. *J Clin Diagn Res.* 2017;11(3):QC21-QC24. doi:10.7860/JCDR/2017/22996.9495