





## Research Article | Araştırma Makalesi

# EVALUATION OF DONOR CANDIDATES USING MULTI-DETECTOR COMPUTED TOMOGRAPHY ANGIOGRAPHY IN PREPARATION FOR RENAL TRANSPLANTATION

## RENAL TRANSPLANTASYON HAZIRLIĞINDA MULTI-DEDEKTÖR BİLGİSAYARLI TOMOGRAFİ ANJİYOĞRAFİ İLE DONÖR ADAYLARININ DEĞERLENDİRİLMESİ

 Demet Dogan<sup>1</sup>,  Kagan Gokce<sup>2\*</sup>,  Taner Kivilcim<sup>2</sup>,  Alp Gurkan<sup>2</sup>

<sup>1</sup>Istanbul Okan University, School of Medicine, Department of Radiology, Istanbul, Türkiye. <sup>2</sup>Istanbul Okan University, School of Medicine, Department of General Surgery, Istanbul, Türkiye.



### ABSTRACT

**Objective:** Renal and extrarenal intra-abdominal findings in Multi-Detector Computed Tomography Angiography (MDCTA) imaging of kidney donor candidates, which may prevent the candidate from becoming a donor, or cause a change in surgical approach. We aim to underline the impact of MDCTA results on pre-transplant kidney donor evaluation.

**Methods:** Our study retrospectively evaluated renal MDCTA imaging performed on 496 kidney donor candidates at Okan University Faculty of Medicine Hospital between January 2017 and November 2022. The size and parenchymal thickness of both kidneys were measured. The diameter, number, variations, and anomalies of the renal artery and vein on both sides were determined. Findings that prevented kidney transplantation were detected. MDCTA findings and how these findings affected the surgical approach were determined.

**Results:** Of the 496 kidney donor candidates 273 were men and 223 were women. The age range of donor candidates was between 20-85, and the mean age was 46.25±13.2. 278 of the healthy individuals who applied to the ethics committee became donor candidates, and 218 were eliminated. Among the 218 candidates eliminated, 22 could not become donors due to the findings detected in MDCTA. The most common MDCTA finding that prevented transplantation was bilateral kidney stones.

**Conclusion:** Before a renal transplant, it is very important to evaluate intra-abdominal renal and extrarenal pathologies that may prevent transplantation. Renal MDCTA provides a minimally invasive, rapid, and accurate evaluation of living kidney donors. For this reason, MDCTA is an imaging method that is increasingly used in the evaluation before renal transplantation.

**Keywords:** Donor nephrectomy, multi-detector computed tomography angiography, renal transplantation

### Öz

**Amaç:** Böbrek donör adayı olarak başvuran kişilere uygulanan Multidedektörlü Bilgisayarlı Tomografi Anjiyografi (MDBTA) incelemesinde; kişinin donör olmasını engelleyebilecek veya cerrahi yaklaşımın değişmesine neden olabilecek renal ve ekstra renal bulgularımızı bildirmeyi amaçlamaktayız. Nakil öncesi donör değerlendirme için yapılan MDBTA incelemesinin ve sonuçlarının transplantasyon planlaması üzerindeki etkisinin altını çizmeyi hedeflemekteyiz.

**Yöntem:** Çalışmamızda Ocak 2017 ile Kasım 2022 tarihleri arasında 496 böbrek verici adayına uygulanan renal MDBTA tetkiki retrospektif olarak değerlendirildi. Her iki böbreğin boyutu ve parankim kalınlığı ölçüldü. Her iki taraf renal arter ve venin çapı, sayıları, varyasyonları, anomalileri tespit edildi. Renal ve diğer batin içi patolojiler belirlendi. Tüm bu değerlendirmelerin sonucunda böbrek nakline engel olan bulgular saptandı. Böbrek nakli için donör adaylarının preoperatif değerlendirilmesinde MDBTA bulguları ve bu bulguların cerrahi yaklaşımı ne oranda etkilediği belirlendi.

**Bulgular:** 496 böbrek verici adayının 273'ü erkek, 223'ü kadın idi. Verici adaylarının yaş aralığı 20-85 arasındaydı, yaş ortalaması ise 46,25±13,2 idi. 278 tanesi donör adayı olmuş, 218 aday çeşitli nedenler ile elenmiştir. Bunların 22 tanesi MDBTA'de tespit edilen bulgulara bağlı olarak donör olamamıştır. Nakile engel olan en sık MDBTA bulgusu ise bilateral böbrek taşı idi.

**Sonuç:** Renal transplant öncesi nakile engel olacak batin içi renal ve ekstrarenal patolojilerin değerlendirilmesi oldukça önemlidir. Renal MDBTA; canlı böbrek donörlerinin minimal invaziv, hızlı ve doğru bir şekilde değerlendirilmesini sağlar. Bu nedenle MDBTA renal transplantasyon öncesi değerlendirmede kullanımı gittikçe yaygınlaşan bir görüntüleme yöntemidir.

**Anahtar Kelimeler:** Donör nefrektomi, multi-dedektör bilgisayarlı tomografi anjiyografi, renal transplantasyon

\*Corresponding author/İletişim kurulacak yazar: Kagan Gokce; Icmeler Mahallesi, Aydinli Yolu Caddesi, Okan Üniversitesi Tıp Fakültesi Arastirma ve Uygulama Hastanesi, Genel Cerrahi Anabilim Dalı, No: 2, 34947 Tuzla-Istanbul, Türkiye.

Phone/Telefon: +90 (532) 581 05 90 e-mail/e-posta: kagangokce2023@gmail.com

Submitted/Başvuru: 31.12.2023

Accepted/Kabul: 14.02.2024

Published Online/Online Yayın: 29.02.2024

## Introduction

The gold standard treatment for end-stage renal failure is kidney transplantation.<sup>1</sup> It can be performed from a deceased human source or a living donor. Graft survival in renal transplantation from a living donor is higher than in transplantation from a deceased person. Since organ donations from deceased humans are scarce in our country, kidney transplants from living donors have tended to increase in recent years.<sup>2</sup> The presence of active infection, incurable malignant diseases, alcohol and drug addiction are absolute contraindications for kidney transplantation. Kidney transplantation can be done in people over the age of 60, but transplantation in patients over the age of 70 is a matter of debate.<sup>3</sup> Radiological imaging plays an important role in the evaluation of living donor candidates before kidney transplantation. Conventional renal angiography has been used to date in the anatomical evaluation of renal arteries. Intravenous Pyelography (IVP) has been used for many years to evaluate the renal parenchyma and collect urinary system.<sup>4</sup> Conventional angiography is an invasive procedure. However, it also carries risks of complications and side effects due to invasive intervention and high-dose contrast material use. As a result of technological developments in Computed Tomography (CT), the Renal Multidetector Computed Tomography Angiography (MDCTA) technique has been developed. Renal MDCTA imaging has replaced invasive angiography and IVP in pre-transplant donor evaluation.<sup>5-6</sup> With four-phase multiplanar MDCTA, the anatomy, vascular and nonvascular pathologies, and anomalies of both kidneys can be detected. In addition, extrarenal and other intra-abdominal pathologies can be easily distinguished. MDCTA provides guidance in surgical planning before donor nephrectomy surgery and significantly reduces the risk of surgical complications. Due to the absence of ionizing radiation, Magnetic Resonance (MRI) imaging can give insight into the anatomy and vascular structure of the kidneys. In the literature, studies comparing non-contrast MR Angiography (MRA) and renal MDCTA have found high diagnostic accuracy rates of MRA examination in showing vascular anatomy.<sup>7-9</sup>

However, due to its inability to rule out possible urinary system stones and the higher number of respiratory artifacts compared to MDCTA, it is not preferred in imaging before kidney transplantation unless necessary.<sup>10</sup>

In kidney transplants from living donors where nephrectomy is planned, full consent of the donor must be obtained and potential risks must be explained to the donor candidate. In addition, absolute contraindications that may prevent the donor from becoming a donor should be excluded.<sup>11</sup> After these conditions are met, the purpose of preoperative evaluation of the living donor is to evaluate the anatomy of the donor's kidneys and measure their size and parenchymal thickness. The presence of any mass lesion in the kidneys or the presence of stones in the urinary system is investigated. It is aimed to evaluate the arteries and veins of both

kidneys, to investigate collecting system anomalies, and to determine whether there are variations related to these anatomical structures. Findings identified by renal MDCTA performed in appropriate phases are highly visualized.<sup>12</sup>

In this study, we aimed to determine the frequency of renal and extrarenal pathologies detected by renal MDCTA before transplantation and to what extent these pathologies affect the person's ability to become a donor and the surgical approach.

## Methods

A total of 496 cases who applied to our hospital as kidney transplant donor candidates and underwent MDBTA examination between January 2017 and November 2022 were retrospectively screened. Demographic data of the cases were obtained from the hospital's electronic record system. Examinations were obtained on 64-slice CT (Optima CT 660, General Electric Medical Systems, Milwaukee, Wisconsin, USA). Water-soluble non-ionic intravenous (i.v.) contrast substance (350 mg/ml) was administered with an automatic double-injector system at a dose of 1 ml/kg at a speed of 4-5 ml/s through an 18-gauge cannula placed in the antecubital vein. Bolus monitoring technique and i.v. contrast substance scheduling was made. Thin-section axial images of the abdomen were taken, starting from the celiac artery origin of the suprarenal aorta to the distal part of both common iliac arteries. Two- and three-dimensional images were created from these images using Maximum Intensity Projection (MIP) and Volume Rendering Technique (VRT). Renal MDCTA examination was performed in four phases.

The first phase (non-contrast phase) is a thin-section multiplanar examination aimed at evaluating kidney dimensions, parenchymal thickness and structure, presence of stones, and possible additional pathologies. Craniocaudal and transverse dimensions and parenchymal thicknesses of both kidneys were measured on sagittal images of this phase.

The second phase (arterial or corticomedullary phase) visualizes the abdominal aorta and its branches in three dimensions throughout the entire course of the renal arteries, starting from the aortic ostium, within 25-30 seconds after contrast substance administration. This phase is used to detect possible renal artery anomalies and their variations and to evaluate renal parenchymal contrast enhancement. Renal artery diameters were measured using axial MIP sections of this phase. Branching of the renal arteries 2 centimeters (cm) from the orifice; considered early branching. In the presence of more than one renal artery that was separated from the aorta by a separate orifice and extended to the kidney, the larger diameter was called the main renal artery and the others were called accessory renal arteries. The accessory renal artery originates from the aorta; If it enters the hilus, it is called accessory hilar artery, if it enters the upper pole, it is called upper polar

artery, and if it enters the lower pole, it is called lower polar artery.

The third phase (venous-nephrographic phase) was used to evaluate the renal veins and other abdominal structures 65-75 seconds after the administration of the contrast substance. If there is more than one renal vein on both sides; This condition has been defined as an accessory renal vein. Anatomical course anomalies of the left renal vein by its position relative to the aorta; They were evaluated and named as preaortic, retroaortic, and circumaortic.

The fourth phase (late phase-pyelographic phase) was used to evaluate the collecting system and filtering functions of the kidneys 5-10 minutes after contrast substance administration.

MDCTA images were examined and evaluated in detail by a single radiologist (D.D.) experienced in abdominal radiology. Average craniocaudal and transverse dimensions and parenchymal thickness of bilateral kidneys were measured. The diameter, number, and anomalies of both renal arteries and veins were determined. Urinary and other intra-abdominal pathologies were identified within the abdominal sections.

### Statistical Analysis

SPSS 22.0 (SPSS for Windows, 2007, Chicago, US) was used for statistical analysis. Continuous variables with normal distribution are presented as mean±standard deviation. Statistical analysis for parametric variables was performed with Student's t-test. Qualitative variables were given as percentages and the correlation between categorical variables was investigated with the Chi-square test and Fisher's exact test. The statistical significance level was defined as  $p < 0.05$ .

### Results

The renal MDBTA examination, which was registered in our hospital's Picture Archiving and Communication System (PACS) and performed on 496 kidney donor candidates between January 2017 and November 2022, was evaluated retrospectively by a single radiologist (D.D.). 273 of the cases were male (55%) and 223 were female (45%). The age range was 20-85, the overall average age was  $46.25 \pm 13.2$ . The average age by gender was  $48.36 \pm 12.72$  for females and  $44.53 \pm 13.35$  for males ( $p = 0.01$ ).

The mean craniocaudal length of the right kidney was  $105.73 \pm 10.218$  millimeters (mm) in females and  $108.31 \pm 9.163$  mm in males ( $p = 0.003$ ). The average right kidney transverse length was  $46.06 \pm 5.318$  mm in females and  $48.07 \pm 5.73$  mm in males ( $p < 0.01$ ). The average parenchymal thickness of the right kidney was  $16.95 \pm 2.634$  mm in females and  $17.63 \pm 2.766$  mm in males ( $p = 0.005$ ), the average craniocaudal length of the left kidney was  $105.76 \pm 10.415$  mm in females and  $111.10 \pm 9.712$  mm in males ( $p < 0.01$ ). The average left kidney transverse length was  $45.69 \pm 5.337$  mm in females

and  $48.63 \pm 6.080$  mm in males ( $p < 0.01$ ), the average left kidney parenchymal thickness was  $17.07 \pm 2.516$  mm in females and  $17.73 \pm 2.586$  mm in males ( $p < 0.01$ ) (Table 1). The mean diameter of the right renal artery was  $5.80 \pm 1.076$  mm in females and  $6.13 \pm 1.323$  mm in males ( $p = 0.003$ ). The mean diameter of the right renal vein was  $9.70 \pm 2.105$  mm in females and  $9.90 \pm 2.227$  mm in males ( $p = 0.329$ ). The mean diameter of the left renal artery was  $6.01 \pm 0.96$  mm in females and  $6.38 \pm 1.323$  mm in males ( $p < 0.001$ ). The mean diameter of the left renal vein was  $8.43 \pm 2.401$  mm in females, and  $8.67 \pm 2.577$  mm in males ( $p = 0.297$ ) (Table 2).

Right renal artery variation was detected in 40 females (17.9%) and 64 males (23.4%) ( $p = 0.134$ ). Lower polar artery variation was detected in 5 of the female donor candidates, an upper polar artery in 16, an accessory hilar artery in 16, 4 renal artery variations in 2, and 3 renal artery variations in 1 female donor candidate. Lower polar artery variation was detected in 5 male donor candidates, upper polar artery variation in 20, accessory hilar artery variation in 32, 4 renal artery variations in 2, and 3 renal artery variations in 5 male donor candidates. Left renal artery variation was detected in 48 women (21.5%) and 78 men (28.6%) ( $p = 0.073$ ). Upper polar renal artery variations were detected in 13 of the female cases, accessory hilar in 24, lower polar in 8, and 3 renal artery variations in 3 of them. Accessory hilar artery variation was detected in 34 of the male cases, an upper polar artery in 22, a lower polar artery in 17, 3 renal artery variations in 3, and 4 renal artery variations in 2 male donor candidates.

Early branching variation was detected in 35 (15.7%) of females and 42 (15.4%) of males.

Right renal vein variation was detected in 21 females (9.4%) and 41 men (15%) ( $p = 0.061$ ). In females, 1 ovarian vein draining into the right renal vein, 1 with 3 renal vein variations, and 19 with double renal vein variations were detected. 35 of the males had double renal veins, 3 had 3 renal veins, 1 had a renal vein flowing into the iliac vein, 1 had 4 renal veins, and 1 had double inferior vena cava and accompanying double renal vein variation.

Left renal vein variation was detected in 24 females (10.8%) and 37 males (13.6%) ( $p = 0.346$ ). Lumbar vein draining into the renal vein in 8 of the female cases, retroaortic left renal vein in 7, double renal vein variation and accompanying lumbar vein anomaly draining into the left renal vein in 1, and compression of the left renal vein between the Superior Mesenteric Artery (SMA) and Aorta (Nutcracker Syndrome) in 4, double renal vein and ovarian vein variation flowing into the left renal vein were detected in 1 patient, double renal vein one of which had a retroaortic course, and double renal vein variation was detected in 2 patients. Double renal vein was detected in 11 of the male cases, retroaortic left renal vein in 12, lumbar vein variation flowing into the renal vein in 10, and compression of the left renal vein between SMA and Aorta (Nutcracker Syndrome) variation in 4.

Right kidney pathology was detected in 35 (15.7%) of female kidney donor candidates and 54 (19.8%) of male

kidney donor candidates (p=0.238). Kidney stones were detected in 13 of the female cases, kidney cysts in 18 females, a cyst in one kidney and angiomyolipoma in the other kidney in 1 female, kidney stones and angiomyolipoma in 1 female, rotation anomaly in 1 female, and only angiomyolipoma in 1 female. Of the

male cases, 20 had kidney stones, 26 had kidney cysts, and 5 had kidney cysts and stones together. A Horseshoe kidney was detected in 1 male, a distal ureter stone was detected in 1 and angiomyolipoma was detected in 1 male.

**Table 1.** Mean age by gender, mean dimensions and mean parenchymal thickness of both kidneys

Table 1	Female	Male	p
Mean Age	48.36±12.722	44.53±13.358	=0.001
Right kidney craniocaudal dimension	105.73±10.218 mm	108.31±9.163 mm	=0.003
Right kidney transverse dimension	46.06±5.318 mm	48.07±5.730 mm	<0.001
Right kidney parenchymal thickness	16.95±2.634 mm	17.63±2.766 mm	=0.005
Left kidney craniocaudal dimension	105.76±10.415 mm	111.10±9.712 mm	<0.001
Left kidney transverse dimension	45.69±5.337 mm	48.63±6.080 mm	<0.001
Left kidney parenchymal thickness	17.07±2.516 mm	17.73±2.586 mm	=0.005

**Table 2.** Mean diameter of bilateral renal arteries and veins by gender

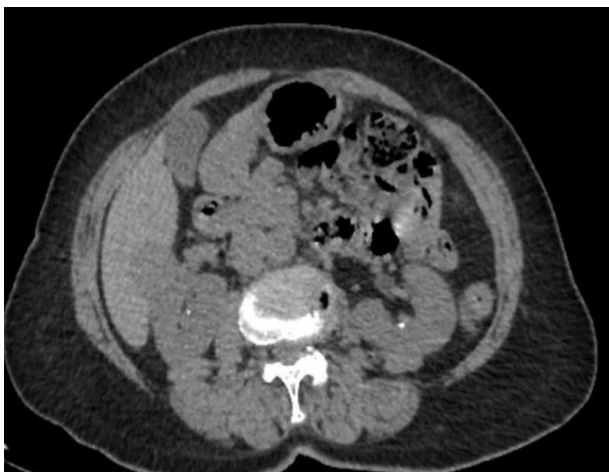Table 2	Female	Male	p
Mean diameter of right renal artery	5.80±1.076 mm	6.13±1.323 mm	=0.003
Mean diameter of right renal vein	9.70±2.105 mm	9.90±2.227 mm	=0.329
Mean diameter of left renal artery	6.01±0.964 mm	6.38±1.323 mm	<0.001
Mean diameter of left renal vein	8.43 ±2.401 mm	8.67 ±2.577 mm	=0.297

Left kidney pathology was detected in 34 females (15.2%) and 55 males (20.1%) (p=0.157). Kidney stones were detected in 12 of the female kidney donor candidates, kidney cysts in 17, kidney stones and accompanying cysts in 4, and angiomyolipoma in 1. Kidney stones were detected in 14 of the male kidney donor candidates, kidney cysts in 34, kidney stones and cysts in 6, microcalculi, and an accompanying solid lesion in 1 male. Collecting system pathology was detected in 9 females (4%) and 12 males (4.4%) (p=0.843). Bilateral pelvicalyceal ectasia was detected in 3 of the female cases, bilateral extrarenal pelvis variation in 2, unilateral pelvicalyceal ectasia in 3, and bilateral dilated extrarenal pelvis variation in 1. 3 of the male cases had unilateral pelvicalyceal ectasia, 2 had bilateral pelvicalyceal ectasia, 2 had bilateral extrarenal pelvis variation, 1 had bilateral extrarenal pelvis and accompanying pelvicalyceal ectasia, 1 had a double collecting system on the left, 1 had an ectopic pelvic kidney variation on the left and 1 had double left pelvic kidney variation. Collecting system and accompanying pelvicalyceal ectasia were detected on the right side and ureteropelvic stenosis variation was detected on the left in 1 of the male cases. Other intra-abdominal additional pathologies were detected in 92 (41.3%) of females and 93 (34.1%) of males (p=0.1). Hepatosteatosi in 33 of the female cases, hepatosteatosi and accompanying hepatomegaly in 6, umbilical hernia in 15, liver cyst in 7, liver hemangioma in 5, splenomegaly in 4, cholelithiasis in 3, adrenal adenoma in 2, adrenal lipoma in 1, mesenteric panniculiti in 4. appearance 1 with a giant mass originating from the uterus, 1 with a uterine myoma, 2 with an ovarian cyst, 1

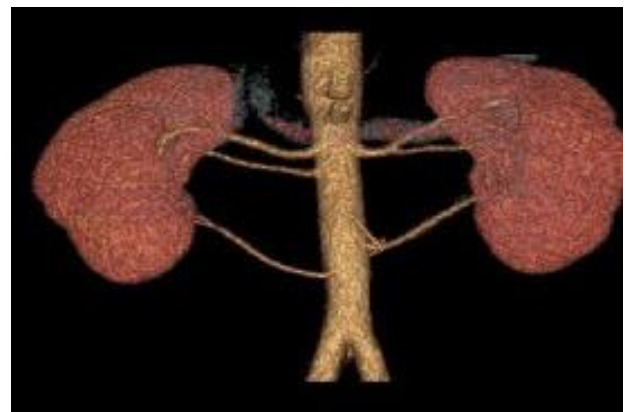
with hepatosteatosi and accompanying hemangioma, 2 with hepatosteatosi and accompanying adrenal adenoma, 2 with hepatosteatosi and splenomegaly, 2 with adrenal adenoma and cholelithiasis, in another one hemangioma, hepatosteatosi and cholelithiasis were detected in the liver. Among the male cases, 45 had hepatosteatosi, 10 had hepatosteatosi and accompanying hepatomegaly, 3 had umbilical hernia, 1 had umbilical hernia and associated bladder stones, 1 had umbilical hernia and associated hepatosteatosi, 9 had liver cysts, 3 had liver cysts associated with gallbladder stones, hepatosteatosi and hepatomegaly in 2, cholelithiasis in 7, hepatosteatosi and accompanying liver hemangioma in 2, hepatosteatosi and accompanying adrenal adenoma in 5, mesenteric panniculiti in 2, splenomegaly in 2 and Ankylosing Spondyliti findings in the bone structures in 1 (Table 3). Of the 496 kidney donor candidates in the study, 278 were able to become donors. 218 candidates were eliminated for various reasons. According to MDCTA findings, the number of patients eliminated was 22, and 15 of them had bilateral kidney stones (Figure 1). One of them had left nephrolithiasis and accompanying proteinuria, one had 3 bilateral renal arteries (Figure 2), one had bilateral fine-calibrated double renal arteries and veins, and one had 3 renal arteries on the right and double renal arteries on the left and early branching variation (Figure 3). One case was eliminated because of multiple kidney cysts, one had a right kidney stone and a double retroaortic renal vein on the left, and one had a gynecological tumor (Figure 4).

**Table 3.** The incidence of renal artery and vein variations, renal pathologies, collecting system pathologies, and other intra-abdominal pathologies according to gender

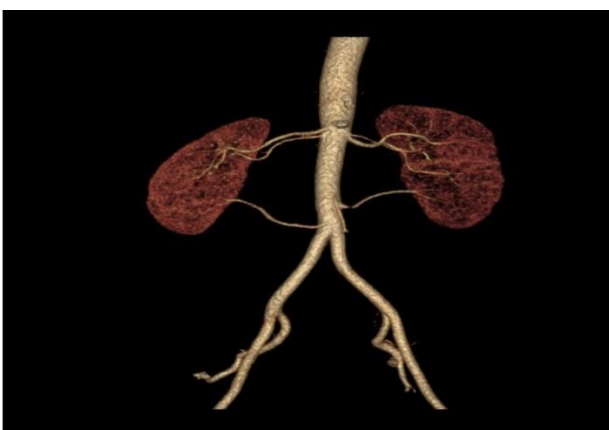
		Female	Male	p
Right renal artery variation	Negative	183(82.1%)	209(76.6%)	=0.134
	Positive	40(17.9%)	64(23.4%)	
Left renal artery variation	Negative	175(78.5%)	195(71.4%)	=0.073
	Positive	48(21.5%)	78(28.6%)	
Right renal vein variation	Negative	202(90.6%)	232(85%)	=0.061
	Positive	21(9.4%)	41(15%)	
Left renal vein variation	Negative	199(89.2%)	236(86.4%)	=0.346
	Positive	24(10.8%)	37(13.6%)	
Right kidney pathology	Negative	188(84.3%)	219(80.2%)	=0.238
	Positive	35(15.7%)	54(19.8%)	
Left kidney pathology	Negative	189(84.8%)	218(79.9%)	=0.157
	Positive	34(15.2%)	55(20.1%)	
Collecting system pathology	Negative	214(96%)	261(95.6%)	=0.843
	Positive	9(4%)	12(4.4%)	
Additional intra-abdominal pathology	Negative	131(58.7%)	180(65.9%)	=0.1
	Positive	92(41.3%)	93(34.1%)	
Total		223(100%)	273(100%)	



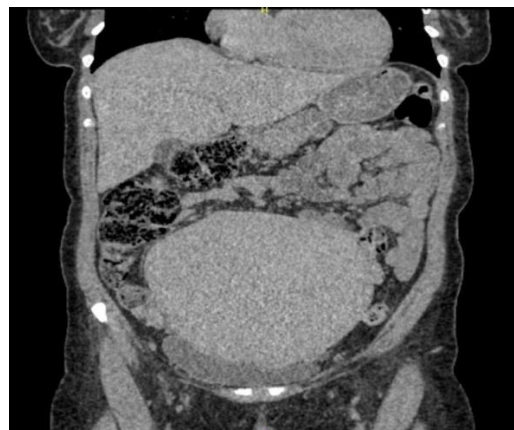
**Figure 1.** Bilateral kidney stones (blue arrows) in non-contrast axial MDCTA examination



**Figure 3.** Three-dimensional Volume Rendered Technique (VRT) imaging shows 3 renal arteries on the right and double renal arteries on the left, with variation and early branching



**Figure 2.** In the three-dimensional Volume Rendered Technique (VRT) review; bilateral three renal artery variations



**Figure 4.** Giant mass thought to originate from the uterus (white arrow) on coronal non-contrast CT scan

Other reasons for exclusion in the evaluation of donor nephrectomy are the kidney recipient being found to be at immunological risk, the kidney recipient being found to be at cardiovascular risk, other diseases detected in

the recipient, blood group incompatibility, detection of proteinuria, hypertension, diabetes, malignancy, cardiovascular diseases in the donor candidate, the ethics committee not approving transplantation, and the donor candidate gives up on transplantation. In a total of 203 kidney transplant operations performed without complications, left laparoscopic donor nephrectomy was performed, and in the other 75 operations, laparoscopic right donor nephrectomy was performed. When choosing the side of the surgeries; MDBTA review results played an important role in the decision-making process.

## Discussion

In patients whose chronic renal failure has become irreversible, when the glomerular filtration rate drops below 15 milliliters/minute/1.73 square meters, these patients are evaluated for dialysis and kidney transplantation. The transplant success rate is higher in patients who have the chance to undergo transplantation without dialysis.<sup>13-14</sup> Laparoscopic donor nephrectomy from a living donor was first performed by Ratner in 1995 and subsequently became widespread rapidly. This practice has started to be implemented in our country since the year 2000.<sup>15-16</sup> Nowadays, with the increasing success of immunosuppressive treatment, graft survival rates are over 90% thanks to technical developments such as laparoscopic surgery. Kidney transplantation is the gold standard treatment for kidney failure. Since organ donations from deceased persons are low, kidney transplantation from living donors is more prominent in some countries like ours.<sup>17</sup> During donor nephrectomy, the donor should be protected as much as possible and the risks of mortality and morbidity should be reduced. Studies have shown that the Laparoscopic Donor Nephrectomy (LDN) procedure takes longer than the open operation, and has a longer warm ischemia time, but has similar results in terms of perioperative complications and long-term complications.<sup>18-19</sup> Therefore, LDN is the most commonly performed surgical method today.<sup>20</sup>

Having knowledge about renal anatomy and vascular structure in the preoperative period is guiding in terms of surgical planning. In particular, examining the vascular structures of both kidneys of donor candidates is decisive in determining which side of the kidney will be selected for nephrectomy. In addition, it greatly reduces the risk of complications that may occur during dissection during donor nephrectomy surgery.<sup>21</sup>

Renal MDCTA, performed in four phases with appropriate technique, is the most common imaging method used for this purpose today. First of all, in the thin-section imaging performed in the non-contrast phase, the localization of both kidneys, their dimensions, and parenchymal thickness are measured, and lesions such as stones and crystalloids, if any, can be distinguished. Renal vascular anatomy is evaluated in detail in the arterial and venous phases. In particular, the presence of more than one renal artery and vein, the presence of accessory and renal polar arteries, and the

presence, of course, anomalies of the renal vein such as retroaortic, circumaortic, and left renal vein opening into the lumbar vein are displayed. Renal cysts, the most common kidney mass, appear as homogeneous hypodense lesions with smooth contours that do not enhance contrast in the arterial and venous phases and can be easily distinguished from mass lesions such as angiomyolipoma, oncocytoma, and renal cell carcinoma. In the late phase; It can be evaluated whether there are anomalies in the collecting system such as ureteropelvic stenosis and ureteral dilatation. Evaluating all the findings together provides guidance on which side, right or left, will be chosen for donor nephrectomy.<sup>22</sup>

If there is more than a 2 cm difference between kidney sizes on imaging, it should be considered that there may be a significant difference in glomerular filtration rates. Radioisotope renography (Tc99m-MAG3) can be performed when necessary to evaluate the function of both kidneys. If a difference of 10% or more is detected between kidney functions, the kidney with lower function can be planned to be removed, but this usually prevents acceptance as a donor.<sup>23-24</sup>

Preoperative evaluation of vascular anatomy is extremely important. The presence of multiple renal arteries and veins does not constitute a contraindication for donor nephrectomy. However, preoperative knowledge of these vascular variations is very important in preventing possible complications. In approximately 25% of cases, more than one vessel is seen in one kidney, and in 7% of cases, more than one vessel is seen in both kidneys. If there is no other obstacle, the removal of a kidney with a single artery and a single vein should be preferred to minimize the risk of complications. Due to the length of the vein, the preference for donor nephrectomy is the left kidney. Due to the short vein in the right kidney, mechanical complications such as renal vein thrombosis are more common.<sup>23,25</sup>

Preoperative evaluation should also be performed carefully in the presence of kidney stones. If stones are detected in both kidneys, the person cannot be a candidate for donor nephrectomy. However, non-symptomatic stones under 1.5 cm in diameter in a single kidney are not an obstacle for donor nephrectomy. Planning should be done so that the kidney without stones remains in the donor.<sup>26-27</sup>

Simple cystic structures of the kidney detected in preoperative evaluation do not prevent becoming a donor. Kidney transplantation can be performed with cystic structure. Again, while benign masses such as angiomyolipoma under 4 cm do not prevent donation, mass lesions in the kidney over 4 cm are generally not suitable for donor nephrectomy. However, donor nephrectomy may be considered if there is a mass that can be removed ex-vivo.<sup>10,17</sup> Kidney transplantation may be a possibility if ex-vivo partial nephrectomy can be performed in incidentally detected early-stage renal cell cancers.<sup>11,22</sup>

Both renal arteries originate from the aorta just after the superior mesenteric artery at the level of L1-L3 vertebrae. In most cases, there is a single renal artery

bilaterally. It is approximately 4-6 cm long and 5-6 mm in diameter. Depending on the location of the renal hilus, they show a lateral and posterior course and enter the hilus from the posterior of the renal vein. The right renal artery originates from the anterolateral aspect of the aorta, while the left renal artery originates from the aorta more superior to the right.<sup>28</sup> Transient mesonephritic arteries that develop during the embryological period and do not disappear afterward cause renal artery variations. Renal artery variations are named accessory, hilar, upper polar, lower polar, aberrant, and early branching according to their number, origin, branching pattern, and entry into the kidney. These variational conditions in the renal arteries often do not cause clinical findings. It is detected incidentally in radiological imaging. However, sometimes thin and tortuous accessory renal arteries can cause perfusion disorders in the kidney and resistant hypertension. If the inferior polar artery causes compression as it courses in front of the ureteropelvic junction, hydronephrosis may occur. Accessory renal arteries may be injured during renal biopsy or kidney surgery, and conditions such as bleeding and ischemia necrosis may occur. Evaluating the donor's vascular structure, especially before renal transplant, is very important in this respect.<sup>29</sup> In the donor nephrectomy operation, the renal artery incision should be made 1.5-2 cm distal to the aortic origin to control bleeding easily and to make the anastomosis suitable for the recipient. Therefore, it is very important to identify any possible premature branching of the main renal artery preoperatively.<sup>30</sup>

Renal vein anomalies and variations are much less common than renal arteries. Multiple renal veins are the most common renal vein variation, they are more common in the right kidney and are between 15-30% of the whole population.<sup>31</sup> Each kidney usually has one renal vein, which drains into the inferior vena cava. The right renal vein is shorter than the left. Therefore, the left kidney is usually chosen. At the entrance location to the Inferior Vena Cava (IVC), the average diameter of the left renal vein is 12.3±1.41 mm, while the right renal vein is 10.9±1.56 mm wide. Multiple renal veins bilaterally, circumaortic, or retroaortic renal vein on the left may be seen. The left renal vein normally passes in front of the aorta and flows into the IVC. If the left renal vein passes posterior to the aorta and flows into the inferior vena cava, it is called a retroaortic course. If it divides into branches passing in front and behind the aorta and extends to the inferior vena cava, it is called the circumaortic renal vein. These variations do not pose an obstacle to LDN. However, the risk of thrombosis of the retroaortic left renal vein is high and it is important to know it in the preoperative period as there is a risk of injury during surgery.<sup>32</sup> The circumaortic left renal vein becomes compressed between the aorta and SMA, or the retroaortic left renal vein becomes compressed between the aorta and the vertebral body, causing the Nutcracker Phenomenon. Increased pressure in the left renal vein causes rupture in the thin-walled renal veins, which may cause clinical findings such as hematuria, orthostatic

proteinuria, and increased pressure in the gonadal veins may cause clinical findings such as pelvic congestion, left varicocele, and flank pain.<sup>33</sup> Urinary system anomalies and collecting system anomalies may be asymptomatic or may lead to renal failure.<sup>34</sup> In the pyelographic phase, which is the late phase; the renal pelvis, calyces, and ureter anatomy are evaluated and anomalies such as hydronephrosis, ureteropelvic stenosis, and double collecting system are detected.<sup>35</sup> It is possible to detect renal artery and vein variations accurately and quickly with renal MDCTA. At the same time, MDCTA provides information about renal function, urinary system variations and pathologies, and other intra-abdominal pathologies.<sup>36-38</sup> Renal MDCTA performed with appropriate technique; is superior to other radiological modalities in the evaluation of living kidney donors.<sup>39</sup> With a single radiographic imaging, renal vascular and nonvascular anatomy, and other intra-abdominal organs can be evaluated quickly and accurately. For this reason, it is an imaging method that is increasingly used routinely.<sup>40</sup>

### Conclusion

MDCTA can be applied as radiological imaging alone to determine suitable candidates before donor nephrectomy operation and to predict the vascular variants that will be encountered perioperatively. Knowing the vascular variants before surgery is important data on which kidney will be received as a donor. Technically, taking the left kidney as a donor is more suitable from a surgical perspective. Although vascular variations are more prevalent on the right side, detailed information can be obtained with MDCTA and this information may enable the selection of the right side in donor nephrectomy operation. MDCTA alone is an ideal radiological examination modality that can be used safely before donor nephrectomy surgery, as it provides detailed information about renal parenchyma and size, collecting urinary system and other intra-abdominal pathologies, as well as vascular and urinary variations.

### Compliance with Ethical Standards

The study was performed after obtaining the necessary ethics committee permission and institutional approval were received from Istanbul Okan University Non-Invasive Clinical Research Ethics Committee at the meeting numbered 169 on 18/10/2023 with decision number 14.

### Conflict of Interest

The authors declared no conflicts of interest with respect to the authorship and/or publication of this article.

### Author Contribution

All authors contributed equally to the article.

### Financial Disclosure

The authors received no financial support for the research and/or authorship of this article.

## References

1. Roi GS, Mosconi G, Totti V, et al. Renal function and physical fitness after 12-mo supervised training in kidney transplant recipients. *World Journal of Transplantation*. 2018;8(1):13-22. doi:10.5500/wjt.v8.i1.13
2. Atlı E, Kılınçer A, Uyanık S, et al. Renal computed tomography angiography protocol and radiation dose in kidney transplant donors. *Kocatepe Medical Journal*. 2021;22(5):321-325. doi:10.18229/kocatepetip.786155
3. Melandro F, Del Turco S, Ghinolfi D. Age disparities in transplantation. *Current Opinion in Organ Transplantation*. 2021;26(5):536-541. doi:10.1097/mot.0000000000000906
4. Kaynan AM, Rozenblit AM, Figueroa KI, et al. Use of spiral computerized tomography in lieu of angiography for preoperative assessment of living renal donors. *The Journal of Urology*. 1999;1769-1775. doi:10.1097/00005392-199906000-00006
5. Pozniak MA, Lee FT. (1999) 'Computed tomographic angiography in the preoperative evaluation of potential renal transplant donors. *Current Opinion in Urology*. 1999;9(2):165-170. doi:10.1097/00042307-199903000-00011
6. Alfrey EJ, Rubin GD, Kuo PC, et al. The use of spiral computed tomography in the evaluation of living donors for kidney TRANSPLANTATION1. *Transplantation*. 1995;59(4):643-645. doi:10.1097/00007890-199559040-00037
7. Li X, Xia F, Chen L, Zhang X, Mo C, Shen W. One-stop preoperative assessment of renal vessels for living donors with 3.0 T non-contrast-enhanced magnetic resonance angiography: Compared with computerized tomography angiography and surgical results. *The British Journal of Radiology*. 2021;94(1128). doi:10.1259/bjr.20210589
8. Israel GM, Lee VS, Edey M, et al. Comprehensive MR imaging in the preoperative evaluation of living donor candidates for laparoscopic nephrectomy: Initial experience. *Radiology*. 2002;225(2):427-432. doi:10.1148/radiol.2252011671
9. Gurkan A, Varılsuha C, Eren S, et al. The diagnostic value of the spiral computed tomographic angiography in the evaluation of renal transplant donors. *Klinik ve Deneysel Cerrahi Dergisi*. 2000;8(4):190-193.
10. Gluecker TM, Mayr M, Schwarz J, et al. Comparison of CT angiography with MR Angiography in the preoperative assessment of living kidney donors. *Transplantation*. 2008;86(9):1249-1256. doi:10.1097/tp.0b013e3181890810
11. Garg AX, Levey AS, Kasiske BL, Cheung M, Lentine KL. Application of the 2017 KDIGO guideline for the evaluation and care of living kidney donors to clinical practice. *Clinical Journal of the American Society of Nephrology*. 2020;15(6):896-905. doi:10.2215/cjn.12141019
12. Yiğit B, Berber İ, Kara M, Tellioglu G, Akıncı O, Titz İ. Canlı böbrek vericisinin ameliyat öncesi incelemesinde 3-Boyutlu Spiral Tomografik Anjiyografinin Kullanımı. *Türk Nefroloji ve Transplantasyon Dergisi*. 2007;16(2):77-9.
13. Ersoy FF. Son dönem böbrek yetmezliğinde uygun diyaliz yönteminin seçimi. *Türkiye Klinikleri J Int Med Sci*. 2005;(1):88-92.
14. Ertugrul G. Böbrek nakli yapılan hastaların retrospektif analizi. *Journal of Health Sciences and Medicine*. 2019;2.3:88-91.
15. Ratner LE, Ciseck LJ, Moore RG, Cigarroa FG, Kaufman HS, Kavoussi LR. Laparoscopic live donor nephrectomy. *Transplantation*. 1995;60(9):1047-1049.
16. Sen S, Özkahya M, Hoşçoskun C, Başdemir G. Sıfır saat biyopsilerde saptanan morfolojik bulgular ve erken dönemde greft fonksiyonuna etkisi. *Türk Nefrol Diyaliz Transplant Derg*. 2000;1:30-36.
17. Gürkan A, Kaçar S, Karaca C, Varılsüha C, Karaoğlan M, Başak K. Laparoscopic living donor nephrectomy a nation's first experiences. *Dialysis and Transplantation*. 2004;33(1):22-30.
18. Wilson CH, Sanni A, Rix DA, Soomro NA. Laparoscopic versus open nephrectomy for live kidney donors. *Cochrane Database Syst Rev*. 2011;(11):CD006124. doi:10.1002/14651858.CD006124.pub2
19. Erikoğlu M, Küçükartallar T, Çolak B, Tekin A. Laparoskopik Donör Nefrektomi: Erken Dönem Sonuçlarımız. *Endoskopik Laparoskopik & Minimal İnvaziv Cerrahi Dergisi*. 2011;18(4).
20. Gürkan A, Kaçar S, Başak K, Varılsüha C, Karaca C. Do Multiple renal arteries restrict laparoscopic donor nephrectomy? *Transplant Proc*. 2004;36(9):105-107.
21. Arer İ, Yabanoğlu H, Çalışkan K, ve ark. Böbrek Transplantasyon Donörlerinde Vasküler Farklılıklar ve Anastomoz Teknikleri. *Cukurova Medical Journal*. 2015;40(3):542-546.
22. Ghonge NP, Gadanayak S, Rajakumari V. MDCT evaluation of potential living renal donor, prior to laparoscopic donor nephrectomy: What the transplant surgeon wants to know? *Indian J Radiol Imaging*. 2014;24(4):367-378. doi:10.4103/0971-3026.143899
23. Andrews PA, Burnapp L. British Transplantation Society / Renal Association UK Guidelines for Living Donor Kidney Transplantation 2018: Summary of Updated Guidance. *Transplantation*. 2018;102(7):e307. doi:10.1097/TP.0000000000002253
24. Janki S, Dor FJ, IJermans JN. Surgical aspects of live kidney donation: an updated review. *Front Biosci (Elite Ed)*. 2015;7(2):346-365. doi:10.2741/738
25. Wang K, Zhang P, Xu X, Fan M. Right Versus Left Laparoscopic Living-Donor Nephrectomy: A Meta-Analysis. *Exp Clin Transplant*. 2015;13(3):214-226.
26. Tatapudi VS, Goldfarb DS. Differences in national and international guidelines regarding use of kidney stone formers as living kidney donors. *Curr Opin Nephrol Hypertens*. 2019;28(2):140-147. doi:10.1097/MNH.0000000000000480
27. Longo N, Calogero A, Creta M, et al. Outcomes of Renal Stone Surgery Performed Either as Predonation or Ex Vivo Bench Procedure in Renal Grafts from Living Donors: A Systematic Review. *Biomed Res Int*. 2020;2020:6625882. doi:10.1155/2020/6625882
28. Stojadinovic D, Zivanovic-Macuzic I, Szadanovic P, et al. Concomitant multiple anomalies of renal vessels and collecting system. *Folia Morphol (Warsz)*. 2020;79(3):627-633. doi:10.5603/FM.a2019.0108
29. Leslie SW, Sajjad H. Anatomy, Abdomen and Pelvis, Renal Artery. *Europe PMC, StatPearls Publishing LLC*. 2022. PMID:2908326, Bookshelf ID: NBK459158.
30. Tatar I, Töre HG, Çelik H, Karcaaltınbaca M. Retroaortic and circum-aortic left renal veins with their CT findings and review of the literature. *Anatomy*. 2008;2(1):72-76.
31. Çınar C, Türkvatan A. Prevalence of renal vascular variations: Evaluation with MDCT angiography. *Diagn Interv Imaging*. 2016;97(9):891-897. doi:10.1016/j.diii.2016.04.001



32. Abrams HL. Renal venography. In: Abrams HL (ed) Abrams angiography, 2nd ed. *Little Brown, Boston*.1983;1327-1364.
33. Aslan A, Barutca H, Kocaaslan C, Orman S, Şahin S. Pulsatile Mass Sensation with Intense Abdominal Pain; Atypical Presentation of the Nutcracker Syndrome. *Pol J Radiol*. 2016;28;(81):507-509. doi: 10.12659/PJR.898166
34. Ramanathan S, Kumar D, Khanna M, et al. Multi-modality imaging review of congenital abnormalities of kidney and upper urinary tract. *World J Radiol*. 2016;8(2):132-141. doi:10.4329/wjr.v8.i2.132
35. Turkvatan A, Olçer T, Cumhuri T. Multidetector CT urography of renal fusion anomalies. *Diagn Interv Radiol*. 2009;15(2):127-134.
36. Tombul ST, Aki FT, Gunay M, et al. Preoperative evaluation of hilar vessel anatomy with 3-D computerized tomography in living kidney donors. *Transplant Proc*. 2008;40(1):47-49. doi:10.1016/j.transproceed.2007.11.045
37. Hänninen EL, Denecke T, Stelter L, et al. Preoperative evaluation of living kidney donors using multirow detector computed tomography: comparison with digital subtraction angiography and intraoperative findings. *Transpl Int*. 2005;18(10):1134-1141. doi:10.1111/j.1432-2277.2005.00196.x
38. Öner S, Öner Z. Arteria Renalis Varyasyonları: Bir Multidetektör BT Anjiyografi Çalışması. *Kafkas J Med Sci*. 2019; 9(1):1-5.
39. Arvin-Berod A, Bricault I, Terrier N, et al. Évaluation préopératoire du nombre de vaisseaux chez le donneur de rein vivant. La TDM est-elle supérieure à l'IRM? [Preoperative assessment of renal vascular anatomy for donor nephrectomy: Is CT superior to MRI?]. *Prog Urol*. 2011;21(1):34-39. doi10.1016/j.purol.2010.05.013
40. Namasivayam S, Kalra MK, Small WC, Torres WE, Mittal PK. Multidetector row computed tomography evaluation of potential living laparoscopic renal donors: the story so far. *Curr Probl Diagn Radiol*. 2006;35(3):102-114. doi:10.1067/j.cpradiol.2006.02.005