

# Descemet membrane endothelial keratoplasty and penetrating keratoplasty in pseudophakic bullous keratopathy: comparison of visual outcomes, graft survival rates, and complications

Ayşe Tüfekçi Balıkcı<sup>1</sup>, Nurşah Demir<sup>1</sup>, Ayşe Burcu<sup>1</sup>, Züleyha Yalnız Akkaya<sup>1</sup>, Evin Şingar<sup>1</sup>, Selma Uzman<sup>1</sup>

Department of Ophthalmology, University of Health Sciences Turkey, Ankara Training and Research Hospital, Ankara, Türkiye

## ABSTRACT

**Objectives:** To compare the outcomes of Descemet Membrane Endothelial Keratoplasty (DMEK) and Penetrating Keratoplasty (PK) in patients with pseudophakic bullous keratopathy (PBK).

**Methods:** Records of 51 eyes of 51 PBK patients (32 male, 19 female) who underwent PK (Group 1=38 eyes) and DMEK (Group 2=13 eyes) were reviewed retrospectively. The two groups were compared for Best-corrected visual acuity (BCVA), graft survival rates, and complications.

**Results:** The mean age was 69.1 and 67.1 years in group 1 and group 2, respectively. First-year cumulative survival rates for group 1 and group 2 were 92.1% and 61.5%, respectively, and 89.1% and 51.3% in the second year ( $P=0.001$  by log-rank test). At the last follow-up visit, 2.7% of Group 1 and 30.8% of Group 2 had a BCVA of 0.3 or better ( $P=0.004$ ). Graft failure was observed in 12 eyes (31.6%) in group 1 and 8 eyes (61.5%) in group 2 ( $P=0.056$ ). At the last examination, the rates of transparent grafts were 73.7% and 69.2% in group 1 and group 2, respectively ( $P=0.756$ ). Postoperative glaucoma was observed in 4 eyes (30.8%) in the group 2 and 4 eyes (10.5%) in the group 1 ( $P=0.083$ ). There was no significant difference between the two groups regarding other complications ( $P>0.05$ ).

**Conclusions:** DMEK surgery offers a better visual outcome than PK for the treatment of PBK. Careful follow-up of patients is required in terms of glaucoma and graft failure after DMEK. Although the graft survival rate was lower in the DMEK group, a similar rate of graft transparency was achieved at the final examination with repeated DMEK surgery.

**Keywords:** Deep anterior lamellar keratoplasty, descemet membrane endothelial keratoplasty, penetrating keratoplasty, macular corneal dystrophy

Corneal endothelial cells prevent the passage of anterior chamber fluid into the corneal stroma and keep the cornea transparent. When the barrier and pump function of the endothelium is disrupted

and the endothelial cell density falls below the critical threshold due to various reasons such as endothelial dystrophy, surgical trauma, infection, eye trauma, glaucoma, and uveitis, excessive fluid accumulates in

**Corresponding author:** Ayşe Tüfekçi Balıkcı, MD.,  
Phone: +90 312 595 30 00, E-mail: [drtufekciayse@yahoo.com](mailto:drtufekciayse@yahoo.com)

**How to cite this article:** Tüfekçi Balıkcı A, Demir N, Burcu A, Yalnız Akkaya Z, Şingar E, Uzman S. Descemet membrane endothelial keratoplasty and penetrating keratoplasty in pseudophakic bullous keratopathy: comparison of visual outcomes, graft survival rates, and complications. Eur Res J. 2024. doi: 10.18621/eurj.1449647

**Received:** March 26, 2024  
**Accepted:** May 4, 2024  
**Published Online:** May 21, 2024

Copyright © 2024 by Prusa Medical Publishing  
Available at <https://dergipark.org.tr/en/pub/eurj>



This is an open access article distributed under the terms of [Creative Commons Attribution-NonCommercial-NoDerivatives 4.0 International License](https://creativecommons.org/licenses/by-nc-nd/4.0/)

the stroma. As edema increases, the cornea becomes cloudy, and painful bullae form in the epithelium. This condition is called Bullous keratopathy (BK) [1]. Bullous keratopathy is a common cause of corneal decompensation, often requiring corneal transplantation. Intraocular cataract surgery may cause or accelerate endothelial decompensation [2]. Corneal edema may develop after cataract surgery due to defects in the patient's endothelial number or structure or problems caused by surgery. If BK develops despite medical treatment, it is defined as pseudophakic bullous keratopathy (PBK), and surgical treatment is required. While painful and blind corneal tissue was replaced with full-thickness donor cornea until recent years, replacement of only the endothelial layer has now become a more common surgery [3]. However, penetrating keratoplasty (PK) is still used in advanced BK that develop chronic fibrosis or when endothelial keratoplasty (EK) is contraindicated.

Endothelial keratoplasty has advantages over PK, such as preserving the integrity of the eye, reducing risks such as postoperative astigmatism, suture problems, traumatic wound dehiscence, providing faster visual rehabilitation, and creating a predictable change in postoperative corneal power [4]. Despite these advantages, some complications such as high intraocular pressure (IOP) that can lead to graft failure are still encountered after EK [5]. Additionally, extensive corneal decompensation during EK can reduce the visibility of the graft in the recipient's anterior chamber.

The study aims to compare the postoperative visual results, complications, and graft survival rates of Descemet membrane endothelial keratoplasty (DMEK) and Penetrating keratoplasty (PK) in patients with PBK.

## METHODS

The study was conducted by retrospectively reviewing the file records of patients who developed BK after cataract surgery with intraocular lens implantation (IOL) and underwent keratoplasty in a tertiary cornea clinic between 2010 and 2020. Records of 51 eyes of 51 PBK patients (32 male, 19 female) who underwent PK (Group 1=38 eyes) and DMEK (Group 2=13 eyes) (group 2) were reviewed. The hospital's ethics committee approved this retrospective study (Decision no.:

17/2024, Date: 21.02.2024) and the study adhered to the tenets of the Declaration of Helsinki.

Eligible subjects for the study were patients with subepithelial fibrosis, anterior stromal scarring, and corneal edema caused by corneal endothelial decompensation for more than 1 year after cataract surgery. Inclusion criteria: Patients who were followed up for  $\geq 1$  year postoperatively, who were between the ages of 50-85, who had their first corneal transplant, who had not undergone eye surgery other than cataract, who did not have a systemic disease causing eye complications, and who did not have a history of chronic drug use were included in the study. Exclusion criteria: aphakic bullous keratopathy, being  $< 50$  years and  $> 85$  years of age, presence of fundus lesions affecting postoperative vision, and postoperative follow-up periods being less than 1 year.

Age, gender, follow-up period, postoperative complications, best-corrected visual acuity (BCVA) at the first year and the last examination, and whether the graft was transparent at the last examination were recorded from the patient's files. The data of the two groups were compared statistically. Graft survival rates were determined. Visual acuity was measured by Snellen charts was converted to logarithm of the minimum angle of resolution (logMAR) value for analysis. The BCVA of the two groups at the first year and at the last examination were recorded. Vision rates  $> 0.3$  and  $< 1$  were compared statistically between the two groups.

All donor corneas were examined for transparency and smoothness by slit lamp microscope. The morphology and number of endothelial cells were evaluated by specular microscopy. The density of all donors' corneal endothelial cells was  $> 2.000/\text{mm}^2$ . Intraocular pressure was measured with a Goldmann applanation tonometer. The following criteria were used to diagnose secondary glaucoma: IOP or estimated IOP  $\geq 24$  mmHg and need medication to lower it; postoperative IOP is 10 mmHg greater than the preoperative IOP. Translucent long-lasting ( $\geq 1$  year), irreversible corneal edema following surgery is referred to as primary graft failure.

Graft rejection was treated the same in both groups. The patient was hospitalized, and 1mg/kg systemic steroid (prednisolone) treatment and dexamethasone drops administered hourly were started. The dose was reduced according to the recovery status.

## DMEK Surgery

All DMEK surgeries were carried out by the same surgeon (ZYA). First, the donor corneal endothelium obtained from the eye bank and planned to be transferred to the recipient's eye was prepared. For this, the donor corneal endothelium was stripped, stained with 0.06% trypan blue, and then suctioned into a DMEK syringe (DORC International BV) to insert the tissue into the anterior chamber. An 8-mm central area was marked on the recipient cornea to determine the desmatoraxis border. The corneal epithelium was scraped with a crescent blade to increase visibility. The temporal and nasal side ports were opened with a 23-gauge blade. The anterior chamber was filled with air. Desmatoraxis was performed using a reverse sinsky hook. The anterior chamber was entered through a 2.4 mm wide corneal tunnel at 12 o'clock in the upper cornea. The stripped endothelium was removed through the main incision. Air was evacuated from the anterior chamber. Iridectomy was performed with a vitrectomy probe at 6 o'clock. The donor corneal endothelium was injected into the anterior chamber through the main incision using the DMEK syringe. The endothelial roll was opened in the anterior chamber with the endothelium side down, using appropriate maneuvers. Air was injected under the endothelium through the side port. Postoperatively, broad-spectrum antibiotic drops were given 8 times a day and Dexamethasone drops 8 times a day for 2 weeks. Dexamethasone was gradually tapered and then loteprednol was given 4 times a day. It was tapered off at 6 months.

## PK Surgery

The corneal tissue obtained from the eye bank was prepared by cutting it with a punch trephine to be 0.5 mm larger than the recipient bed. The center of the recipient's cornea was marked, and the edematous cornea was cut at the center with a vacuum trephine to a size of 7.25-7.75 mm (adjusted according to the corneal size). It was cut to full thickness with the help of side scissors and removed from the eye. The prepared donor corneal tissue was sutured to the recipient bed with continuous or interrupted sutures. Postoperatively, broad-spectrum antibiotic drops and Dexamethasone drops were given 8 times a day for 2 weeks. Dexamethasone drops were used gradually for 12 months.

Postoperatively, patients were examined on day 1,

week 1, and then at 1, 3, 6, 12, and 24 months. At each visit, data were collected by examining BCVA, IOP, graft status, lens, optic nerve head, and macula. Complications that developed and their treatments were recorded.

## Statistical Analysis

The Shapiro-Wilk test was used to examine whether the data showed normal distribution. Categorical variables are presented as frequency and percentage, and continuous variables are presented as mean  $\pm$  standard deviation. Categorical variables were compared with the Pearson Chi-square test. Normally distributed data were compared with independent samples t-test. Chi-square analysis was used to compare the complications between the two groups. Graft survival curves were generated with the log-rank test and using the standard Kaplan-Meier method. Statistical analyses were performed using IBM SPSS Statistics 23.0 (IBM Corp. Released 2015. IBM SPSS Statistics for Windows, Version 23.0. Armonk, NY: IBM Corp.). P-values below 0.05 were regarded as significant.

## RESULTS

The mean age was  $69.13 \pm 9.68$  and  $67.15 \pm 10.59$  years ( $P=0.538$ ), and the mean follow-up period was  $56.76 \pm 36.68$  and  $29.07 \pm 20.17$  months ( $P=0.013$ ) in group 1 and group 2, respectively. Gender ratios were similar in both groups ( $P=0.575$ ) (Table 1). Graft rejection was seen in 12 eyes in group 1. Two eyes improved with treatment, but irreversible graft rejection occurred in 10 eyes. Irreversible graft rejection occurred in 1 eye in group 2. Graft failure was observed in 12 eyes (31.6%) in group 1 and in 8 eyes (61.5%) in group 2 ( $P=0.056$ ). Endophthalmitis (2.6%), retinal detachment (2.6%), and postoperative ectasia (5.3%) were observed in low numbers only in the PK group. Postoperative glaucoma was observed in 4 eyes (10.5%) in the group 1 and 4 eyes (30.8%) in the group 2 ( $P=0.083$ ). Pupillary block developed in 3 eyes in group 2 and IOP was regulated by postoperative air reduction and anti-glaucomatous medications. However, graft failure developed in these 3 eyes. In group 1, glaucoma was regulated with medications in 2 eyes, and glaucoma surgery was required in the other 2 eyes

**Table 1. Demographic data of participants**

	Group 1 (n=38)	Group 2 (n=13)	P value
<b>Age (years)</b>	69.13±9.68	67.15±10.59	0.538*
<b>Gender, n (%)</b>			0.575 <sup>#</sup>
Male	23 (60.5)	9 (69.2)	
Female	15 (39.5)	4 (30.8)	
<b>Follow-up (months)</b>	56.76±36.68	29.07±20.17	<b>0.013*</b>

Data are shown as mean±standard deviation or n (%).

<sup>#</sup>pearson chi-square test

\*Independent samples t-test

(trabeculectomy in 1 eye, valve implant in 1 eye). There was no significant difference between the two groups regarding other complications ( $P>0.05$ ). Re-grafting was made for 6 eyes (15.8%) in group 1 and 8 eyes (61.5%) in group 2 ( $P=0.001$ ) (Table 2).

The BCVA rates of both groups at the first-year visit and the last follow-up visit are shown in Table 3. BCVA levels were better in Group 2 in both examinations (Table 3).

#### Graft survival Rates

Kaplan–Meier curves for graft survival in the two groups are presented in Fig. 1. The cumulative survival rates for PK and DMEK were 92.1% and 61.5% at 1 year and 89.1% and 51.3% at 2 years, respectively. Median survival time was 108 months in the group 1

and 42 months in the group 2 ( $P=0.001$ ). At the last examination, the rates of transparent grafts were 73.7% and 69.2% in group 1 and group 2, respectively ( $P=0.756$ ).

## DISCUSSION

Bullous keratopathy after cataract surgery may be patient-related or caused by surgery. If existing endothelial numbers are low or endothelial changes such as Fuchs endothelial corneal dystrophy (FECD) are present, there is a risk of developing BK, even after an uncomplicated surgery. Endothelial decompensation may develop due to depletion such as using too much phaco energy during surgery, performing phacoemul-

**Table 2. Comparison of complication rates between study groups**

	Group 1 (n=38)	Group 2 (n=13)	P value*
<b>Graft rejection, n (%)</b>	10 (26.3)	1 (7.7)	0.159
<b>Graft failure, n (%)</b>	12 (31.6)	8 (61.5)	0.056
<b>Glaucoma, n (%)</b>	4 (10.5)	4 (30.8)	0.083
<b>Keratitis n, (%)</b>	6 (15.8)	2 (15.4)	0.972
<b>Endophthalmitis, n (%)</b>	1 (2.6)	0	0.555
<b>RD, n (%)</b>	1 (2.6)	0	0.555
<b>Optic atrophy, n (%)</b>	1 (2.6)	1 (7.7)	0.417
<b>Postoperative ectasia, n (%)</b>	2 (5.3)	0	0.399
<b>Re-keratoplasty, n (%)</b>	6 (15.8)	8 (61.5)	<b>0.001</b>

RD=Retinal detachment

\*Pearson chi-square test

**Table 3. Comparison of visual outcomes between groups**

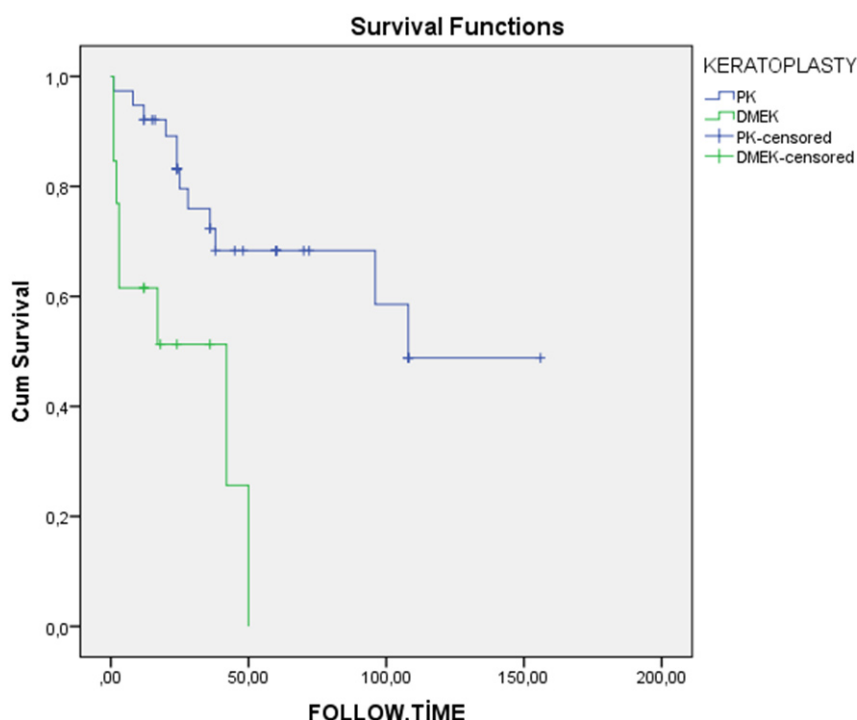
	Group 1 (n=38)	Group 2 (n=13)	P value*
<b>1. year BCVA, n (%)</b>			
>0.3	5 (13.2)	5 (38.5)	<b>0.047</b>
<1	24 (63.2)	6 (46.2)	0.282
<b>Last visit BCVA, n (%)</b>			
>0.3	1 (2.7)	4 (30.8)	<b>0.004</b>
<1	30 (78.9)	8 (61.5)	0.214

BCVA=Best-corrected visual acuity (logMAR)

\*Pearson chi-square test

sification too close to the endothelium, the surgical instrument or cataract piece touching the endothelium, or severe toxic anterior segment syndrome (TASS). The preferred treatment for PBK in recent years has been EK, which permits selective replacement of the

host endothelium rather than PK [6]. Studies on the effectiveness of PK [7] and EK [6, 8] after BK have been previously conducted. However, studies comparing the surgical results of PK and EK in PBK are limited [9-11]. In these studies, PK and Descemet



**Overall Comparisons**

	Chi-Square	df	Sig.
Log Rank (Mantel-Cox)	10.930	1	.001

Test of equality of survival distributions for the different levels of KERATOPLASTY.

**Fig. 1. Comparison of graft survival rates between groups.**



stripping endothelial keratoplasty (DSEK) were compared. To our knowledge, the current study is the first to compare PK with DMEK in PBK. In the current study, the differences between PK and DMEK surgeries in the treatment of PBK were evaluated in terms of visual outcomes, complications, and graft survival.

Since PK has been used in the treatment of BK for many years, the follow-up period was longer in the PK group. The rate of graft rejection is expected to be higher in PK compared to DMEK due to the entire corneal tissue change. In this study, although the rate was higher in the PK group, no statistically significant difference was detected between the two groups. Two other studies comparing PK and DSEK results in the BK also reported that graft rejection rates did not differ significantly [10, 11]. Although the difference was not significant in this study, graft failure was slightly higher in the DMEK group. We think that this is because the learning curve of DMEK surgery is high and the rate of graft failure due to endothelial loss may have increased in surgeries performed in the first years.

Previous studies have shown reduced IOP and steroid needs in EK compared to PK for up to 2 years postoperatively [12]. However, in this study, the glaucoma rate was slightly higher after DMEK, but the difference was not statistically significant ( $P=0.083$ ). After surgery, an IOP elevation can be caused by several factors, including the use of viscoelastic, the reaction to steroids, damage to outflow mechanisms, loss of angle support, and angle closure as a result of synechiae [13]. In the study by Maier *et al.*, the incidence of IOP elevation and glaucoma was found to be lower after DMEK than after DSEK and PK. In this study, steroid-induced IOP elevation was the most common cause [14]. In a study by Sharma *et al.*, in eyes that underwent keratoplasty with different etiologies, IOP increase occurred at a lower rate in the early period after DSEK than in PK. However, there was no significant difference in IOP between the DSEK and PK groups at the 24th week [15]. In the study comparing the glaucoma therapy escalation (GTE) after PK and DSEK in eyes with PBK, no significant difference was found between the two groups [16]. In the current study, the most important reason for the high glaucoma rate after DMEK was the development of the pupillary block. If the air given to ensure adhesion of

the descemet to the recipient bed also closes the iridotomy, the pupillary block may develop. The IOP of these 3 eyes was regulated by reducing the amount of postoperative air and using anti-glaucomatous treatment. However, graft failure occurred because endothelial cells were affected. Although the IOP increased significantly after DMEK, none of them developed glaucoma surgery. However, in the PK group, glaucoma could be regulated by surgery in 2 patients. Since steroid treatment after DMEK is used for a shorter duration and in lower doses, steroid-induced IOP elevation is less expected than after PK surgery. Therefore, in long-term follow-up, the number of eyes with uncontrolled glaucoma requiring surgery after DMEK can be expected to be lower compared to the PK group.

Endophthalmitis, retinal detachment, and postoperative ectasia were observed only in the PK group. Although follow-up periods are different, the risk of endophthalmitis and retinal detachment is a less expected complication in DMEK surgery performed with a more closed system. However, since the entire cornea is opened in PK, the risk of these serious complications increases. Since tissue is not sutured in DMEK surgery, unlike PK, ectasia complications are not expected.

In this study, reDMEK surgery was performed in all 8 eyes that developed graft failure after DMEK. However, after PK, only 6 eyes underwent re-keratoplasty. This may be because replacing the endothelium alone is more advantageous and less risky than full-thickness surgery. Additionally, some patients could not undergo re-keratoplasty surgery because they did not want to have keratoplasty again or because it was thought that a new surgery would be risky due to other health conditions. As a result of these grafts, the transparent graft rates at the last examination were 73.7% and 69.2% in the PK and DMEK groups, respectively. In this study, BCVA levels were found to be significantly higher in the DMEK group at the first year and at the last visit. This is similar to previous studies [10, 11]. The astigmatism resulting from the sutures placed after PK and the altered anterior corneal surface curvature from the whole corneal alteration were considered to be the causes of the DMEK group's better visual acuity.

Contrary to previous studies, in this study, the

graft survival rate was found to be higher in the PK group. First-year cumulative survival rates for PK and DMEK were 92.1% 61.5%, and 89.1% and 51.3% at 2 years, respectively ( $P=0.001$ ). The reason for this difference may be early graft loss due to endothelial loss during DMEK surgeries performed in the early years. In the study by Chen *et al.*, at the last follow-up 1 year after surgery, the graft survival rate in the DSEK group was found to be significantly higher than that in the PK group (91.17% vs. 70.37%,  $P=0.039$ ) [10]. In the study by Kim *et al.*, the 2-year graft survival rates for DSAEK and PK were 93.3% and 81.8%, respectively, and the median graft survival was 56 and 44 months, respectively ( $P=0.344$ ) [11]. In a similar study by Wai *et al.*, 2-year survival rates for DSEK and PK were found to be 80.8% and 75%, respectively [9]. The difference between the studies may be due to less endothelial loss due to easier manipulation of the DSEK graft. Another reason may be that the number of patients in the groups differs in the studies. Manipulation of the endothelial roll in DMEK surgery is a little more difficult than in DSEK and DSAEK surgery. Therefore, until experience is gained during surgery, endothelial loss and subsequent graft failure may occur. To our knowledge, no study comparing DMEK and PK has been conducted before. Additionally, in this study, DMEK surgeries performed in the last year could not be included in the study because their follow-up period was short, and therefore the DMEK numbers are slightly low. For all these reasons, graft survival rates may have been different compared to other studies.

### Limitations

There were some limitations of the current study. Due to the retrospective nature of the study, variables including patient selection, astigmatism adjustment following PK, and endothelial number comparison could not be assessed. The smaller number of patients in the DMEK group, the longer surgical time until experience in DMEK surgery was gained, and the higher rate of graft failure due to endothelial loss that may develop due to the high number of surgical manipulations, may have affected the results of the study. Therefore, prospective studies with more patients are required. However, we believe that this study can provide insight as a pioneering study and that better studies can be carried out by evaluating the deficiencies.

### CONCLUSION

DMEK surgery offers a better visual outcome than PK for the treatment of PBK. However, care must be taken in terms of postoperative glaucoma and graft failure. Even though the DMEK group's graft survival rate was lower in the study, repeat DMEK surgery led to a comparable rate of graft transparency at the final assessment.

### Ethical Approval

All procedures performed in study comply with the ethical standards of the Institutional research committee of the University of Health Sciences Ankara Training and Research Hospital and with the 1964 Helsinki declaration and its later amendments or comparable ethical standards

### Authors' Contribution

Study Conception: ATB, ND, AB, ZYA, EŞ, SU; Study Design: ATB, ND, AB, ZYA, EŞ, SU; Supervision: ATB, ND, AB, ZYA, EŞ, SU; Funding: ATB, ND, AB, ZYA, EŞ, SU; Materials: N/A; Data Collection and/or Processing: ND; Statistical Analysis and/or Data Interpretation: ATB; Literature Review: ATB; Manuscript Preparation: ATB and Critical Review: ZYA.

### Conflict of interest

The authors disclosed no conflict of interest during the preparation or publication of this manuscript.

### Financing

The authors disclosed that they did not receive any grant during conduction or writing of this study.

### REFERENCES

1. Peh GSL, Ang HP, Lwin CN, et al. Regulatory Compliant Tissue-Engineered Human Corneal Endothelial Grafts Restore Corneal Function of Rabbits with Bullous Keratopathy. *Sci Rep.* 2017;7(1):14149. doi: 10.1038/s41598-017-14723-z.
2. Briceno-Lopez C, Burguera-Giménez N, García-Domene MC, Díez-Ajenjo MA, Peris-Martínez C, Luque MJ. Corneal Edema after Cataract Surgery. *J Clin Med.* 2023;12(21):6751. doi: 10.3390/jcm12216751.
3. Lee WB, Jacobs DS, Musch DC, Kaufman SC, Reinhart WJ, Shtein RM. Descemet's stripping endothelial keratoplasty: safety and outcomes: a report by the American Academy of Ophthalmol-

- ogy. *Ophthalmology*. 2009;116(9):1818-1830. doi: 10.1016/j.ophtha.2009.06.021.
4. Anshu A, Price MO, Tan DT, Price FW Jr. Endothelial keratoplasty: a revolution in evolution. *Surv Ophthalmol*. 2012;57(3):236-252. doi: 10.1016/j.survophthal.2011.10.005.
5. Naveiras M, Dirisamer M, Parker J, et al. Causes of glaucoma after descemet membrane endothelial keratoplasty. *Am J Ophthalmol*. 2012;153(5):958-966.e1. doi: 10.1016/j.ajo.2011.10.003.
6. Agarwal A, Narang P, Kumar DA, Agarwal A. Young donor-graft assisted endothelial keratoplasty (PDEK/DMEK) with epithelial debridement for chronic pseudophakic bullous keratopathy. *Can J Ophthalmol*. 2017;52(5):519-526. doi: 10.1016/j.jcjo.2017.03.004.
7. Jung YH, Choi HJ, Kim MK, Oh JY. Etiology and outcome of penetrating keratoplasty in bullous keratopathy post-cataract surgery vs post-glaucoma surgery. *PLoS One*. 2023;18(5):e0285419. doi: 10.1371/journal.pone.0285419.
8. Liarakos VS, Ham L, Dapena I, et al. Endothelial keratoplasty for bullous keratopathy in eyes with an anterior chamber intraocular lens. *J Cataract Refract Surg*. 2013;39(12):1835-1845. doi: 10.1016/j.jcrs.2013.05.045.
9. Wai YZ, Pee XK, Lai YP, Alias R. Descemet stripping endothelial keratoplasty versus penetrating keratoplasty in bullous keratopathy: A 2-year analysis of graft survival and outcomes in a tertiary eye centre in Kuala Lumpur. *Med J Malaysia*. 2023;78(1):74-78.
10. Chen Y, Sun S, Gao M, Liu Q, Wang Z. Comparative observation of the efficacy of simplified Descemet stripping endothelial keratoplasty and penetrating keratoplasty in treating bullous keratopathy. *Exp Ther Med*. 2020;20(5):31. doi: 10.3892/etm.2020.9158.
11. Kim SE, Lim SA, Byun YS, Joo CK. Comparison of Long-term Clinical Outcomes between Descemet's Stripping Automated Endothelial Keratoplasty and Penetrating Keratoplasty in Patients with Bullous Keratopathy. *Korean J Ophthalmol*. 2016;30(6):443-450. doi: 10.3341/kjo.2016.30.6.443.
12. Vu PQ, Aggarwal S, Lu Y, Xie K, Wade M, Bhatt A. Comparison of Intraocular Pressure, Usage of Topical Steroids, Need for Intraocular Pressure Lowering Drops, and Incidence of Glaucoma Surgery Up to 2 Years After Penetrating Keratoplasty and Endothelial Keratoplasty. *J Glaucoma*. 2020;29(12):1120-1125. doi: 10.1097/IJG.0000000000001635.
13. Huber KK, Maier AK, Klamann MK, et al. Glaucoma in penetrating keratoplasty: risk factors, management and outcome. *Graefes Arch Clin Exp Ophthalmol*. 2013;251(1):105-116. doi: 10.1007/s00417-012-2065-x.
14. Maier AK, Wolf T, Gundlach E, et al. Intraocular pressure elevation and post-DMEK glaucoma following Descemet membrane endothelial keratoplasty. *Graefes Arch Clin Exp Ophthalmol*. 2014;252(12):1947-1954. doi: 10.1007/s00417-014-2757-5.
15. Sharma RA, Bursztyn LL, Golesic E, Mather R, Tingey DP. Comparison of intraocular pressure post penetrating keratoplasty vs Descemet's stripping endothelial keratoplasty. *Can J Ophthalmol*. 2016;51(1):19-24. doi: 10.1016/j.jcjo.2015.09.014.
16. Aldarrab A, Alsakran W, Al-Swailem SA, Al-Shahwan SA. Comparison of Glaucoma Therapy Escalation After Penetrating Keratoplasty to Descemet Stripping Automated Endothelial Keratoplasty for the Treatment of Pseudophakic Bullous Keratopathy: A Cohort Study. *Middle East Afr J Ophthalmol*. 2023;29(2):72-79. doi: 10.4103/meajo.meajo\_21\_22.