

Spontaneous Triceps Hematoma and Radial Nerve Impairment due to Warfarin Use

Warfarine Kullanımına Bağlı Spontan Triseps Hematomu ve Radial Sinir Arazı

 Zeynep Saral Öztürk

 Emine Emektar

 Yunsur Çevik

Ankara Atatürk Sanatory Education And Research Hospital, Clinic of Emergency Medicine, Ankara, Türkiye

ABSTRACT

Intramuscular hemorrhages and hematomas are a complication of anticoagulation in patients using warfarin as an anticoagulant. Hematomas may be due to trauma or may develop spontaneously. Neuropathies due to direct compression of hematomas or hemorrhage around the nerve may rarely occur. We aimed to present a case of spontaneous hematoma in the triceps muscle and associated radial nerve deficit in a patient taking warfarin for valvular disease. The hematoma was evacuated after prothrombin complex concentrate and vitamin K. The patient's nerve deficit improved in the follow-up. Early evacuation of the haematoma may be important for favorable outcomes.

ÖZET

Antikoagülan olarak warfarin kullanan hastalarda kas içi kanamalar ve hematomlar antikoagülasyonun bir komplikasyonu olarak karşımıza çıkmaktadır. Hematomlar travmaya bağlı olabileceği gibi spontan da gelişebilir. Hematomların direk basısı nedeniyle veya sinir çevresine olan kanamalara bağlı olarak nöropatiler nadiren karşımıza çıkabilmektedir. Kapak hastalığı nedeniyle warfarin kullanan hastada spontan triseps kası içerisinde hematom ve buna bağlı gelişen radial sinir arazı gelişen olgumuzu sunmayı amaçladık. Protrombin kompleks ekresi ve K vitamini sonrası hematom boşaltılmış ve takibinde hastanın sinir kusuru düzelmiştir. Hematomun erken boşaltılması yüz güldürücü sonuçlar açısından önemli olabilir.

Keywords:

Warfarin
Triceps hematoma
Radial nerve deficit

Anahtar Kelimeler:

Warfarine
Triseps hematomu
Radial sinir arazı

INTRODUCTION

Anticoagulant drugs are used to prevent thromboembolic events. Warfarin, a vitamin K antagonist, has an important place among anticoagulant drugs. However, regular international normalization ratio (INR) monitoring is needed to ensure effective dosing and to prevent unwanted complications. The annual incidence of bleeding in warfarin users is around 2-8 (1). Although bleeding complications can be grouped as major and minor, this definition is not standardized. Intracranial hemorrhage is the most serious bleeding complication with a mortality rate of 60% (2). Although intramuscular hematomas may be seen as a complication of anticoagulation, the incidence of neuropathy is not known exactly (3).

Although hemorrhage-induced neuropathy is a rare condition, its prominent clinical findings may be a warning in terms of diagnosis (3). Symptoms and signs include pain in the distribution area of the involved nerve, sensory deficit and motor involvement. Although neuropathy after hematoma has been reported in the literature, reports of radial neuropathy are rare (1,4). Here, we aimed to discuss a patient with a hematoma in the triceps muscle after warfarin use and associated radial nerve impairment.

CASE REPORT

A 70-year-old woman presented to the emergency department with bruising on the right elbow and upper arm. She had no history of trauma. She had a history of mitral valve replacement and heart failure. The patient was taking diltiazem, digoxin, furosemide and warfarin. On physical examination, the patient was conscious, oriented and coherent. Blood pressure arterial: 104/55 mmHg, pulse: 101 beats/minute, temperature 36 °C, oxygen saturation 98%. There were ecchymosis on the right elbow lateral and medial and above the elbow (Figure 1). Radial and ulnar pulses were obtained. Radial, ulnar and median nerve examinations were normal. Although the patient had no history of trauma, X-ray imaging of the right elbow and right humerus was performed because of the ecchymosis. No fracture was observed on X-ray. INR level was 11.43 and platelet count was $291 \times 10^3/\mu\text{L}$. Other laboratory tests were normal. The patient was administered 5 mg vitamin K intravenously (IV) with an INR >10, to prevent compartment syndrome from bleeding in the arm and for rapid onset of action. One day later, the patient was extened with a recommendation for outpatient follow-up. The next day, the patient presented to the emergency

Correspondence: Zeynep Saral Öztürk, Ankara Atatürk Sanatory Education And Research Hospital, Clinic of Emergency Medicine, Ankara, Türkiye. **E mail:** drzeynepsaral@gmail.com

Cite as: Saral Öztürk Z, Emektar E, Çevik Y. Spontaneous Triceps Hematoma and Radial Nerve Impairment due to Warfarin Use. Phnx Med J. 2024;6(2):86-88.

Received: 06.04.2024

Accepted: 01.07.2024

Online Published: 04.07.2024



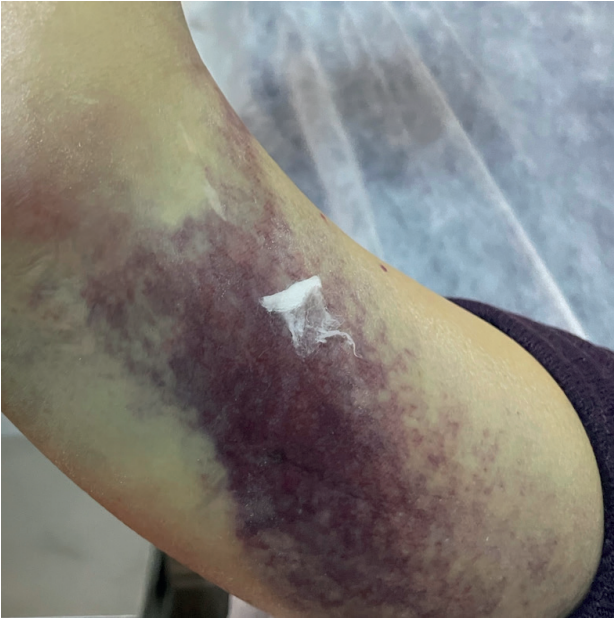


Figure 1: Ecchymosis on the patient's arm

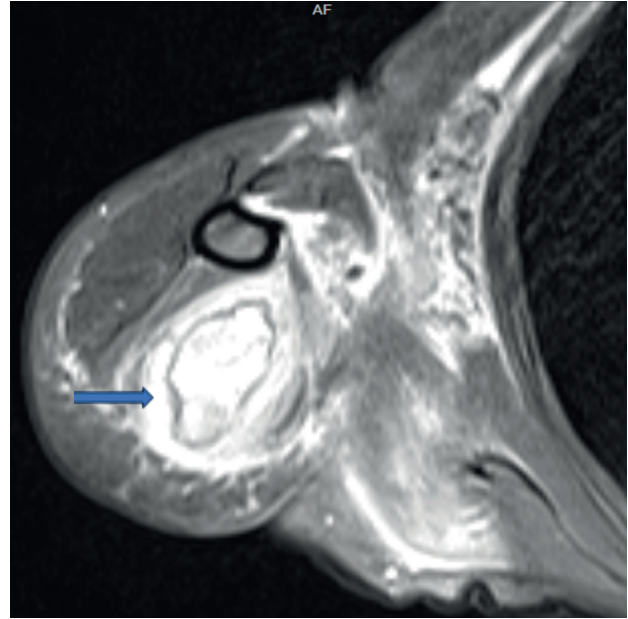


Figure 2: MR image of the hematoma

department again with the complaint of inability to extend the right hand. Physical examination revealed no right hand dorsiflexion movement. There was loss of sensation in the 1st finger of the right hand and loss of sensation except pain sensation in the other fingers. Complete blood count and INR tests were performed. INR level was 6.52, platelet count was $270 \times 10^3/\mu\text{L}$. Other tests were normal. Superficial ultrasonography (USG) was performed on the right arm. In the USG report, there was an intramuscularly located organized hematoma area extending from the proximal 1/3 of the dorsal aspect of the right arm to the elbow level and reaching a depth of 4 cm. Hematoma evacuation was planned because the patient's symptoms were new. After administration of prothrombin complex concentrate (PCC) and 5 mg vitamin K IV 65 cc hematoma was drained by interventional radiology. The patient was evaluated with the orthopedic clinic and hospitalized in the orthopedic clinic for follow-up and treatment. One day later, right elbow magnetic resonance imaging (MRI) was performed. Hematoma size was measured as 126*40 mm (Figure 2). The patient was discharged on the fifth day with normal neurological examination and no increase in hematoma size.

DISCUSSION

In addition to anticoagulants such as heparins and vitamin K antagonists, there is a new generation of anticoagulants that directly target the enzymatic activity of thrombin and factor Xa. Anticoagulants are used in conditions such as myocardial infarction, venous thromboembolism and atrial fibrillation. An estimated 1% of the European population uses warfarin, a vitamin K antagonist (2). The most serious side effect of these drugs is bleeding. The risk of major bleeding varies between 1% and 7.4% (2). Intracranial hemorrhage, gastrointestinal bleeding, compartment syndrome due to intramuscular hemorrhage are serious bleeding complications. There are studies in the literature showing that these complications occur more frequently in the elderly without trauma (5). Our patient also had a spontaneously developing intramuscular hematoma.

On initial examination, neurovascular examination was normal and there was no clinical evidence of compartment syndrome. However, the following day the patient developed radial nerve impairment due to hematoma.

Warfarin is monitored by INR level. Bleeding can be observed in 40% of patients with normal INR levels (1). Although the risk of bleeding increases as the level increases, cases of compressive neuropathy in the therapeutic range have been reported in the literature (1,3). The first INR measured in our patient was 11.43. She had intramuscular non-traumatic hematoma due to high INR level.

Anticoagulation-related hematoma may occur in various muscle groups and cases of neuropathy related to it are available in the literature (6, 7). In the literature, it is observed that this complication is more frequent in heparin treatment (45%) compared to warfarin treatment (18%) and involves the lower extremity nerves more frequently with a rate of 87% (7). Although the pathophysiology has not been fully elucidated, neuropathy is observed probably due to bleeding into the nerve or nerve compression of the hematoma. Cases of spontaneous hematoma-related neuropathy in patients using warfarin have been reported in the literature (4). These cases include femoral nerve, sciatic nerve, median and ulnar nerve compression (1,3,5). In our case, radial nerve impairment due to hematoma developing in the triceps was present.

In cases of INR elevation or bleeding due to Warfarin overdose, the treatment that can be applied is discontinuation of the drug and oral or IV administration of vitamin K. The first of the two important factors here is the indication and the need for ongoing anticoagulation, and the second is the rate of INR reversal required by bleeding. Other treatment options include fresh frozen plasma and PCC. Treatment options may vary depending on the INR level of the patient and the type of bleeding. Rapid INR decrease is important in major bleeding states (2). In our patient, vitamin K was used in the first treatment in order to prevent any findings other than intramuscular

hematoma and to prevent this hemorrhage from causing compartment syndrome.

Conservative treatments were used in 85% of hematoma-related neuropathies (8). Evacuation of the hematoma is another treatment option to reduce compression. In a study, it was emphasized that surgical treatment may be a good option (9). In hematomas drained within 48 hours, it is observed that neurologic loss is completely recovered, but after 48 hours, the success rate decreases to 50% and the neurologic deficit becomes difficult to reverse (8). Therefore, conservative approach becomes more prominent as time passes after hematoma formation, but delay in treatment may result in permanent damage (3). Since there are few cases in the literature, it is controversial whether a conservative approach or early drainage is more

appropriate. However, drainage of the hematoma may reverse ischemia by decreasing the pressure effect. There are publications in the literature recommending surgical drainage (4). In our case, the hematoma was drained after administration of PCC and vitamin K with rapid onset of action in order to reduce the compression. Early recovery of the nerve defect suggested that this treatment approach may be beneficial. It has been reported that even small drainage may be beneficial (9).

CONCLUSION

Although neuropathies due to intramuscular hematoma have been reported, there is no clear treatment procedure. Therefore, we believe that hematoma evacuation should be considered as a treatment for neuropathies, which is a rare complication, and early treatment may be beneficial.

Conflict of Interest: No conflict of interest was declared by the authors.

Ethics: The patient informed consent form was obtained.

Funding: There is no financial support of any person or institution in this research.

Approval of final manuscript: All authors.

REFERENCES

1. Yaycioglu S, Ak H. Concomitant ulnar and median nerve entrapment due to spontaneous hematomas at humerus mid-shaft under warfarin treatment: Case report. *Journal of Neurological Sciences (Turkish)*. 2010;27:239-243.
2. Wiedermann CJ, Stockner I. Warfarin-induced bleeding complications clinical presentation and therapeutic options. *Thromb Res*. 2008;122 Suppl 2:S13-8.
3. K Reddy VP, Rangasami R, Vignesh G. Sciatic Nerve Hematoma-Case Report. *Neurol India*. 2021;69:1043-1044.
4. Apostolopoulos A, Kosmas L, Angelis S, Balfousias T, Filippou D. Femoral Nerve Palsy Secondary to Iliopsoas Spontaneous Haematoma in a Patient Under Warfarin Treatment. *Cureus*. 2020;12:e7610.
5. Dagar S, Emektar E, Uzunosmanoglu H, Cevik Y. Assessment of factors affecting mortality in geriatric patients with warfarin overdose. *Turk J Emerg Med*. 2020;20:180-185.
6. Takahashi K, Nihei T, Aoki Y, Nakagawa M, Konno N, Munakata A, Okawara K, Kashimura H. Spontaneous rectus sheath hematoma associated with warfarin administration: a case report. *J Rural Med*. 2019;14:245-248.
7. King RB, Bechtold DL. Warfarin-induced iliopsoas hemorrhage with subsequent femoral nerve palsy. *Ann Emerg Med*. 1985;14:362-4.
8. Elesber AA, Kent PD, Jennings CA. Compressive neuropathy of the brachial plexus and long thoracic nerve: a rare complication of heparin anticoagulation. *Chest*. 2001;120:309-11.
9. Parmer SS, Carpenter JP, Fairman RM, Velazquez OC, Mitchell ME. Femoral neuropathy following retroperitoneal hemorrhage: case series and review of the literature. *Ann Vasc Surg*. 2006;20:536-40.