

# A Typical Fat Necrosis of the Breast Mimicking Cancer Following Breast Reduction

*Meme Küçültme Sonrası Meme Kanserini Taklit Eden Tipik Bir Yağ Nekrozu*

Savaş Serel<sup>1</sup>, Ebru Düşünceli Atman<sup>2</sup>, Sancar Bayar<sup>3</sup>

<sup>1</sup> Ankara University Faculty of Medicine, Plastic, Reconstructive and Aesthetic Surgery Department

<sup>2</sup> Ankara University Faculty of Medicine Department of Radiology

<sup>3</sup> Ankara University Faculty of Medicine, Department of Surgical Oncology

Traumatic fat necrosis can result in a spectrum of imaging appearances that range from characteristically benign to those indistinguishable from malignancy in mammography. In such cases, biopsy might be required for diagnosis. The present case demonstrates a suspicious mammographic mass lesion appearing following a reduction mammoplasty.

**Key words:** *Fat necrosis, Reduction mammoplasty, Mammography*

Travmatik yağ nekrozu mammografide karakteristik olarak benign görüntüden maligniteden ayrılamayan görüntüye neden olabilen bir yelpazede yer alır. Bu tür olgularda tanı için biyopsi gerekebilir. Bu olguda meme küçültme sonrası ortaya çıkan mammografide şüpheli bir kitle lezyonu sunulmuştur.

**Anahtar Sözcükler:** *Yağ nekrozu, Meme küçültme, Mammografi*

Fat necrosis of the female breast was first described by Lee and Adair in the 1920s and later reviewed by Hadfield. Traumatic fat necrosis of the breast is a nonsuppurative inflammatory process, which may result in any one of a variety of radiographic appearances, one or more of which may be confused with carcinoma both clinically and radiographically; so accurate diagnosis requires biopsy. In unusual cases, it may be extensive enough to present as a palpable mass on physical examination with mammographic features suggestive of cancer.

## Epidemiology

The incidence of the disease is estimated to be 0.6% in the breast, representing 2.75% of all benign lesions (1-4). Fat necrosis is found in 0.8% of breast tumors and 1% of breast reduction surgery cases.

## Etiology

The changes of fat necrosis may be seen following blunt trauma, cyst

aspiration, biopsy, lumpectomy, radiation therapy, reduction mammoplasty, breast reconstruction with a transverse rectus abdominis myocutaneous (TRAM) flap, implant removal, and anticoagulant therapy, as well as in patients without a relevant history (5-7).

## Pathogenesis

Histopathologically, there is local destruction of fat cells with the development of variably sized intracellular vacuoles filled with necrotic lipid material. Fat necrosis is a sterile, inflammatory process which results from aseptic saponification of fat by means of blood and tissue lipase. It is recognised histologically as fat-filled macrophages and foreign body giant cells surrounded by interstitial infiltration of plasma cells. Branching, rod-like, or angular microcalcifications associated with fat necrosis may resemble the calcifications associated with carcinoma (3, 6, 7).

Received : 12.11.2011 • Accepted: 15.01.2014

Corresponding Author

Doç.Dr.Savaş SEREL

Phone : 595 72 29

E-mail Address : savassserel@gmail.com

Address : Ankara University Faculty of Medicine, Plastic, Reconstructive and Aesthetic Surgery Department

## CASE REPORT

A 52-year old female noticed a lump in the upper outer quadrant of her right breast. She had vertical bipedicle flap technique (McKissock) breast reduction mammoplasty operation six years ago. The patient consulted our hospital complaining of a palpable mass in her right breast. Physical examination revealed bilateral prominent circumareolar and inframammary scars and firm, 4 x 4 cm lump in the upper outer quadrant of her right breast. Firm, irregular, fixed masses were palpated in the superior aspect of both breasts. No axillary lymph nodes were palpated. There was no history of trauma apart from surgical operation. Excisional biopsy was done under general anesthesia. As a result of the pathologic examination the lump was diagnosed as a fat necrosis.

## DISCUSSION

Fat necrosis occurs most often in the fatty, pendulous breasts of middle-aged women. Fat necrosis of the breast has a variety of clinical and imaging features that may be confused with malignancy (3). It has long been recognized as having an extremely variable presentation, occasionally imitating malignant lesions clinically and mammographically. The patient may be asymptomatic and the pathologic condition may not come to the physician's attention until discovered on mammography. The mammographic spectrum of appearances of fat necrosis ranges from the characteristically benign to the potentially malignant. Mammographic findings in fat necrosis of the breast include lipid cysts, microcalcifications, coarse calcifications, spiculated areas of increased opacity, and focal masses (1-4, 8). It is important to

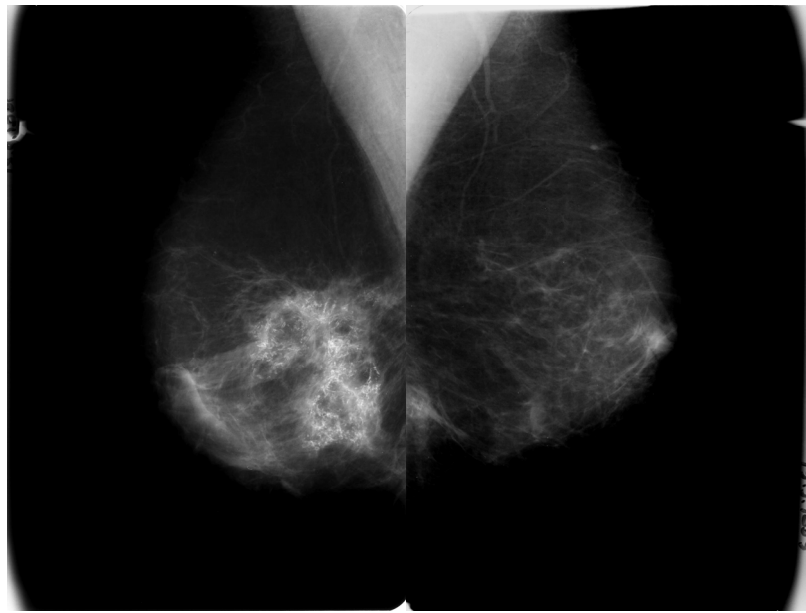


Fig.1a

Fig. 1b

**Figure. 1.** (a) Bilateral mammography screen. Mediolateral and (b) craniocaudal views demonstrate asymmetrical radioluscent fat cysts and diffuse pleomorphic, irregular calcifications in the right lower quadrant of the breast. Nodular calcifications can be seen on left inferomedial quadrant of the breast (fat necrosis).

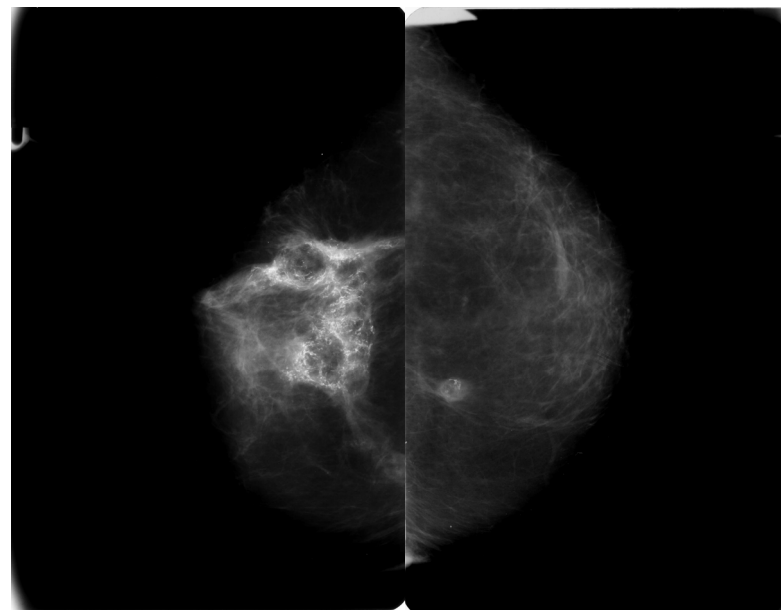


Fig.2a

Fig. 2b

**Figure 2 (a) and 2 (b):** Dystinctive hypoechoic lesions on the right breast.

recognize the mammographic spectrum of appearances of fat necrosis to avoid unnecessary biopsy and to avoid overlooking breast cancer. This case report demonstrates the mammographic spectrum of fat necrosis, including the typical appearances that mimic breast carcinoma. A review of this

typical case leads us to the important conclusion that while breast carcinoma in some cases has characteristic radiographic findings, there are no "pathognomonic" findings. The diagnosis of fat necrosis should only be a diagnosis by exclusion of malignancy.

## REFERENCES

1. Chala LF, de Barros N, Moraes PC, et al. Fat necrosis of the breast: mammographic, sonographic, computed tomography, and magnetic resonance imaging findings. *Curr Probl Diagn Radiol* 2004;33:106-126.
2. Danikas D, Theodorou SJV, Kokkalis G, et al. Mammographic findings following reduction mammoplasty. *Aesth Plast Surg* 2001;25:283-285.
3. Mandrekas AD, Assimakopoulos GI, Mastorakos DP, Pantzalis K. Fat necrosis following breast reduction. *Br J Plast Surg* 1994;47:560-562.
4. Lyle WG, Bossard KR, Day DS. Sclerosing lobular hyperplasia of the breast after reduction mammoplasty. *Ann Plast Surg* 2000;45:454-457.
5. Mizgala CL, MacKenzie KM. Breast reduction outcome study. *Ann Plast Surg* 2000;44:125-134.
- 6- Baillie M, Mok PM. Fat necrosis in the breast: Review of the mammographic and ultrasound features, and a strategy for management. *Australasian Radiology* 2004;48:288-295
- 7- Tan PH, Lai LM, Carrington EV, et al. Fat necrosis of the breast—A review. *The Breast* 2006;15, 313-318
- 8- Dinakara Babu E, Balasubramaniam B, Dawson JW. Triple assessment of fat necrosis of the breast. *Eur J Surg Oncol* 2001;27:816.
- 9- Hogge JP, Robinson RE, Magnant CM, et al. The mammographic spectrum of fat necrosis of the breast. *Radiographics* 1995;15:1347-1356.

