

Bilateral triple renal arteries

Bilateral triple renal arterler

Erol Şener¹, Alper H. Uzun², Kanat Özişik³, Levent Çetin², Mustafa Emir¹

¹ Türkiye Yüksek İhtisas Hospital Cardiovascular Surgery, Ankara, Turkey

² Ankara Education and Research Hospital, Department of Cardiovascular Surgery, Ankara, Turkey

³ Ankara Numune Education and Research Hospital, Department of Cardiovascular Surgery, Ankara, Turkey

Variations in the renal vessels have been observed frequently, either in routine dissections or in clinical practice. But bilateral triple renal arteries existing with another disease is rare. Bilateral triple renal arteries in a 49-years old male patient with aortoiliac artery occlusive disease is presented in this case report.

Key words: *renal artery malformation, occlusive arterial disease*

Renal damarların varyasyonlarına rutin diseksiyon veya klinik çalışmalarda sıklıkla rastlanmaktadır. Ancak bilateral triple renal arterin diğer hastalıklarla birlikte görülmesi sık değildir. Bu olgu sunumunda, bilateral triple renal arter ve aortoiliak tıkalı damar hastalığı olan 49 yaşında bir erkek hasta sunuldu.

Anahtar sözcükler: *renal arter malformasyonları, tıkalı damar hastalığı*

Variations in the renal vessels have been observed frequently, either in routine dissections or in clinical practice. Renal artery variations including their number source and course are very common (1). But bilateral triple renal arteries existing with another disease is rare (2). Bilateral triple renal arteries in a patient with aortoiliac occlusive disease is presented in this case report.

Case report

A 49-year old male patient was admitted to our hospital with symptoms of weight loss and intermittent claudication in the last 9 months. He underwent coronary artery bypass grafting 2 years ago and had a history of smoking for 30 years. On physical examination, right femoral artery pulse was not palpable, and patient was cachexic. Renal functions were found to be normal. His blood chemistry showed an increase in lipid and cholesterol levels.

Selective digital subtraction angiography (DSA) confirmed occlusion of the right common iliac, celiac, superior and inferior mesenteric arteries. The etiology was suggested to be atherosclerosis. On both sides arterial trunks arised from the aorta, which then bifurcated to form upper two renal arteries. The third renal arteries directly arised from aorta in lower position on both sides (Figure 1).

In the first day of his clinical course, he complained symptoms of acute abdomen (melena, abdominal pain, defense and distention). And therefore he was operated urgently in gastroenterologic surgery department in our hospital. In operation there were diffuse necrotic areas in small intestine. Resection and ileostomy were applied. The haemodynamic parameters were impaired postoperatively and patient was lost in the second postoperative day.

Received: Dec 11, 2003 • Accepted: Sept 23, 2004

Corresponding Author

Kanat Özişik, MD

23. Cad. Kırkkonaklar mah. Simkent sitesi 2.blok. No:6/13

06610 Ankara, Turkey

Phone : +90 312 4952530

Fax : +90 312 3103460

E-mail : sozisik2002@yahoo.com

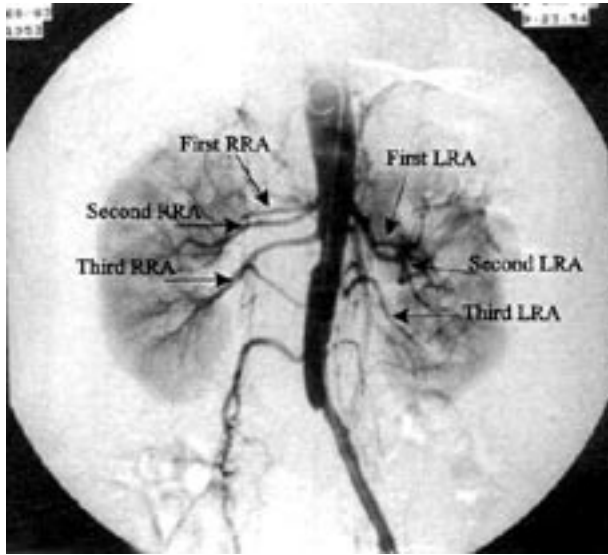


Figure 1. Preoperative DSA showing occlusion of the right common iliac, celiac, superior- inferior mesenteric arteries and bilateral triple renal arteries.

RRA: Right renal artery,
LRA: Left renal artery

Discussion

Supernumerary renal arteries vary in number from two to four, although there may be, rarely, five or six, arranged either unilaterally or bilaterally. A single renal artery on one side and multiple (two, three, or four) renal arteries on the other is not unusual (3). Within an 8 year study

of the renal blood supply, the Bordei and Antohe assessed 14 cases of triple renal arteries, 2 of them bilaterally (both on human fetuses), so a total of 16 triple renal arteries (4). Merklin et al, who reviewed 11.000 necropsy studies, reported that, triple renal arteries were found to be in 70 (0.6 %) cases (5).

There may be several renal arteries on each side, or the renal artery may divide, close to its origin, into several branches. The renal artery may arise from the bifurcation of the aorta or from the common iliac, internal iliac, or inferior mesenteric artery. Branches of the renal artery may perforate the substance of the kidneys instead of entering from the hilus (so called accessory branches). Accessory renal arteries varying in size and generally derived from the aorta are common and may enter kidneys at almost any point (6). In our case on both sides arterial trunks arised from the aorta, which then bifurcated to form upper two renal arteries. The third renal arteries directly arised from aorta in lower position on both sides.

Almost all of the studies of this kind of renal artery variations were made and evaluated by the anatomists. It is also important for the surgeons and radiologists to be aware of the possible renal artery variations in order to prevent complications during diagnostic and therapeutic implications, including surgical procedures for renal transplantation and abdominal aortic diseases.

References

1. Spanos PK, Simmons RL, Kjellstrand CM, et al. Kidney transplantation from living related donors with multiple vessel. A problem reviseted. *Am J Surg* 1973;125:554-558.
2. Bayazit M, Gol MK, Zorlutuna Y et al. Bilateral triple renal arteries in a patient with iliac artery occlusion: a case report. *Surg Radiol Anat* 1992;14:81-83.
3. Nathan H, Glezer I. Right and left accessory renal arteries arising from a common trunk associated with unrotated kidneys. *J Urol* 1984; 132:7-9.
4. Bordei P, Antohe DS. Anatomical study of triple renal arteries. *Morphologie* 2002;86:37-41.
5. Merklin RJ, Michels NA. The variant renal and suprarenal blood supply with data on the inferior phrenic, urethral and gonodal arteries. *J Int Coll Surg* 1958;29:41-76.
6. Jeffery RE. Unusual origins of renal arteries. *Radiology* 1972; 102:309-310.