

Sarcocystosis in The Cremaster Muscle of an Infertile Bull, Spermiostasis and Orchitis

Kamil SAĞLAM¹, Hikmet KELEŞ^{2*}

¹*Ondokuz Mayıs University, Faculty of Veterinary Medicine, Department of Surgery, Samsun, TURKEY*

²*Afyon Kocatepe University, Faculty of Veterinary Medicine, Department of Pathology, Afyonkarahisar, TURKEY*

Corresponding author e-mail: hkeles@aku.edu.tr

ABSTRACT

In this report, macroscobical and microscobical findings of an infrequent sarcocystosis, located in the Musculus cremaster, and its possible effects on the fertility by external genital organs in a bull were described. The case was detected in a slaughtered bull in a slaughterhouse. During inspection, thickened M. cremaster drew attention in a bull. In addition, slightly increased testes and epididymides, and inconsiderable proliferative lesions on the caput epididymides were detected. In microscobical examination, *Sarcocystis* cysts in the cremaster muscle, spermiostasis and extravasation of spermatozoa in the epididymides, and weak intratubular orchitis in the testes were observed.

Keywords: Bull, M.cremaster, Orchitis, Sarcocystosis, Spermiostasis

İnfertil Bir Boğanın Cremaster Kasında Sarkosistozis, Spermiostazis ve Orşitis

ÖZ

Bu olgu sunumunda, bir boğada Musculus cremaster yerleşimli ender bir sarkosistozis'in makroskobik ve mikroskobik bulguları ile bu olayın fertilité üzerine olası etkileri eksternal genital organlar üzerinden irdelendi. Olgu mezbahada kesilen bir boğada teşhis edildi. İnspeksiyon esnasında bir boğada hacimce artmış M. cremaster dikkati çekti. Ayrıca, testisler ve epididimlerde hafif büyüme ile kaput epididimiste çok hafif proliferatif lezyonlar tespit edildi. Mikroskobik incelemede, Cremaster kasında sarkosistis kistleri, epididimiste spermiostazis ve ekstravase spermatozoa ve testiste hafif intratubuler orşitis gözlemlendi.

Anahtar Kelimeler: Boğa, M.cremaster, Orşitis, Sarkosistozis, Spermiostaz

To cite this article: **Sağlam K, Keleş H.** Sarcocystosis in The Cremaster Muscle of an Infertile Bull, Spermiostasis and Orchitis. *Kocatepe Vet.J. 2016; 9(3):252-254.*

INTRODUCTION

Sarcocystis spp. are cyst-forming coccidian parasite that infect mammals, birds, and cold-blooded vertebrates (Dubey et al. 1989, Valentine and McGavin 2007, El-Dakhly et al. 2011, Bucca et al. 2011). *Sarcocystis cruzi*, *S. hirsuta*, and *S. hominis* are main parasites which found in cattle (Dubey and Lindsay 2006). The prevalence of Sarcocystosis, a one of the most prevalent parasitic diseases of cattle, can vary depending on several factors such as, management, age, type, and anatomical site of diagnosis. Some *Sarcocystis* spp. can cause to anemia, weight loss, abortion, and even death in animals, in cases of severe infections (Dubey et al. 1989).

In general, any grossly visible lesions seen in the animals with sarcocystosis at the post mortem inspection (Valentine and McGavin 2007). Diagnosis can be made only by microscopic observation of parasites in the specific muscles (Dubey et al. 1989). Previous field studies aimed to determine prevalence, distribution, and economical importance of sarcocystosis. But in this study it will be taken into account possible secondary effects of sarcocystosis, which settled in the M. cremaster, on the infertility.

CASE HISTORY and DISCUSSION

The case was noticed by coincidence during a study on the male genital tract pathology. In the course of inspection, it was noticed in a crossbred bull which slaughtered due to infertility. The tissue samples of M. cremaster, testes, and epididymides were fixed in 10% buffered formalin. After routine procedures, tissues were blocked with paraffin and cut in 5-micron thickness. Sections were stained with Hematoxylin and eosin (HE) and examined under light microscope. Sarcocystosis was verified morphological criteria's of Dubey et al. (1989).

Macroscopically bilateral hypertrophy was seen in the M. cremaster (Fig. 1). Thickened tunica vaginalis was showed slight, firm, and white adhesions between parietal and visceral parts. A few scattered yellowish foci, which approximately 1 cm in diameter, were detected in the cut surfaces of testes. A white to gray creamy content was seen in the caput epididymides.

In microscopical examination, intracytoplasmic settled globular to oval-shaped micro-cysts, were seen in the myofibers of cremaster muscle (Fig. 2-3). These slightly compartmentalized Sarcocystis cysts (sarcocysts) were contained tightly packed zoites with fine septal partitions. In addition to evident degeneration, inflammatory debris was seen in some areas of the testes mainly intratubular and lesser interstitial (Fig. 4). Excessive spermatozooids with pyknotic nuclei were seen in the dilated ducts of epididymides and extravasation of spermatozoa were seen in caput epididymis (Fig. 5-6).

Sarcocystosis is diagnosed as an incidental finding at necropsy or during meat inspection at slaughter (Valentine and McGavin 2007). Target muscular tissues of *Sarcocystis* spp. are the heart, tongue, esophagus, and diaphragm (Dubey et al. 1989). However, *Sarcocystis* spp. cysts have been reported several other muscles (Ono and Ohsumi 1999, Bucca et al. 2011).

Because they are intracellular within the myofibers, cysts are protected from the host's defense mechanisms; thus there is no inflammatory response. If the cyst wall breaks down, a focus of myofiber necrosis and later granuloma formation occur (Valentine and McGavin 2007).

Uncommonly, fever, anorexia, and progressive wasting were reported in massive exposure. Eosinophilic myositis is a disease of cattle thought to be a relatively uncommon manifestation of *Sarcocystis* spp. infection that may involve hypersensitivity (Valentine and McGavin 2007). Overt green discoloration of affected muscles caused by the massive infiltration of eosinophils is a defect which results in economic loss (Ono and Ohsumi 1999; Dubey and Lindsay 2006).

In recent, Bucca et al. (2011) has been reported sarcocystosis in a lot of muscle including M. cremaster. They mentioned only types and localizations of parasites. Likewise, we detected sarcocystosis in the M. cremaster and also, slight intratubular orchitis and epididymal spermiostasis in the animal. Spermatozooids which deposited in the ductal areas showed evident morphological impairment. Moreover, extravasations of spermatozoa, which can cause spermatoc granuloma, were detected in the epididymis.

Cremaster muscle and some other important tissues e.g. scrotum, tunica vaginalis, ductus deferens, and pampiniform plexus, are to protect and maintain spermatogenesis. In addition to other functions, these structures undertake different tasks to keep testicular temperature lower than body temperature. The testes are raised or lowered, according to ambient temperature, by the cremaster muscle (Foster 2007). Temperature increases, because of upset of thermoregulatory function, can cause testicular degeneration. Furthermore, obstruction of spermatozoal flow is a cause for testicular degeneration. But, testicular degeneration also causes spermiostasis. Spermiostasis and extravasation of spermatozoa, observed in our case, is an important cause of infertility (Keleş 2002).

In conclusion, in addition the negative reflects on animal production, meat quality and human health, sarcocystosis may be an important infertility cause in bulls.

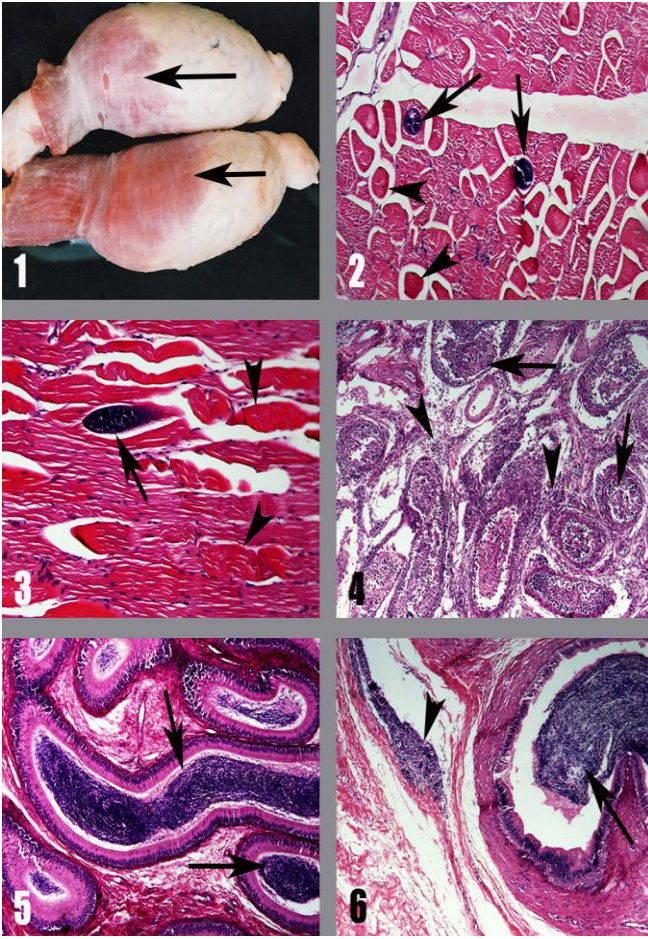


Figure legends:

- 1- Bilateral hypertrophy in the M. cremaster (arrows).
- 2- Sarcocystosis; encysted parasites in the myofibers (arrows) and degenerated myofibers (arrowheads). Transversal section of M. cremaster, HEx100.
- 3- Sarcocystosis; encysted parasite in the myofiber (arrow) and degenerated myofibers (arrowheads). Longitudinal section of M. cremaster, HEx100.
- 4- Intratubular orchitis; degeneration and inflammatory cells in the tubules (arrows) and interstitial areas (arrowheads), Testis, HEx40.
- 5- Spermiostasis; excessive spermatozooids in the dilated ducts (arrows). Epididymis, HEx40.
- 6- Spermiostasis; excessive spermatozooids with pyknotic nuclei in the dilated ducts (arrow) and extravasation of spermatozoa in caput epididymis (arrowhead). Epididymis, HEx40.

Resim Uzantıları:

- 1- M. cremasterde bilateral hipertrofi (oklar).
- 2- Sarcocystosis; myofibriller içerisinde ankiste parazitler (oklar) ve dejenere

miyofibriller (okbaşları). M. cremasterin transversal kesiti, HEx100.

- 3- Sarcocystosis; myofibril içerisinde ankiste parazit (ok) ve dejenere miyofibriller (okbaşları). M. cremasterin longitudinal kesiti, HEx100.
- 4- İntratubular orşitis; dejenerasyon ve tubul lümenleri (oklar) ile interstisyel bölgelerde (okbaşları) yangı hücreleri, Testis, HEx40.
- 5- Spermiostaz; dilate duktuslarda aşırı spermatozoit birikimi (oklar). Epididimis, HEx40.
- 6- Spermiostaz; dilate tubuluslarda piknotik çekirdekli çokça spermatozoit birikimi (ok) ve kaput epididimiste ekstravaze spermatozoa (okbaşı). Epididimis, HEx40.

REFERENCES

- Bucca M, Brianti E, Giuffrida A, Ziino G, Cicciani S, Panebianco A.** Prevalence and Distribution of Sarcocystis spp. Cysts in Several Muscles of Cattle Slaughtered in Sicily, Southern Italy. *Food Control.* 2011; 22:105-108.
- Dubey JP, Speer CA., Fayer R.** Sarcocystosis of Animals and Man. CRC Press, Boca Raton, Florida. 1989.
- El-Dakhly KM, El-Nesr KA, El-Nahass el-S, Hirata A, Sakai H, Yanai T.** Prevalence and Distribution Patterns of Sarcocystis spp. in Buffaloes in Beni-Suef, Egypt. *Trop Anim Health Prod.* 2011; 43(8):1549-1554.
- Dubey JP, Lindsay DS.** Neosporosis, Toxoplasmosis, and Sarcocystosis in Ruminants. *Vet Clin North Am Food Anim Pract.* 2006; 22(3):645-671.
- Ono M, Ohsumi T.** Prevalence of Sarcocystis spp. cysts in Japanese and Imported Beef (Loin: Musculus longissimus). *Parasitol Int.* 1999; 48(1):91-94.
- Valentine BA, McGavin MD.** Skeletal System, In: *Pathologic Basis of Veterinary Disease*, Eds: McGavin MD, Zachary, J.F. 4nd Ed., Mosby-Elsevier St. Louis, Missouri. 2007; pp:973-1039.
- Foster RA.** Male Reproductive System, In: *Pathologic Basis of Veterinary Disease*, Eds: McGavin MD, Zachary, J.F. 4nd Ed., Mosby-Elsevier St. Louis, Missouri. 2007; pp:1317-1348.
- Keleş, H.** Pathological studies on inflammatory changes of testes and epididymides from bulls slaughtered in the region of Van. MSc Thesis, Yuzuncu Yil University Health Sciences Institute, Van, 2002.