

Journal of Surgery and Medicine

Clinical characteristics and results of laser peripheral iridotomy of pigment dispersion syndrome

Pigment dispersiyon sendromlu olgularımızda klinik bulgular ve laser periferik iridotomi sonuçları

Şerife Bayraktar¹, Selen Çağman¹, Belgin İzgi¹, Gülhan Orekiçi Temel²

¹ Istanbul University, Istanbul Faculty of Medicine, Department of Ophthalmology, Istanbul, Turkey

² Mersin University, Department of Biostatistics, Mersin, Turkey

Abstract

Aim: To report the clinical findings, characteristics and the results of peripheral laser iridotomy in pigment dispersion syndrome (PDS) patients.

Methods: Medical records of 30 patients who had been diagnosed with PDS were evaluated retrospectively at Glaucoma Department of Istanbul Faculty of Medicine at Istanbul University. Sixty eyes of these 30 patients enrolled in the study.

Results: Eighteen of them (60%) were male and 12 (40%) were female with mean age of 42.4 ±12.3 years (range: 22 to 73 years). Forty-six eyes of the 23 patients had myopia, 12 eyes of six patients had hyperopia, and two eyes of one patient had emmetropia. All patients except two eyes of the one patient had (96.6%) Krukenberg spindles. Homogeneous trabecular meshwork (TM) pigmentation was seen in all patients. Thirty-two eyes of 17 patients (53.3%) had iris trans-illumination defects. Neodymium:yttrium–aluminum–garnet (Nd:YAG) peripheral laser iridotomy was performed in 44 eyes of 60 eyes (73.3%).

Conclusion: The most common clinical findings in Turkish PDS patients were Krukenberg spindles and homogeneous TM pigmentation. If PDS hasn't advanced in pigmentary ocular hypertension or pigmentary glaucoma, progression can be stabilized by laser iridotomy and medical treatment.

Keywords: Glaucoma, Pigment dispersion syndrome, Peripheral laser iridotomy

Öz

Amaç: Pigment dispersiyon sendromlu (PDS) olgularımızda klinik bulguları ve laser periferik iridotomi sonuçlarımızı bildirmek

Materyal ve Metod: İstanbul Üniversitesi İstanbul Tıp Fakültesi Glaucoma departmanında PDS tanısı alan 30 olgunun tıbbi kayıtları retrospektif olarak incelendi. Çalışmaya 30 olgunun 60 gözü dahil edildi.

Bulgular: Olguların 18'i (%60) erkek, 12'si (%40) kadındı. Ortalama yaş 42,4 ±12,3 yıld (22-73). 23 olgunun 46 gözünde miyopi, altı olgunun 12 gözünde hipermetropi ve bir olgunun iki gözünde emetropi mevcuttu. 29 olgunun her iki gözünde de (%96,6) Krukenberg mekiği izlendi. Trabeküler ağda homojen pigmentasyon tüm olgularda görüldü. On yedi olgunun 22 gözünde (%53,3) iris transilüminasyon defektleri vardı. Neodymium:yttrium–aluminum–garnet (Nd:YAG) laser periferik iridotomi 44 göze (%73,3) uygulandı.

Sonuçlar: Olgularımızda en sık rastlanan klinik bulgular Krukenberg mekiği ve trabeküler ağda homojen pigmentasyondur. Pigment dispersiyon sendromu pigmenter oküler hipertansiyona ve pigmenter glokoma ilerlemedikçe periferik ND yag laser iridotomi ve medikal tedavi ile kontrol altına alınabilir.

Anahtar kelimeler: Glaucoma, Pigment dispersiyon sendromu, Laser periferik iridotomi

Corresponding author / Sorumlu yazar:

Şerife Bayraktar

Address / Adres: İstanbul Üniversitesi İstanbul Tıp Fakültesi, Göz Hastalıkları Kliniği, 34390

Çapa / İstanbul / Türkiye

E-mail: serifecanturk@yahoo.com

Ethics Committee Approval: Ethics committee approval was received from local ethic committee.

Etik Kurul Onayı: Çalışma için lokal etik kuruldan etik kurul onayı alınmıştır.

Informed Consent: Informed consent was not received because the study design was retrospective.

Hasta Onamı: Çalışmanın retrospektif olması nedeniyle hasta onamı alınmamıştır.

Conflict of Interest: No conflict of interest was declared by the authors.

Çıkar Çatışması: Yazarlar çıkar çatışması bildirmemişlerdir.

Financial Disclosure: The authors declared that this study has received no financial support. Finansal Destek: Yazarlar bu çalışma için finansal destek almadıklarını beyan etmişlerdir.

Received / Geliş Tarihi: 01.10.2017

Accepted / Kabul Tarihi: 09.12.2017

Published / Yayın Tarihi: 10.12.2017

Copyright © JOSAM



Introduction

Pigment dispersion syndrome (PDS) is characterized by disruption of the iris pigment epithelium by irido-zonular contact and deposition of the released pigment throughout the anterior segment of the iris [1]. Characteristic concave iris configuration has been described and it is thought to facilitate pigment release. Over time, chronic pigment release can lead to elevated intraocular pressure (IOP) and advanced pigmentary glaucoma (PG). PDS can be associated with ocular hypertension or glaucoma. Pigmentary ocular hypertension (POH) is a pigment dispersion syndrome with elevated IOP and no glaucomatous optic neuropathy. PG is glaucomatous optic neuropathy in association with PDS [2].

The classic diagnostic triad is corneal endothelial pigmentation (Krukenberg's spindle), radial mid-peripheral iris trans-illumination, and homogenous trabecular meshwork (TM) pigmentation [1]. Typically, PDS is a bilateral condition that affects young males with myopia and it is more common in Caucasian patients. PDS can also be associated with endotheliopathy, deeper anterior chamber depth, heterochromia, anisocoria, pigment deposition on the anterior or posterior lens capsule, and zonules.

In addition to findings within the anterior segment of the eye, PDS can also affect the posterior segment. Lattice retinal degeneration has been reported to be evident in PDS and PG, which is greater than what would be expected for the associated myopia [3]. Laser peripheral iridotomy (LPI), can reverse backward bowing of the iris and it might prevent pigment release. It is an effective and safe method for reducing intraocular pressure.

This study aims to report the clinical findings, characteristics, and results of using LPI to treat PDS in Turkish patients at a single center.

Material and methods

The medical records of 30 PDS patients who were diagnosed and followed at the Glaucoma Department of the Istanbul Faculty of Medicine at Istanbul University were evaluated retrospectively. The study protocol was approved by the Ethics Committee of Istanbul University, Istanbul Faculty of Medicine. The research follows the tenets of the Declaration of Helsinki. Informed consent was obtained from all participants.

All 30 patients underwent detailed ophthalmic examinations, including family history, systemic and ocular history, laterality, visual acuity, and central corneal thickness, number of topical medication, IOP measurement (Goldman applanation tonometry), refraction, spherical equivalent power, slit-lamp biomicroscopy, gonioscopy, and detailed funduscopic examination. The Humphrey Automated (Carl Zeiss Meditec, Dublin, CA, USA) Swedish Interactive Threshold Algorithm (SITA) standard 30-2 visual field test results, the Heidelberg Retinal Tomography 3 (Heidelberg Engineering, GmbH, Dossenheim, Germany) results, and the retinal nerve fiber layer analysis results (Spectralis OCT, Heidelberg Engineering) of each patient were also recorded. TM pigmentation was evaluated by physicians experienced in diagnosing glaucoma using gonioscopy.

Diagnostic criteria for PDS include at least two of the following three signs: Krukenberg's spindle, homogenous TM pigmentation, and iris trans-illumination defects. Patients with a history of uveitis, trauma, or previous laser or ocular surgery were excluded.

LPI was performed on the PDS eyes at the 10 or 2-o'clock meridian with 3 mJ energy using an Abraham contact lens. All of the LPIs were performed by two physicians (SB, BI). After undergoing LPI, the patients were treated topically with corticosteroids three times daily for one week.

SPSS software (version 11.5; SPSS Inc. Champaign, IL, USA) was used for statistical analysis, which included the Shapiro Wilk test, the paired sample t-test, the Wilcoxon signed-rank test, and the Kruskal-Wallis test. $p < 0.05$ was considered to be statistically significant.

Results

Thirty patients (60 eyes) were evaluated in the study. Eighteen (60%) of the 30 patients were male and 12 (40%) were female. Four patients had been referred to our clinic with a misdiagnosis of uveitis. Fifteen patients had already been diagnosed with glaucoma at other centers. Seven patients had visual problems and three had complaints of redness. Two patients were diagnosed during the routine examination.

The mean age of the patients was 42.4 ± 12.3 years (range: 22–73 years). The average age for the male and female patients was 41.8 ± 14.7 (range: 22–73) and 43.2 ± 7.8 (range: 27–56 years), respectively. The male-to-female ratio was 3:2. Six of the patients had a family history of glaucoma. None of the patients had a family history of PDS or PG. Twenty-three patients (46 eyes) had myopia of -0.5 D or greater, with a mean refractive error of -1.7 ± 1.1 D spherical equivalent dioptres (range: -0.50 – 6.0 D). Five patients (10 eyes) had hyperopia with a mean refractive error of 1.0 ± 0.3 D spherical equivalent dioptres (range: 0.50 – 1.50 D), and two patients (four eyes) had emmetropia.

Most of the patients (96.6%) had Krukenberg's spindle (as seen in Figure 1a), which were bilateral; one patient (two eyes) did not have that condition. The gonioscopy results showed that the eyes in all 30 patients (100%) had homogeneous TM pigmentation (as seen in Figure 1b). Seventeen patients (53.3%; 32 eyes) had iris trans-illumination defects (as seen in Figure 2), and these were found to be bilateral in 15 patients and unilateral in two patients. One patient (3.3%) had heterochromia, two patients (5%; three eyes) had pigment granule dusting on the anterior lens surface. None of the patients had anisocoria. After reviewing the fundus examination results, five eyes (8.3%) were found to have peripheral lattice degeneration. Vitreoretinal surgery was performed due to the development of retinal detachment in two eyes (3.3%).

The average central corneal thickness was 537 ± 35.2 μ m (range: 481–617 μ m) Best-corrected visual acuity (BCVA) of the all participants at first examination was 0.02 ± 0.19 logMAR. The initial average intraocular pressure was 19.3 ± 6.9 mmHg and the patients were using an average of 0.4 ± 0.7 topical medications at the time of their first visit. At the final visit in all patients, the mean intraocular pressure was 14.7 ± 2.6 mmHg with an average of 1.3 ± 1.3 medications.

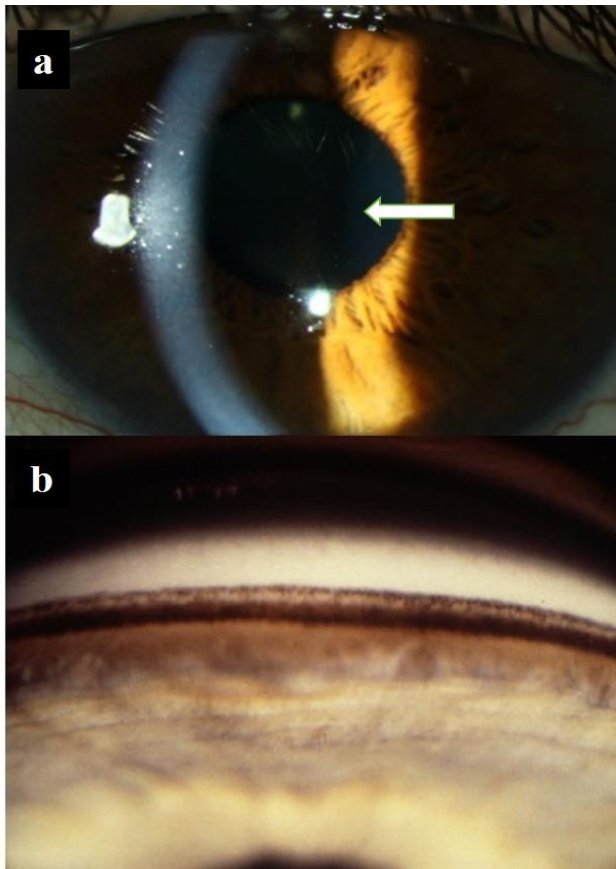


Figure 1: (a) Slit-lamp photo of the left eye. Arrow shows Krukenberg spindle. (b) Homogeneous TM pigmentation

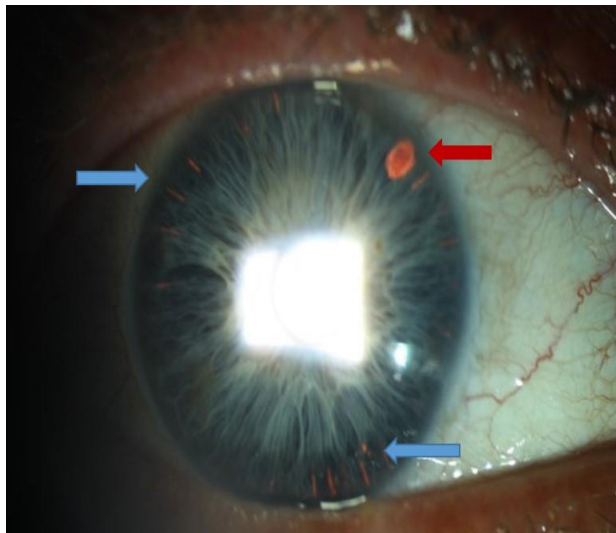


Figure 2: Anterior segment photo of the right eye of a patient. Blue arrows show iris trans-illumination defects, red arrow shows the peripheral laser iridotomy

LPIs were performed in 44 of the 60 eyes (73.3%). Three patients (three eyes) underwent trabeculectomy due to high IOP (>30 mmHg) with the maximum amount of antiglaucomatous medication. Seven patients (13 eyes) that were supposed to receive the laser treatment declined to undergo it.

For the peripheral laser treatment group, the mean intraocular pressure and the average number of medications at the first visit was 20.2 ± 7 mmHg and 0.38 ± 0.68 , respectively. At the last visit, the mean intraocular pressure and the average number of medications in that group was 14.8 ± 2.8 mmHg ($p < 0.001$) and 1.5 ± 1.5 ($p < 0.001$), respectively. The C/D ratios and the retinal nerve fiber layer (RNFL) thickness measurement of these patients before treatment were 0.43 ± 0.18 and

$85.8 \pm 19.2 \mu$, respectively; after treatment the C/D ratios and RNFL measurements were 0.5 ± 0.2 ($p = 0.002$) and $84.6 \pm 19.5 \mu$ ($p = 0.048$), respectively.

Twenty-one eyes were classified as PDS, 15 eyes as POH, and 24 eyes as PG. LPIs were performed in 14 of the 21 PDS eyes. The mean IOP and the average number of medications at the first visit in the PDS group before LPI were 17.5 ± 1.5 mmHg and 0, respectively. At the last visit after LPI, the mean IOP and the average number of medications were 15.1 ± 2.6 mmHg ($p < 0.05$) and 0.8 ± 1.1 ($p < 0.05$), respectively. Eight of those eyes (57%) continued without topical medication after the LPI procedure. The C/D ratios and RNFL thickness measurements of those patients before treatment were 0.36 ± 0.18 and $97.86 \pm 7.07 \mu$, respectively. After treatment the C/D ratios and RNFL measurements were 0.36 ± 0.18 ($p = 0.88$) and $97.93 \pm 6.40 \mu$ ($p = 0.97$), respectively. Five eyes (36%) progressed to POH and one eye (7%) progressed to PG. Seven of the PDS eyes did undergo LPI. Three (43%) of those seven eyes progressed to POH and four (57%) of the seven eyes did not.

In the POH cases, 11 eyes underwent LPI; one eye progressed to PG and two eyes regressed to PDS. In the POH group, the mean IOP and the average number of medications at the first visit before LPI were 22.2 ± 7.8 mmHg and 0.9 ± 0.9 , respectively. At the last visit after LPI, the mean IOP and the average number of medications were 14 ± 2.9 mmHg ($p = 0.06$) and 1.18 ± 1 ($p = 0.77$), respectively. The C/D ratios and the RNFL thickness measurements of these patients before treatment were 0.40 ± 0.15 and $97.45 \pm 9.60 \mu$, respectively; after treatment they were 0.54 ± 0.22 ($p < 0.05$) and $95.27 \pm 10.15 \mu$ ($p < 0.05$), respectively. No progression to PG was observed in four eyes that did not undergo LPI; moreover, IOP had been controlled with topical medications.

Nineteen of the 24 PG eyes underwent LPI treatment. In this PG group, the mean IOP and the average number of medications at the first visit before LPI were 21.1 ± 8.6 mmHg and 0.3 ± 0.5 , respectively. At the last visit after LPI, those values were 15.2 ± 2.9 mmHg ($p < 0.05$) and 2.3 ± 1.6 ($p < 0.001$), respectively. The C/D ratios and the RNFL thickness measurements of these patients before treatment were 0.51 ± 0.19 and $70.32 \pm 18.8 \mu$, respectively; after treatment those values were 0.59 ± 0.18 ($p < 0.001$) and $68.74 \pm 18.88 \mu$ ($p = 0.059$), respectively. The mean follow-up period was 69.7 ± 57.7 months (range: 3–168 m). The LPI results are summarized in Table 1.

Discussion

Sugar and Barbour first described pigmentary glaucoma in 1949 in their report of two patients with marked trabecular meshwork pigmentation, iris trans-illumination defects, and elevated intraocular pressure.⁴ These findings were later described to be secondary to a posterior bowing of the concave iris figuration and increased pigment dispersion from iridozonular contact [5,6].

Studies have shown that 4–21% of PDS patients have a family history of glaucoma [7,8]. Our cases showed a 20% family history of glaucoma, and none of the patients had a family history of PDS or PG. Several conditions, including pseudoexfoliation syndrome, uveitis, intraocular surgery, and

Table 1: Results of the laser peripheral iridotomy

	IOP (mmHg)	No. of medication	C/D ratio (HRT)	RNFL thickness (μ)
PDS (before)	17.5 \pm 1.5	0	0.35 \pm 0.18	97.8 \pm 7.06
PDS (after)	15.1 \pm 2.6	0.8 \pm 1.1	0.36 \pm 0.17	97.9 \pm 6.4
p	0.023	0.026	0.888	0.970
POH (before)	22.2 \pm 7.8	0.9 \pm 0.9	0.4 \pm 0.1	97.4 \pm 9.5
POH (after)	14 \pm 2.9	1.18 \pm 1	0.53 \pm 0.2	95.2 \pm 10.1
p	0.06	0.744	0.023	0.018
PG (before)	21.1 \pm 8.6	0.3 \pm 0.5	0.5 \pm 0.18	70.3 \pm 18.7
PG (after)	15.2 \pm 2.9	2.3 \pm 1.6	0.59 \pm 0.18	68.7 \pm 18.8
p	0.017	0.001	<0.001	0.059
All of LPI (before)	20.2 \pm 7	0.38 \pm 0.68	0.43 \pm 0.18	85.8 \pm 19.2
All of LPI (after)	14.8 \pm 2.8	1.5 \pm 1.5	0.5 \pm 0.2	84.6 \pm 19.5
p	<0.001	<0.001	0.002	0.048

trauma, have characteristics that are similar to PDS. Iris transillumination defects are not always present in PDS eyes, but they are present in most (86%) PDS cases and these defects are more obvious in light-colored eyes [8].

Tugal-Tutkun et al. [9] described Bilateral Acute Depigmentation of the Iris (BADI), which is an acute onset of bilateral pigment dispersion in the anterior chamber, depigmentation and discoloration of the iris stroma, and pigment deposition in the trabecular meshwork. This condition was initially mistaken for pigment dispersion syndrome. Patients with a diagnosis of BADI do not have the other characteristic features of pigment dispersion syndrome, including pigment deposition on the surface of the lens, zonules, iris stroma, iris concavity, or mid-peripheral trans-illumination defects in a spoke-like pattern. Therefore, it is important not to misdiagnose PDS patients with a normal IOP as having BADI.

Ocular hypertension or pigmentary glaucoma develops over a number of years in PDS, whereas the increase in IOP occurs within weeks or months in Bilateral Acute Iris Transillumination (BAIT), which is a condition in which bilateral acute iris trans-illumination develops in association with pigment showering and persistent mydriasis [8]. Compromised pupillary constriction to light was thought to be related to variable amounts of sphincter paralysis in BAIT [10]. Pupillary reactions to light and near stimuli are not affected in PDS [11,12].

In PDS, iris trans-illumination defects are commonly located in the mid-peripheral iris and with a spoke-like pattern [13]. The incidence of iris trans-illumination defects in our study was 53% and most of them were observed to have a spoke-like pattern.

The characteristic gonioscopic feature of PDS is increased homogenous TM pigmentation contrast to the patchy pigmentation in pseudo-exfoliation syndrome [14-16]. We observed TM pigmentation in all of our patients. Although some sources have said that Krukenberg's spindle is not seen in all patients, it was observed in 96.6% of the patients in our study [17].

Heterochromia may be observed in asymmetric patients, with the affected eye having a darker iris as a result of the deposition of pigment onto the anterior surface of the iris [14-18]. In our cases, only one patient had heterochromia (3.3%).

PDS can affect the posterior segment. Lattice retinal degeneration has been reported to occur in 20–33% of cases of PDS and PG, which is greater than would be expected for the associated myopia [2, 19]. Retinal detachments have been reported to occur in 5.5–6.6% of PDS cases; again this is higher than the expected for the degree of myopia [15,20,21]. However, in our study peripheral lattice degeneration was present in five eyes (8%) and retinal detachment was present in two eyes (3%), requiring vitreoretinal surgery. Similar results were seen in the published studies.

In 1992, Karickhoff [6] suggested that LPI may be a potential treatment for PG. He postulated that LPI may relieve the posterior bowing of the peripheral iris by equalizing the pressure in the anterior and posterior chambers. LPI has been advocated as a means to correct peripheral iris bowing from reverse pupillary block. Gandolfi and Vecchishow that the use of Nd:YAG LPI reduced the incidence of POH in a randomized control trial of 21 patients [22]. In a retrospective study, Reistad et al. could not provide evidence to support the benefit of LPI in the long-term IOP control of patients with PG [23]. In our study, we observed a statistically significant decrease of IOP in the PDS cases that underwent LPI, although the PDS eyes required more medication. Despite this, the C/D ratios and the RNFL thickness did not deteriorate during the follow-up period. In the POH cases, IOP decreased after LPI but that decrease was not statistically significant. However, during the follow-up period the increase in the C/D ratios and the thinning of RNFL thickness were statistically significant in these cases. In the PG eyes, IOP was under control; however, it is difficult to say that this was due to LPI because these PG eyes also needed more medication and other treatment modalities.

Consequently, homogeneous trabecular meshwork pigmentation was the most common clinical finding in our 30 patients (100%), followed by Krukenberg's spindle (96.6%) and then iris trans-illumination defects (53.3%). In addition to the anterior segment findings, it is important to use funduscopy examinations in order to ensure that retinal pathologies are identified.

This study's findings suggest that if pigment dispersion syndrome hasn't advanced to pigmentary ocular hypertension or pigmentary glaucoma, its progression can be stabilized by laser peripheral iridotomy and medical treatment.

References

1. Fine BS, Yanoff M, Sheie HG. Pigmentary "glaucoma": A histologic study. *Trans Am Acad. Ophthalmol Otolaryngol.*1974; 7:314-325.
2. Niyadurupola N, Broadway DC. Pigment dispersion syndrome and pigmentary glaucoma-a major review. *Clinic Experiment Ophthalmol*2008; 36: 868–82.
3. Scuderi G, Papale A, Nucci C, Cerulli L. Retinal involvement in pigment dispersion syndrome. *IntOphthalmol*1996; 19: 375–378.
4. Sugar HS, Barbour FA. Pigmentary glaucoma; a rare clinical entity. *Am J Ophthalmol.* 1949; 32:90–92.
5. Campbell DG. Pigmentary dispersion and glaucoma. A new theory. *Arch Ophthalmol.* 1979; 97:1667–1672.
6. Karickhoff JR. Pigmentary dispersion syndrome and pigmentary glaucoma: a new mechanism concept, a new treatment, and a new technique. *Ophthalmic Surg.* 1992; 23:269–277.
7. Gillies WE. Pigmentary glaucoma: a clinical review of anterior segment pigment dispersal syndrome. *Aust NZ J Ophthalmol* 1985; 13: 325–328.
8. Siddiqui Y, Ten Hulzen RD, Cameron JD, Hodge DO, Johnson DH. What is the risk of developing pigmentary glaucoma from pigment dispersion syndrome? *Am J Ophthalmol*2003; 135: 794–799.
9. Tugal-Tutkun I, Araz B, Taskapili M, Akova YA, Yalniz-Akkaya Z, Berker N, Emre S, Gezer A. Bilateral Acute Depigmentation of the Iris: Report of 26 New Cases and Four-year Follow-up of Two Patients. *Ophthalmology* 2009; 116:1552–1557.
10. Tugal-Tutkun I, Onal S, Garip A, Taskapili M, Kazokoglu H, Kadayifcilar S, Kestelyn P. Bilateral Acute Iris Transillumination. *Arch Ophthalmol* 2011; 129:1312-1319.
11. Feibel RM, Perlmutter JC. Anisocoria in the pigmentary dispersion syndrome. *Am J Ophthalmol.* 1990; 110:657-660.
12. Feibel RM. Anisocoria in the pigmentary dispersion syndrome: further cases. *J Glaucoma.* 1993; 2:37-38.
13. Campbell DG. Pigmentary dispersion and glaucoma: a new theory. *Arch Ophthalmol*1979; 97: 1667–1672.
14. Sugar HS. Pigmentary glaucoma: a 25-year review. *Am J Ophthalmol*1966; 62: 499– 507.
15. Scheie HG, Cameron JD. Pigment dispersion syndrome: a clinical study. *Br J Ophthalmol*1981; 65: 264–269.
16. Prince AM, Ritch R. Clinical signs of the pseudoexfoliation syndrome. *Ophthalmology* 1986; 93: 803–807.
17. Wilensky JT, Buerk KM, Podos SM. Krukenberg's spindles. *Am J Ophthalmol*1975; 79: 220–225.
18. Sugar S. Pigmentary glaucoma and the glaucoma associated with the exfoliation-pseudoexfoliation syndrome: update. *Ophthalmology* 1984; 91: 307–310.
19. Weseley P, Liebmann J, Walsh JB, Ritch R. Lattice degeneration of the retina and the pigment dispersion syndrome. *Am JOphthalmol*1992; 114: 539– 43.
20. Ritch R. A unification hypothesis of pigment dispersion syndrome. *Trans Am Ophthalmol Soc*1996; 94: 381–409.
21. Farrar SM, Shields MB. Current concepts in pigmentary glaucoma. *Surv Ophthalmol*1993; 37: 233–252.
22. Gandolfi SA, Vecchi M. Effect of a YAG laser iridotomy on intraocular pressure in pigment dispersion syndrome. *Ophthalmology* 1996; 103:1693–1695.
23. Reistad CE, Shields MB, Campbell DG, Ritch R, Wang JC, Wand M: American Glaucoma Society Pigmentary Glaucoma Iridotomy Study Group. The influence of peripheral iridotomy on the intraocular pressure course in patients with pigmentary glaucoma. *J Glaucoma* 2005; 14:255–259.