



This work is licensed under a Creative Commons Attribution-NonCommercial 4.0 International License



Evaluation of Damaged Brain Area and Correlation of Them with Clinical Symptoms in Brain Surgery

Beyin Cerrahisinde Hasarlı Beyin Bölgesinin Değerlendirilmesi ve Hasarlı Alanların Klinik Belirtilerle İlişkisi

Veli Çıtışlı ¹

¹ Department of Neurosurgery Pamukkale University Medical Faculty, Denizli, Turkey

Aim: Previous postmortem studies have shown the relationship between the ischemic brain area and clinical symptoms in patients. This study aims to evaluate ischemic brain area images obtained with magnetic resonance (MR) and computational tomography (CT) and correlate them with patients' clinical symptoms.

Material And Methods: For this purpose, images obtained were evaluated and results were correlated with reported clinical findings of patients. A significant correlation has already been detected between damaged areas and clinical symptoms. Damaged areas in the brain can be detected by cranial imaging methods. At the same time, the localization of ischemic areas can be designated through neurological examination. So far, many functional brain areas have been investigated in this way. However, this determination was usually made in postmortem cases.

Results: In the present study, the correlation between evaluated images and clinical symptoms was made for the first time.

Conclusions: The present study results can be a reference point for the computational neuroscience related to brain surgery. It can also provide authentic opportunities for new research in the clinical and basic sciences

Keywords: Brain ischemia; magnetic resonance imaging; computational tomography; neurosurgery; symptoms; computational neuroscience

Amaç: İskemik hasar görmüş beyin bölgesi ile hastalardaki klinik semptomlar arasındaki ilişki daha önceki postmortem çalışmalarda gösterilmiş ancak canlı olarak gösterilmemiştir. Çalışmanın amacı hastanın manyetik rezonans (MR) ve bilgisayarlı tomografi (BT) görüntülerinden elde edilen iskemik hasarlı beyin alanlarını değerlendirmek ve bunların hastaların klinik semptomlarıyla ilişkilendirilmesidir.

Gereç ve Yöntemler: Bu amaçla hastaların görüntüleri değerlendirildi ve sonuçlar hastaların bildirilen klinik bulgularıyla ilişkilendirildi. Hasarlı alanlar ile klinik semptomlar arasında önemli ölçüde korelasyon zaten tespit edilmiştir. Yapılan kranial görüntüleme yöntemleriyle beyindeki hasarlı alanlar tespit edilebilmektedir. Aynı zamanda nörolojik muayene ile iskemik bölgelerin lokalizasyonu da yapılabilmektedir. Bugüne kadar pek çok işlevsel beyin alanı bu yolla incelenmiştir. Ancak bu tespit genellikle postmortem vakalarda yapılyordu.

Bulgular: Bu çalışmada ilk kez görüntülerin değerlendirilmesi ile klinik belirtiler arasındaki ilişki araştırıldı.

Sonuç: Mevcut çalışma sonuçları beyin cerrahisi ile ilgili hesaplamalı sinirbilime kaynak olabilir. Klinik ve temel bilimlerde yeni araştırmaların önünü açabilir

Anahtar kelimeler: Beyin iskemisi; manyetik rezonans; bilgisayarlı tomografi; nöroşirurji; semptomlar; bilgisayarlı sinirbilim

INTRODUCTION

The brain systematically controls neuronal networks. It is divided into three main sub-units; the brain stem, the cerebellum, and the cerebrum. However, each point on the brain has a different function on this foretold control. Body functions might be impaired by the involvement of the different areas in the brain due to various diseases. One of them is stroke. Stroke includes all impairments that might affect any brain region temporarily or permanently by ischemia or hemorrhage that is at the end of corrupt blood vessels feeding the brain because of pathological processes (Asspland 1994, Biousse 2007, Goldstein 2011). Brain infarction in any part of the brain, depending on the regional anatomical and physiological characteristics of the human body, causes a failure in the body function. Detailed examination of infarcted brain area by advanced medical imaging methods and then making the correlation between results and neurological symptoms will provide new information about not only the mechanism of the disease but also the associated one with brain anatomy and function (Blit 1999, Williams 1989). Imaging is widely used today in medicine. (Treleas 2002). Especially the development of radiological imaging techniques in medicine and being integrated with the 3D technology will enable the production of more new programs. Our goal is to damage ischemia patients correlated with clinical findings.

MATERIAL AND METHODS

Hundred-five patients under consideration and treatment due to acute ischemic CVD (Cerebro Vascular Disease) diagnosed in our neurology clinic and 50 healthy volunteers were enrolled in the study (Table 1).

	n	%
Patient group-Male	53	34.2
Patient group-Female	52	33.5
Control group-Male	23	14.8
Control group-Female	27	17.4
Total	155	100.0

Table 1. Patient numbers

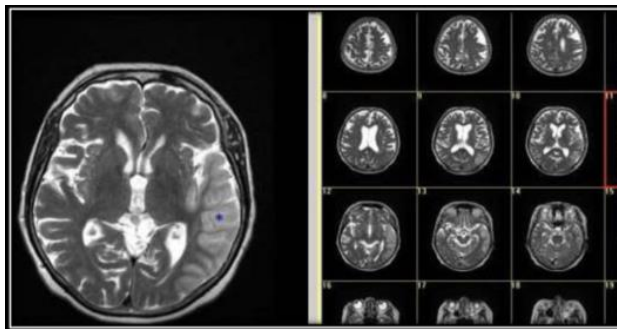
The study was approved by our university ethics committee, and informed consent was obtained from participants. Patients who had pre-recognized renal, hepatic, hematological, or infectious diseases or malignancies were excluded from the study. Risk factors for CVD including hypertension (HT), hyperlipidemia, diabetes, atrial fibrillation (AF), and cardiac diseases were recorded as well (Murray 2013). Patients were divided into 5 etiologies according to TOAST (Trial of Org. 10172 in Acute Stroke Treatment) classification: Large artery atherosclerosis; cardioembolism; lacunar infarct; other identifiable etiologies; and stroke of undetermined etiology (cryptogenic) (Adam 1993, Bamford 1991, Goldstein 2001).

Standard protocols were administered to all patients, including radiologic and laboratory evaluations such as cranial imaging (Figure 1) (Kleinderfer 2015). To determine the severity of CVD in patients, the 1st and 14th days of ischemic CVD were evaluated with NIHSS (The National Institute of Health Stroke Scale) depending on neurologic examinations (Adams 1999).

Diffusion magnetic resonance imaging (MRI) was used to calculate infarct volume. MRI evaluation was obtained using a 1.5 Tesla superconductive magnet (*Signa Excite HD, GE Healthcare, Milwaukee, WI, USA*).

Infarct area related to the arterial supply

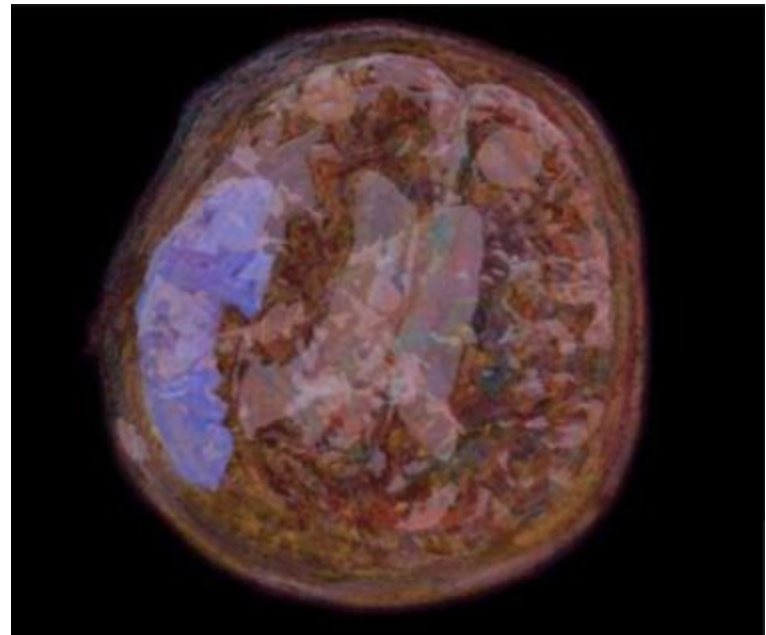
Surf Driver 3.5 is a program used to create Three-dimensional (3D) images of organs and modals in animations and virtual reality (Trelease 2002, Reidenberg 2002). In volume calculation of ischemic areas, the calculation made with this program was verified. Images obtained in MRI with Surf Driver 3.5 were called in software and infarct areas were marked (Figure 1).



MR: Magnetic resonance

Figure 1. MR images of patient with ischemia

Images were then reconstructed automatically by the program and their volumes were calculated (Figure 2).



3D: three-dimensional

Figure 2. 3D demonstration of the relationship between infarct and all brain structures (Area colored with blue is infarct area)

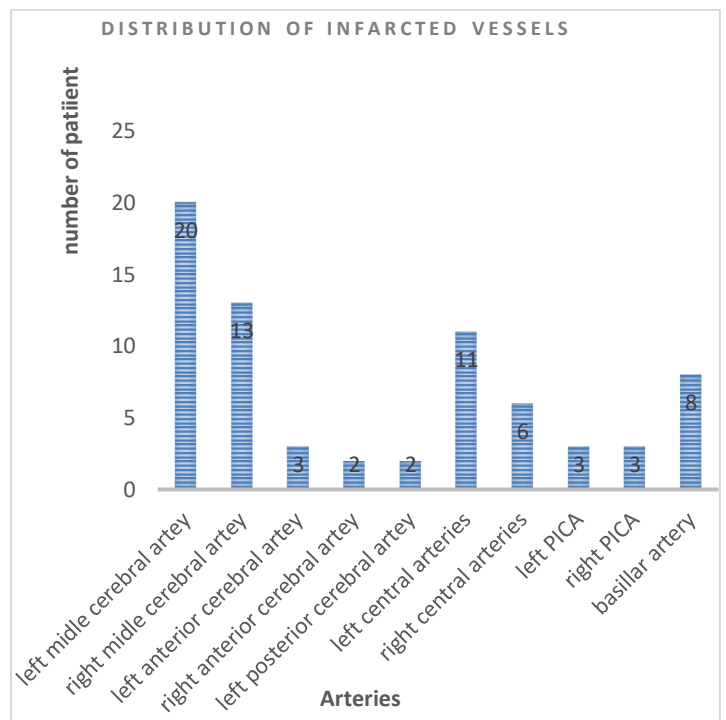


Figure 3. Distribution of infarcted vessels

between variables.

However, 3D images are more advantageous as they provide a 3D view of the ischemic spread.

At the same time, according to the ischemic brain damaged area, the responsible artery is noted. There were 11 responsible different arteries due to the infarct area (Table 2).

Finally, ischemic CVD was evaluated with NIHSS (The National Institute of Health Stroke Scale) depending on neurologic examinations. Then, the results were correlated with arteries related to the infarct area (Table 3).

Table 2. Responsible different arteries due to infarct area

	Normal (No CVD)
1	Normal (No CVD)
2	Left middle cerebral artery
3	right middle cerebral artery
4	Left anterior cerebral artery
5	right anterior cerebral artery
6	Left posterior cerebral artery
7	right posterior cerebral artery
8	Left central arteries
9	right central arteries
10	Left posterior inferior cerebellar arte
11	Left posterior inferior cerebellar arte
12	Basillar artery

CVD; cerebrovascular disease

Statistical Analysis

Data were evaluated with the SPSS 17.0 statistic program. Descriptive statistics relating to the patient and control groups were reported. Continuous variables (mean±standard deviation), minimum and maximum values, and categorical variables were indicated in numbers and percentages. For the comparison of intergroup differences, the Mann-Whitney *U* test and Kruskal Wallis variance analysis were used. The chi-square test was used to compare categorical variables and Pearson's correlation analysis was used to evaluate the correlation

Table 3. NIHSS – (National Health Stroke Scale) was correlated with 11 different arteries that each supply the unique brain region. Given numbers shows the number of patients in any responsible artery with symptoms on NIHSS.

Code	1	2	3	4	5	6	7	8	9	10	11	12
A	10	14	9	3	2	2	6	4	3	3	7	
B	4	1					5	2			1	
C	2											
D	1	1										
E	10	12	8	2	2	2	7	5	3	2	6	
F	4	4					4	1		1	1	
G	3	1	1								1	
H	10	16	5	3	1	2	9	6	1	2	7	
I	2									2	1	1
J	3	6					2					
K	10	17	11	2	1	1	11	6	3	2	8	
L	1				1	1						
M	1	2	1								1	
N	1											
O	8	8	4	2	1	1	5	1	1	2	5	
P	2	4	1		1	1	1	2	1	1	1	
Q	6	8	1				5	3	1		2	
R	1											
S	9	9	10	1	2	2	3	5	3	1	7	
T	1	8	1				6	1		2	1	
U	2	1	2				3					
V	1						1					
W	9	17	1	3	1	1	10	2	1	3	3	
X	1	1	4		1	1	1	2			4	
Y	1	6					2				1	
Z	2											
AA	8	18	12	3	2	2	10	6		2	7	
AB	1	1	1				1		2		1	
AC	1									1	1	
AD	6	12	7	1	1	2	4	2	3	2	5	
AE	4	6	6	2	1		7	4		1	3	
AF	1											
AG	10	18	10	3	2	2	11	6	3	3	8	
AH	3											
AI	1											
AJ	7	11	6	2	1	1	7	4	1	1	5	
AK	2	7	6	1	1	1	3	2	2	1	3	
AL	1	1	1				1			1		
AM	10	7	9	3	2	1	10	5	3	3	7	
AN	4	3								1		
AO	4	1			1	1					1	
AP	4											

Level of consciousness (A)
Orientation (Ask month and age) (B)
Horizontal extraocular movements (C)
Visual field (D)
Facial palsy (E)
Right arm motor drift (F)
Left arm motor drift (G)
Limb Ataxia (H)
Sensory (I)
Extinction and Inattention (formerly Neglect)(J)
Dysarthria(K)
Best Language(L)
responsible arteries due to infarct area
1 Normal (no CVD)
2 Left middle cerebral artery
3 right middle cerebral artery
4 Left anterior cerebral artery
5 right anterior cerebral artery
6 Left posterior cerebral artery
7 right posterior cerebral artery
8 Left central arteries
9 right central arteries
10 Left posterior inferior cerebellar artery (PICA)
11 Left posterior inferior cerebellar artery (PICA)
12 Basillar artery
CVD; cerebrovascular disease

RESULTS

Clinical and demographic characteristics

A total of 105 consecutive patients and 50 healthy controls ≥18 years old were included in this study. The mean ages of the patients and control group were 68.1±13.2 (22-82) and 62.4±18.0 (21-83) (Table 1). The CVD sub-types were as follows: Atherosclerotic 30 (28.6%); cardioembolic 46 (43.8%); lacunar infarct 14 (13.3%); other etiologies 2 (1.9%) (1 vascular and 1 dissection); and undetermined (cryptogenic) 3 (2.9%). Ten patients (9.5%) without infarction were included in the transient ischemic attack

(TIA) group.

Distribution of infarcted vessels

The most infarcted artery was the left middle cerebral artery (in 20 patients). The following one was the right middle cerebral artery (in 13 patients). Left central artery (in 11 patients), basilar artery (in 8 patients), and right central artery (in 6 patients) were the common results. Infarction of the other arteries was rare (Table 1, Figure 3)

Correlation between the NIHSS and infarcted area related to arteries

The level of consciousness was generally normal in most of the arterial infarcts. However, there were alterations in consciousness level at the infarcted area because of the left and right middle cerebral arteries, left and right central arteries, and basilar artery (Figure 3,4-6). Orientation was altered in almost all artery infarctions except anterior and posterior cerebral arteries (Figure 3-B). Horizontal extraocular movements worsened in almost all artery infarctions except posterior cerebral arteries (Figure 3-C).

A3 Responds only with reflex motor or autonomic effects, or totally unresponsive, flaccid, and areflexic

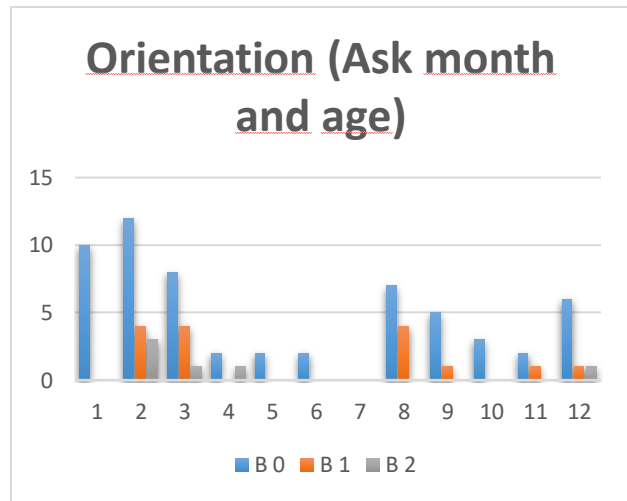


Figure 3-B Orientation

B0 Answers both questions correctly.

B1 Answers one question correctly.

B2 Answers neither question correctly

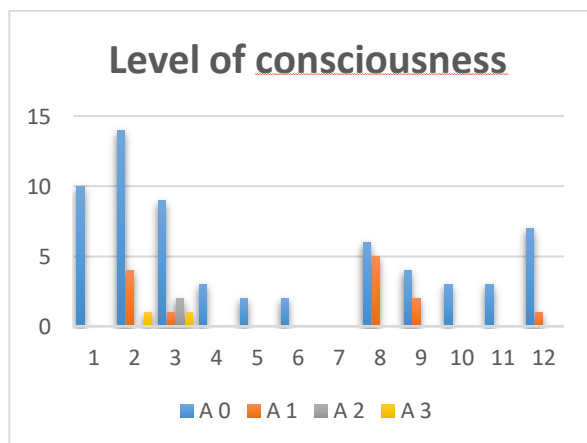


Figure 3-A Level of Consciousness

A0 Alert; keenly responsive

A1 Not alert; but arousable by minor stimulation to obey, answer, or respond

A2 Not alert; requires repeated stimulation to attend, or is obtunded and requires strong or painful stimulation to make movements (not stereotyped)

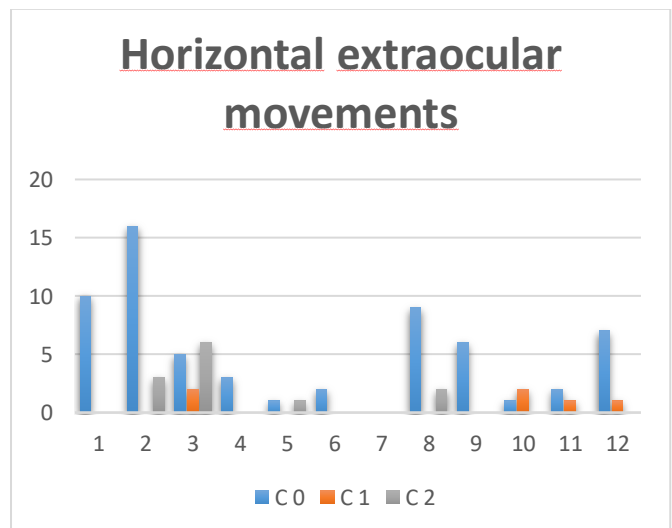


Figure 3-C Horizontal extraocular movements

C0 Normal.

C1 Partial gaze palsy; gaze is abnormal in one or both eyes, but forced deviation or total gaze paresis is not present.

C2 Forced deviation, or total gaze paresis is not overcome by the oculocephalic maneuver

DISCUSSION

The loss of brain functions sometimes sign as functional loss of any body structure. Stroke scale is for determining loss of functions due to brain functions (NIHSS - National Health Stroke Scale). This scale is accepted in the world literature (Adams 1999). We evaluated a total of 12 parameters on this scale (Table 3). In the present study, Infarct localizations were correlated with arteries that irrigate brain regions. By the way, infarct size and loss of brain function are correlated with the vessels supplying certain brain regions.

In our study, for the first time, ischemia areas in the brain were studied with 3D, and anatomical and physiological features of the brain were correlated in patients.

In this study, the arteries responsible for the infarct areas that irrigate these areas were studied in detail. The frequency of infarct formation of each artery was determined for the first time in this study. The left middle cerebral artery was the most common artery causing infarction (20%) (Figure 3). Infarction of the brain regions fed by the left middle cerebral artery causes speech impairment or spatial perception impairment compared to hemispheres that are damaged by motor function, sensory loss, and homonymous hemianopsia on the opposite side of the body. The motor and sensory cortex outside the lower extremity region is fed by the middle cerebral artery, motor function weakness and sensory loss are more pronounced in the distal part of the upper extremity and the face. In the left hemisphere of the infarction, Broca-type aphasia occurs due to the destruction of the motor speech center. In the infarct of right hemisphere, there may be spatial perception disorders such as constructional apraxia (difficulty in drawing simple pictures), topographagnosia (difficulty in interpreting a sketch or finding a path), asomatognosia in the left side (inability to detect body parts on one side), and inability to detect objects on the left

side of the midline of the body (Arıncı 1997, Arifoğlu 2016, Moore 2103, Williams 1983). In the acute phase of infarction, weakness occurs in the conjugated glance to the opposite side due to the destruction of the site of eye movements in the frontal lobe. The reason for this improvement in the 1-2 days following the acute phase is unknown.

After the left middle cerebral artery, the most deep bleeding artery is the left deep artery (10%). This was followed by right deep arteries (7%). These branches are called “central branches. These branches, which are the proximal parts of the arteries that make up the circulus arteriosus cerebria, are thin end branches and there is no anastomosis between them. These arteries feed the diencephalon, Capsula interna, basal nuclei, and formations located in the deep parts of the brain. Contralateral hemiplegia or contralateral hemianesthesia is possible only as a result of infarction of the posteromedialis of the nucleus ventralis and posterolateralis of the nucleus ventralis (Clark 2010, Williams 1983).

In our study, the third of the most common arteries involved in infarcts was the basilar artery (Figure 3); Its branches affect the brain stem.

Left and right vertebral arteries, both involvement was 6%. Right and left involvement is equal. The most clinically important branch here was the inferior posterior cerebellar artery. This artery is called PICA in the clinic. The lateral part of the medulla oblongata is fed by PICA. A sudden obstruction of the PICA or branches of this artery that feeds the lateral portion of the medulla oblongata leads to “Wallenberg syndrome”. In Wallenberg syndrome, loss of sensation of pain and heat is seen in the contralateral half of the body. Swallowing and speech difficulties. Nausea, vomiting, vertigo, and nystagmus nuclei are due to vestibular destruction. Pain and heat loss occurs on the ipsilateral half of the face. Horner syndrome develops due to the destruction of sympathetic fibers. Cerebellar ataxia can be seen. If the lesion expands, nuclei tractus solitarii and cochlear nuclei may be affected. The medial medullar syndrome develops as a

result of a sudden obstruction in the branches of the vertebral artery feeding the medial part of the medulla oblongata (Clark 2010, Williams 1983).

In our study, anterior cerebral arteries were the least responsible for cerebral lesions. However, different results were obtained from the literature in correlation with the clinic. In the literature, in the infarction of the regions fed by anterior cerebral arteries, especially in the distal part of the lower extremity, motor weakness and loss of sensation in the opposite half of the body are more pronounced in the distal part of the lower extremity. Cerebri anterior, the proximal parts of the lower extremity of the cortex associated with a. small collateral branches from cerebri media. In the infarction of the regions fed by anterior cerebral arteries, urinary incontinence may also be seen in the lobulus paracentralis due to a lesion of the bladder-related motor and sensory regions or which is thought to develop due to the lesion of the region related to inhibition of bladder emptying (Clark 2010, Williams 1983).

Contralateral homonymous hemianopsia develops in the infarction of the brain regions fed by the posterior cerebral artery due to the destruction of the occipital lobe. The obstruction of the posterior cerebral artery is located in the proximal part of the artery, and infarction is also seen in the areas fed by the central branches. In this case, loss of sensation in the contralateral body half, spontaneous pain and dysesthesia (thalamic pain syndrome) due to destruction of the thalamus; contralateral hemiparesis due to destruction of the tractus corticospinalis; contralateral ataxia due to tractus dentatothalamicus destruction; hemiballismus on the contralateral side due to damage to the nucleus subthalamicus; paralysis of the eye muscles that are innervated by this nucleus may occur due to damage to the nucleus nervi oculomotorii (Clark 2010, Williams 1983).

Infarct size caused by vessels was compared in the study for the first time in the literature. The right middle cerebral artery was the vessel causing the largest volume infarction. The left vertebral artery was followed by the right vertebral artery, then the arteries that cause the

most infarct volume together with the deep arteries (central arteries). These results will provide the basis for explaining the mechanisms of clinical findings (Figure 3).

When the consciousness level of the patients was correlated with the irrigation areas of the arteries, there was generally no loss of consciousness in left middle cerebral artery infarcts. Only 4 patients had a mild loss of consciousness. The cause of mild loss of consciousness in these patients was found to be directly proportional to the size of the infarct. Consciousness loss leading to coma has been observed with increasing infarct size. We can say that the right lobe is more sensitive to the loss of consciousness. Infarct size is also predictive of loss of consciousness. No loss of consciousness was detected in the anterior and posterior cerebral arteries infarct areas. However, there was a slight loss of consciousness in the infarcts caused by the right and left central arteries and the basilar artery. It is known that formatio reticularis is responsible for consciousness. Formatio reticularis is distributed throughout the central nervous system. ARAS (ascending reticular activating system) is controlled electrically (Clark 2010, Williams 1983). In our study, the only comatose state of consciousness was detected under middle cerebral artery infarction (Figure 3-A). Orientation; In the two command findings, the left and right middle cerebral artery were held responsible. Along with these, orientation has also been impaired during the infarction of the central arteries and the basillary arteries. Association centers were evaluated here (Clark 2010, Williams 1983). Disturbance in command orientation is evident in right and left parietofrontal lobe lesions. According to this result, it can be said that the capsula interna and parts of the brain stem are also involved in the orientation of the commands. Lobus frontalis, cerebellar nuclei, and vestibular nuclei are responsible for eye movements. Colliculus superior, head, and neck movements is an important center that provides harmony with eye movements (Williams 1983). In this study, eye movements were found to be impaired in right parietal lobe involvement, especially in right and brain stem involvement (Figure 3-B). These

findings are consistent with the literature. Complete loss of vision on the same side of nervus opticus damage, heteronymous half-vision loss in chiasma opticum damage, homonymous half-vision loss in tractus opticus injuries, quarter-vision loss in radiato optica lesions, and finally half-vision loss in lobus occipitalis lesions (Moore 1999). In this study, visual loss due to infarction was detected in areas irrigated by right and left cerebral arteries due to infarct size. Motor activity examination of the facial nerve was the most obvious clinical symptom. Especially left cerebri-media infarcts. This may be due to the fact that the facial homunculus occupies a large space on the left side and is therefore easily affected (Figure 3-C, 3-D, 3-E).

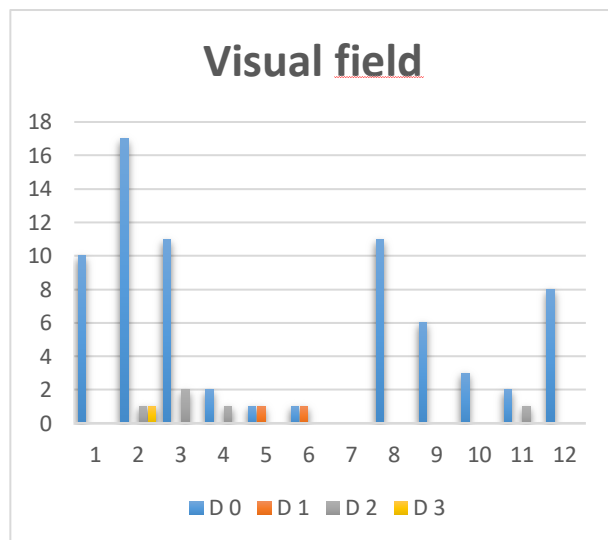


Figure 3-D Visual field

D0 No visual loss.

D1 Partial hemianopia.

D2 Complete hemianopia.

D3 Bilateral hemianopia (blind including cortical blindness)

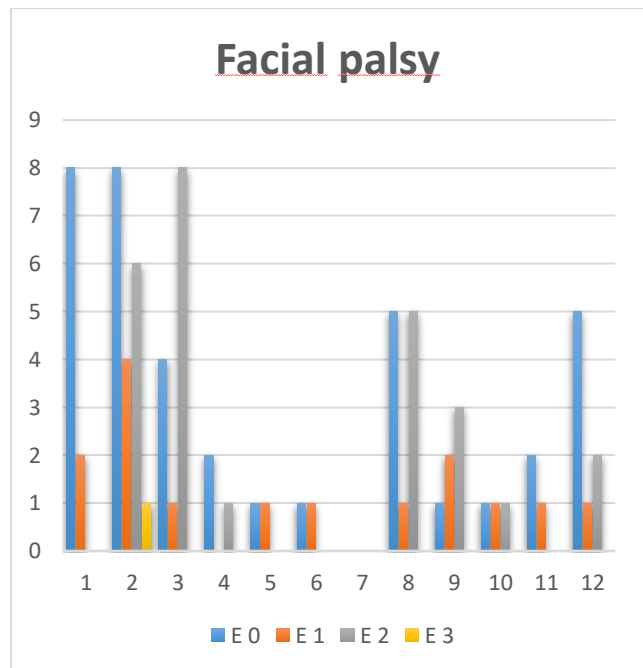


Figure 3-E Facial palsy

E0 Normal symmetrical movements.

E1 Minor paralysis (flattened nasolabial fold, asymmetry on smiling).

E2 Partial paralysis (total or near-total paralysis of lower face).

E3 Complete paralysis of one or both sides (absence of facial movement in the upper and lower face).

Again, the capsula interna can be held responsible for damage to the basal vessels. Particularly in infarct areas caused by vessels that irrigate the brainstem, one-half of the face is completely paralyzed, proving that this infarct affects the peripheral nerves. These findings are consistent with the literature on facial paralysis (Clark 2010, Williams 1983).

Right upper extremity motor activity findings, especially the left middle cerebral artery's infarcts in irrigated areas show us that the left hemisphere controls the right half of the body easily. The interesting finding here was that the motor disorders of the right upper extremity were also caused by the infarct in the right hemisphere due to the infarct size. This shows that there were motor nerve fibers descending without crossing. Significant impairment was

detected in the infarcts of the left central arteries in the right upper extremity. This disorder was thought to be involved in the capsula interna. What was interesting here was to say that the findings in the upper right extremity of the body may be caused by the left capsula interna. Because the descending paths have not yet crossed the decussatio pyramidorum. Crus cerebri, part of the mesencephalon, was held responsible for the infarcts in the areas that irrigate the brain stem. The lack of clinical findings in left upper extremity motor activity proves the presence of the dominant hemisphere (Figure 4-A, 4-B).

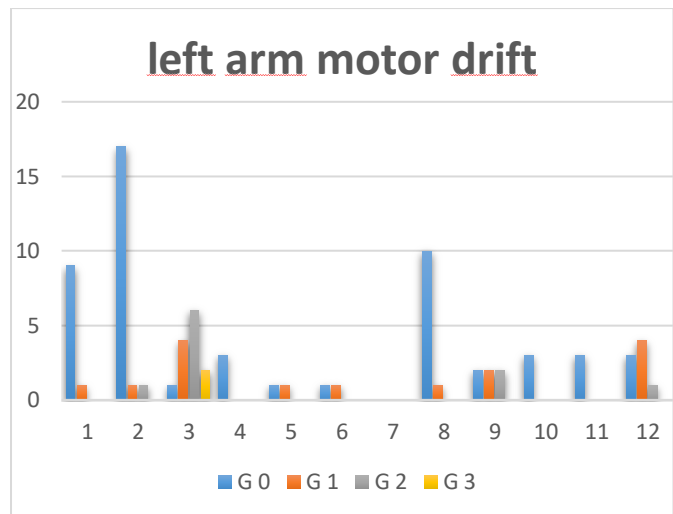


Figure 4-B Left arm motor drift

G0 No drift; limb holds 90 (or 45) degrees for full 10 seconds.

G1 Drift; limb holds 90 (or 45) degrees, but drifts down before full 10 seconds; does not hit bed or other support.

G2 Some effort against gravity; limb cannot get to or maintain (if cued) 90 (or 45) degrees, drifts down to bed, but has some effort against gravity.

G3 No effort against gravity; limb falls.

Limb ataxia is usually seen in lesions of the basal nuclei (Williams 1989). In our study, ataxia was also detected in patients without infarct areas. Only one patient had ataxia as a result of infarcts seen in irrigation areas of the middle cerebral artery, left basal artery, and arteries supplying the brain stem (Figure 4-C). This suggests that ataxia is a neuromediator function rather than an anatomical localization function.

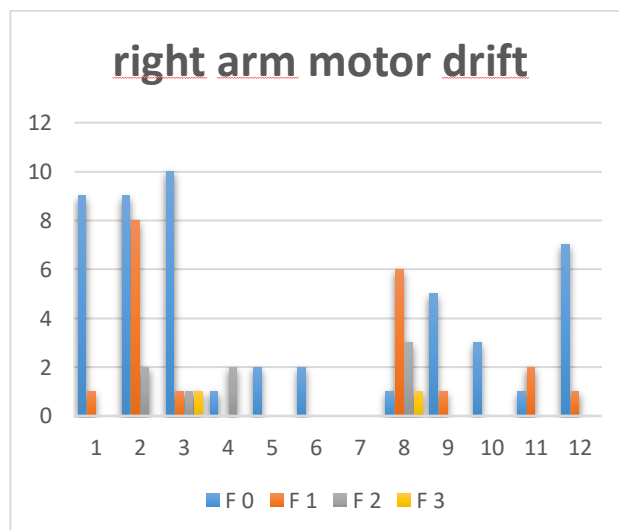


Figure 4-A Right arm motor drift

F0 No drift; limb holds 90 (or 45) degrees for full 10 seconds.

F1 Drift; limb holds 90 (or 45) degrees, but drifts down before full 10 seconds; does not hit bed or other support.

F2 Some effort against gravity; limb cannot get to or maintain (if cued) 90 (or 45) degrees, drifts down to bed, but has some effort against gravity.

F3 No effort against gravity; limb falls

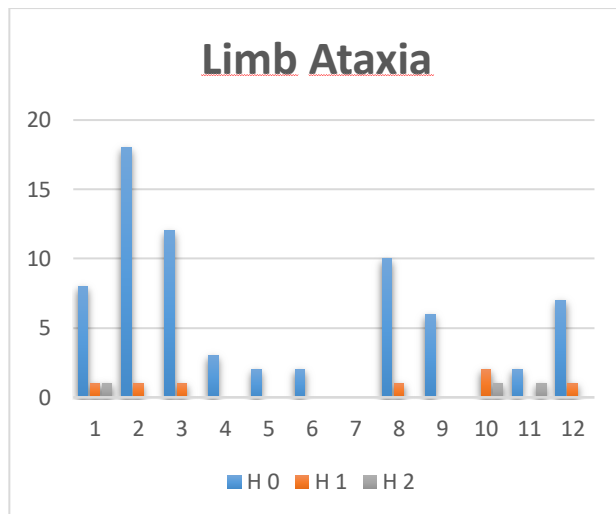


Figure 4-C Limb ataxia

H0 Absent.

H1 Present in one limb.

H2 Present in two limbs.

Sensorial status is one of the most controlled parameters in neurological examination. Therefore, the results of our study are in parallel with the literature (Figure 4-D).

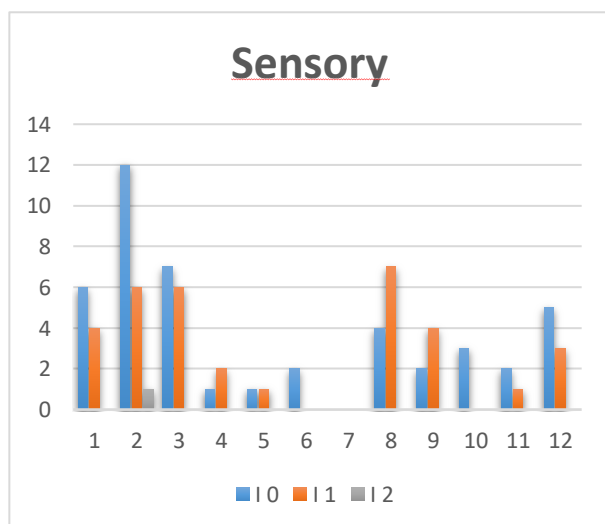


Figure 4-D Sensory

I0 Normal; no sensory loss.

I1 Mild-to-moderate sensory loss; patient feels pinprick is less sharp or is dull on the affected side; or there is a loss of superficial pain with

pinprick, but patient is aware of being touched

I2 Severe or total sensory loss; patient is not aware of being touched in the face, arm, and leg.

Especially, it is evident in the irrigation areas of cerebri media. It should be noted that neurosensorial mild losses were also detected in patients with or without infarction.

Neglect is a difficult parameter to evaluate. The left middle cerebral artery in a patient with infarction in the area was in three patients with neglected (Figure 5-A). None of the areas irrigated by other arteries were considered responsible.

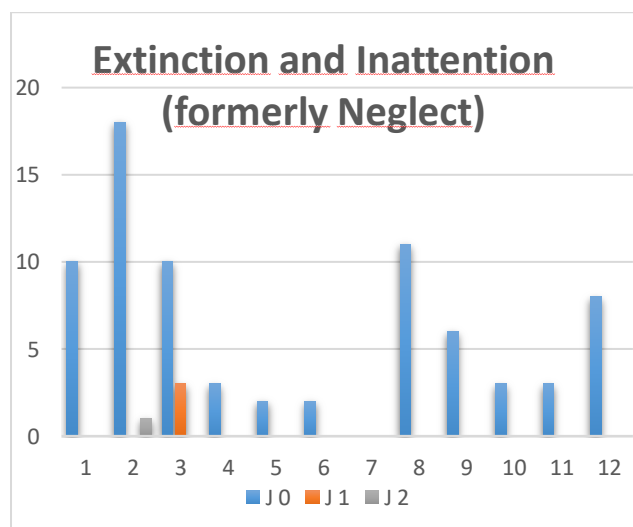


Figure 5-A Extinction and Inattention

J0 No abnormality.

J1 Visual, tactile, auditory, spatial, or personal inattention, or extinction to bilateral simultaneous stimulation in one of the sensory modalities.

J2 Profound hemi-inattention or extinction to more than one modality; does not recognize own hand or orients to only one side of space

Articulation disorder has been detected in infarcts in almost all arteries irrigated areas. This result shows that the pronunciation is almost related to all brain regions. In fact, according to the results of our study left a. cerebri posterior.

Language is the most frequently evaluated parameter in terms of cognition in neurological examination (Figure 5-B, 5-C). The speech center is 90% in the left lobe. In people with a dominant hemisphere on the right, the speech center was also found in the left lobe. (Moore 1999). The results of this study fully support the previous information. Almost all patients left middle cerebral artery involvement. However, the new finding is that the language disorder is again dependent on the size of the infarct. When the relationship between infarct scale, infarct size, and vessels is examined, it is one of the results of this study that infarct size was the most important criterion. In addition, significant localization of brain functions of the left and right frontoparietal lobes was another result.

K2 Severe dysarthria; patient's speech is so slurred as to be unintelligible in the absence of or out of proportion to any dysphasia, or is mute/anarthric.

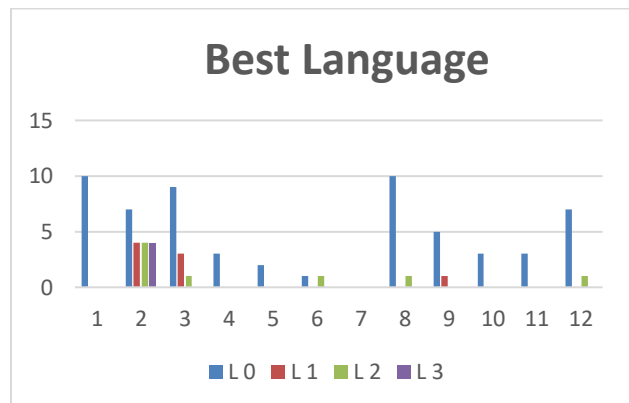


Figure 5-C Best Language

L1 Mild-to-moderate aphasia; some obvious loss of fluency or facility of comprehension, without significant limitation on ideas expressed or form of

expression. Reduction of speech and/or comprehension, however, makes conversation about provided materials difficult or impossible. For

example, in conversation about provided materials, examiner can identify picture or naming card content from patient's response.

L2 Severe aphasia; all communication is through fragmentary expression; great need for inference, questioning, and guessing by the listener. Range

of information that can be exchanged is limited; listener carries burden of communication. Examiner cannot identify materials provided from

patient response.

L3 Mute, global aphasia; no usable speech or auditory comprehension

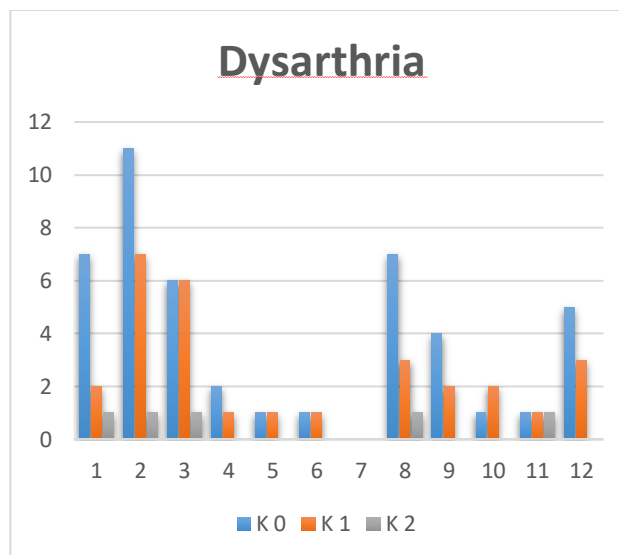
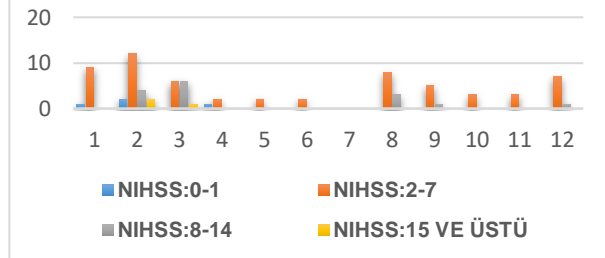


Figure 5-B Dysarthria

K0 Normal.

K1 Mild-to-moderate dysarthria; patient slurs at least some words and, at worst, can be understood with some difficulty.

Infarct scale, infarct size and relationship between vessels



(NIHSS - National Health Stroke Scale)

Figure 6. Infarct scale, infarct size and relationship between vessels

3D evaluation in the brain areas has contributed to the understanding of stroke disease mechanisms and the relationship between brain functions and body functions. The results of this study will be an important source for other studies.

CONCLUSIONS

The 3D evaluation of ischemia shows us that 3D follow-up strongly reveals the anatomy of the lesion, but that the clinical findings do not depend entirely on the localization of the lesion, but rather on the location of the lesion and the size of the lesion. In this sense, infarct size is an important parameter. This finding is one of the most important results of our study. The left middle cerebral artery was found to be the highest artery responsible for stroke. The posterior cerebral artery was found the least affected artery. The artery causing the largest infarct volume was the right middle cerebral artery. When the infarct areas in which the arteries are responsible and the clinical findings were evaluated together, it was found that the symptoms could not be correlated with anatomical localization exactly as in the literature, but the clinical symptoms became clearer as the infarct size increased. The most sensitive findings in infarct facial nerve-related findings and speech-centered findings. The results of this study showed that infarct

localization and size of infarcts do not always correlate with clinical findings. Individual characteristics can change a person's responses to illness. The same results were observed for the nervous system. This supports the individual treatment principle.

Abbreviations:

MRI: magnetic resonance imaging

CT: computational tomography

3D: three-dimensional

CVD: cerebrovascular disease

NIHSS: national health stroke scale

PICA: posterior inferior cerebellar artery

Authorship Contributions: Idea/Concept, Design, Data Collection, Writing, Literature Review: VÇ

All authors reviewed the results and approved the final version of the manuscript.

Acknowledgments: The authors would like to offer their sincere thanks to all research assistants who helped them during the study.

Funding: The authors declared that this study received no financial support.

Conflict of interest: There are no conflicts of interest.

Ethics approval and consent to participate: Ethics committee approval was obtained from the non-invasive clinical research ethics committee, Pamukkale University Medical Faculty, on 28/05/2024 with the number: 2024/10 and E-60116787-020-532903

REFERENCES

- Adams, H. P., B. H. Bendixen, L. J. Kappelle, J. Biller, B. B. Love, D. L. Gordon and E. E. Marsh "Classification of subtype of acute ischemic stroke. Definitions for use in a multicenter clinical trial. TOAST. Trial of Org 10172 in Acute Stroke Treatment." *Stroke*: 24(1): 35-41.
- Adams, H. P., P. H. Davis, E. C. Leira, K.-C. Chang, B. H. Bendixen, W. R. Clarke, R. F. Woolson and M. D. Hansen "Baseline NIH Stroke Scale score strongly predicts outcome after stroke: A report of the Trial of Org 10172 in Acute Stroke Treatment (TOAST)." *Neurology*: 53(1): 126.
- Arıncı, K. and A. Elhan (1997) "Anatomi (Cilt 1), 2." Baskı, Ankara, Güneş Kitabevi: 341.
- Arifoğlu, Y. (2016) *Her Yönüyle Anatomi*, 1. Baskı, İstanbul Tıp Kitabevi, İstanbul.
- Asplund K, Wester PO. (1994) Stroke management around the world- Sweden. *Cerebrovasc Dis*; 4:432-434.
- Bamford, J., P. Sandercock, M. Dennis, J. Burn and C. Warlow (1991) "Classification and natural history of clinically identifiable subtypes of cerebral infarction." *Lancet*: 337(8756): 1521-1526.
- Biousse, V. (2007) "Adams and Victor's Principles of Neurology, 8th Edition." *Journal of Neuro-Ophthalmology*: 27(3): 246.
- Blits, K. C. (1999) "Aristotle: form, function, and comparative anatomy." *Anat Rec*: 257(2): 58-63.
- Bradley, W. G. (2004) *Neurology in clinical practice: principles of diagnosis and management*, Taylor & Francis.
- Clark D, Boutras N, Mendez M. (2010) *The Brain and Behavior*. Cambridge Uni Press Third ed.
- Goldstein, L. B., C. D. Bushnell, R. J. Adams, L. J. Appel, L. T. Braun, S. Chaturvedi, M. A. Creager, A. Culebras, R. H. Eckel, R. G. Hart, J. A. Hinchey, V. J. Howard, E. C. Jauch, S. R. Levine, J. F. Meschia, W. S. Moore, J. V. Nixon and T. A. Pearson "Guidelines for the primary prevention of stroke: a guideline for healthcare professionals from the American Heart Association/American Stroke Association." *Stroke*: 42(2): 517-584.
- Goldstein, L. B., M. R. Jones, D. B. Matchar, L. J. Edwards, J. Hoff, V. Chilukuri, S. B. Armstrong and R. D. Horner (2001) "Improving the reliability of stroke subgroup classification using the Trial of ORG 10172 in Acute Stroke Treatment (TOAST) criteria." *Stroke*: 32(5): 1091-1098.
- Kleindorfer, D., J. Khoury, K. Alwell, C. J. Moomaw, D. Woo, M. L. Flaherty, O. Adeoye, S. Ferioli, P. Khatri and B. M. Kissela (2015) "The impact of Magnetic Resonance Imaging (MRI) on ischemic stroke detection and incidence: minimal impact within a population-based study." *BMC Neurology*: 15: 175.
- Moore, K. L., A. F. Dalley and A. M. (2013) *Agur Clinically oriented anatomy*, Lippincott Williams & Wilkins.
- Murray, C. J. and A. D. Lopez (1997) "Global mortality, disability, and the contribution of risk factors: Global Burden of Disease Study." *Lancet*: 349(9063): 1436-1442.
- Reidenberg, J. S. and J. T. Laitman (2002) "The new face of gross anatomy." *Anat Rec*: 269(2): 81-88.
- Trelease, R. B. (2002) "Anatomical informatics: Millennial perspectives on a newer frontier." *The Anatomical Record*: 269(5): 224-235.
- Williams, P. L. (1989) *Gray's anatomy*, Churchill livingstone Edinburg.