

# A Giant Bilateral Hydronephrosis Case Saved Despite the Patient's Negligence

<sup>1</sup>Lale Tuna<sup>1</sup>, <sup>2</sup>Oya Güven<sup>2</sup>, <sup>3</sup>Mehmet Tamer Çomaklı<sup>3</sup>, <sup>4</sup>Muzaffer Savaş Tepe<sup>4</sup>

<sup>1</sup>Kırklareli Training and Research Hospital, Department of Radiology, Kırklareli, Türkiye

<sup>2</sup>Kırklareli University Faculty of Medicine, Kırklareli Training and Research Hospital, Department of Emergency Medicine, Kırklareli, Türkiye

<sup>3</sup>Kırklareli Training and Research Hospital, Department of Urology, Kırklareli, Türkiye

<sup>4</sup>Kırklareli University Faculty of Medicine, Kırklareli Training and Research Hospital, Department of Radiology, Kırklareli, Türkiye

## Abstract

Hydronephrosis due to nephrolithiasis is common, but giant hydronephrosis is rare in adults. Most of the cases previously identified in the literature are unilateral. In the study, we presented bilateral giant hydronephrosis. A 40-year-old male patient stated that he had stones in both kidneys and took at least 2-3 tablets of various painkillers daily but did not come to urology check-ups due to the pandemic. The examinations detected bilateral giant hydronephrosis, and the parenchyma was severely thinned. The patient underwent bilateral ureterorenoscopic lithotripsy and inserted a double J catheter. Seven liters of fluid were drained from the right and 8 liters from the left. It was determined that the size of both kidneys of the patient, who was followed for two years, decreased by half. Bilateral giant hydronephrosis cases are rarely seen in the literature. With the findings in this study, we tried to show that damaged both kidneys are not life-threatening, and the COVID-19 pandemic has affected our health directly and indirectly.

**Keywords:** Adult, COVID-19, giant, hydronephrosis

## Introduction

Giant hydronephrosis is defined as a hydronephrotic kidney containing more than 1 liter of urine. Palpable mass and abdominal distension findings on examination may be mistakenly interpreted as a mass and confused with polycystic kidney on imaging.

Hydronephrosis is generally unilateral and frequently detected prenatally in the pediatric patient group (1). In adults, hydronephrosis mainly occurs due to ureteral stones, pregnancy, pelvic ureteric junction stenosis and obstruction in the bladder tract (2, 3).

Renal calculus causes 10-15% of hydronephrosis in adult patients (4). In post-mortem studies, the incidence of hydronephrosis in adults was found to be 3.1%, but the literature remains unclear about the incidence of bilateral hydronephrosis in adults (5).

Hydronephrosis due to nephrolithiasis is common, but giant hydronephrosis is a rare entity in adults. Most of the cases previously identified in the literature are unilateral. This study will try to emphasize a bilateral giant hydronephrosis case and show that it heals with appropriate and rapid treatment without posing a life-threatening risk.

## Case Report

A 40-year-old male patient applied to the emergency room with complaints of increasing abdominal pain, nausea, vomiting, burning sensation in urination, and frequent urination for 1 week. He had a familial history of hypertension and is being treated due to hypertension. He has been using lercanidipine hydrochloride. He smoked 1 pack/day of cigarettes and did not report chronic alcohol use. He stated that he was diagnosed with bilateral ureteral stones a year ago, and Extracorporeal Shock Wave Lithotripsy (ESWL) treatment was recommended. Still, he did not come for a urology treatment due to the COVID-19 pandemic and took at least 2-3 tablets of various analgesics daily. Lung examination was normal, and there was tenderness in both the abdomen's upper quadrants and costovertebral angles. Also, there was a palpable mass in both costovertebral angles. There was no pretibial edema. Blood pressure was 120/70 mmHg, heart rate was 100/minute, and electrocardiography showed normal sinus rhythm (no T peak). In blood tests taken, leukocyte count was 10.7 10<sup>9</sup>/L, urea 424 mg/dl, creatinine 12.7 mg/dl, C-Reactive protein (C-RP) 1.4 mg/dl, glomerular filtration rate (GFR) 4 ml/minute, pH 7.17,

**Corresponding Author:** Oya Güven

**e-mail:** ersinoya@yahoo.com

**Received:** 09.06.2024 • **Revision:** 09.09.2024 • **Accepted:** 24.09.2024

**DOI:** 10.33706/jemcr.1498336

©Copyright 2020 by Emergency Physicians Association of Turkey - Available online at www.jemcr.com

**Cite this article as:** Tuna L, Güven O, Çomaklı MT, Tepe MS. A Giant Bilateral Hydronephrosis Case Saved Despite the Patient's Negligence. Journal of Emergency Medicine Case Reports. 2024;15(4): 90-92

pCO<sub>2</sub> 27 mmHg, HCO<sub>3</sub> 9.6 mg/dl, base deficit -17 mmol/L was observed. Normal yellow urine came from the urinary catheter. In the urine test, pH and density were normal, and 12% leukocytes and 10% erythrocytes were detected.

Urinary ultrasound (USG) was performed, and bilateral cystic hydronephrosis was detected. Abdominal computer tomography (CT) showed severe thinning in kidney parenchyma and bilateral giant hydronephrosis (Rad-V Radiology hydronephrosis grading system). Kidney dimensions (Length/AP thickness/Width) were measured as 29x24x18.5 cm on the right and 31x24x12.5 cm on the left. A 17x8 mm diameter stone was detected in the right proximal ureter, and a 23x9 mm diameter stone was detected in the left proximal ureter (Figure-1). The diameter of the right proximal ureter was measured as 16 mm, and the diameter of the left proximal ureter was measured as 32 mm. The ureters distal to the stone were observed within normal limits.

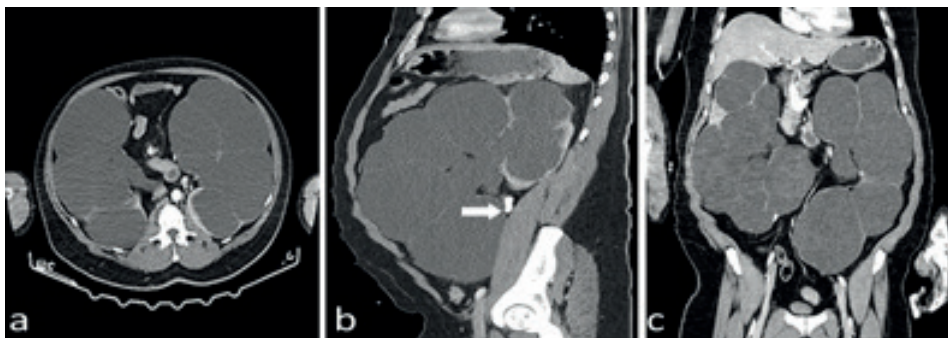Considering the patient's acute renal failure (ARF), internal medicine and urology consultation was performed.

The internal medicine physician did not consider emergency dialysis because there was urine output. The urologist planned an operation due to bilateral ureteral stones.

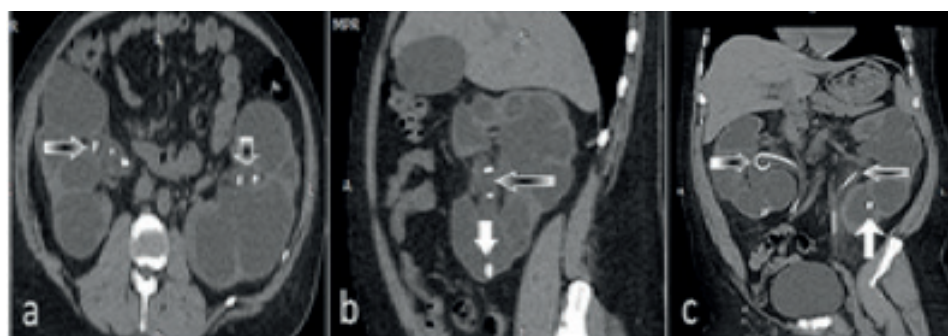
The patient underwent bilateral ureterorenoscopic lithotripsy and was inserted into a double J catheter. Seven liters of liquid were drained from the right and 8 liters from the left kidney. In blood tests taken 10 days after the operation, leukocyte 8.47 10<sup>9</sup>/L, C-RP 0.96 mg/dl, urea 58 mg/dl, creatinine 2.29 mg/dl, C-RP 0.92 mg/dl, GFR 33 ml/min, pH 7.33, pCO<sub>2</sub> 27 mmHg, HCO<sub>3</sub> 14.3 mg/dl, base deficit -10.1 mmol/L. The patient was discharged with the recommendation to come 1 month later to the urology outpatient clinic.

The control CT scan taken 1 month later showed that the kidney dimensions (Length/AP thickness/Width) were 17x15x9 cm on the right and 20.5x17x9.5 cm on the left (Figure-2).

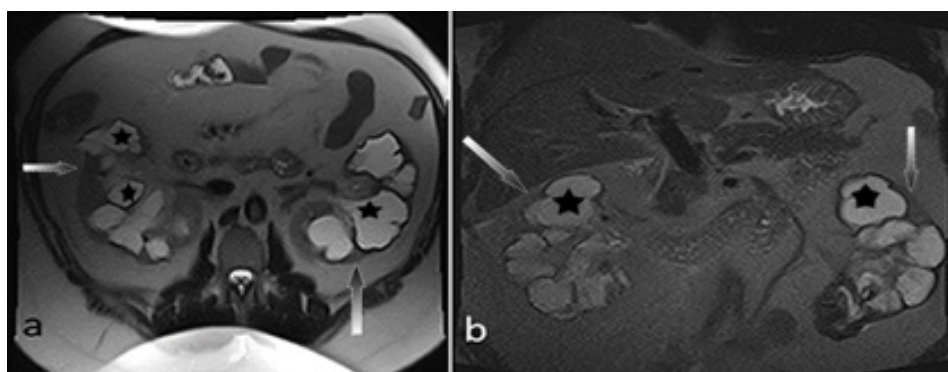
In the follow-up abdominal magnetic resonance imaging (MRI) obtained twenty months later, kidney dimensions (Length/AP thickness/Width) were seen to be 12.6x12x7.5 cm on the right and 15x11.7x6.4 cm on the left (Figure-3).



**Figure 1 (a-b-c).** Axial, sagittal, and coronal contrast-enhanced abdominal CT images. Bilateral giant hydronephrosis, stone in the left proximal ureter (b: white arrow)



**Figure 2 (a-b-c).** Axial, sagittal, and coronal non-contrast abdominal CT images. Bilateral ureteric stents on control images in 1 month after admission to the hospital (a-b-c: hollow arrows indicate double J catheter, b-c: White arrows indicate renal calculus)



**Figure 3 (a-b).** Control images 20 months after admission to the hospital. Axial and coronal T2W MRI images show dilated hyperintense calyces (black stars) and markedly thinned hypointense renal cortex (dotted black/white arrows) bilaterally.

## Discussion

Cases of giant hydronephrosis are rarely seen in the literature. There is usually an obstructive cause, such as a stone or an intra-abdominal mass. In the case report by Gölcük et al., giant hydronephrosis was observed on the right side, and the causative factor was determined to be nephrolithiasis (6). Our patient also developed hydronephrosis after stone-related obstruction, but unlike the literature, bilateral giant hydronephrosis was detected.

It is difficult to diagnose giant hydronephrosis. Because it can be confused with abdominal mass or fluid. Since our patient had a known history of bilateral nephrolithiasis and chronic flank pain, we focused on the kidneys. That's why diagnosis and treatment could be done quickly.

Nephrostomy, pyeloplasty, and calicourethorostomy can be applied to treat hydronephrosis. In cases of advanced hydronephrosis, nephrectomy may be the only solution if kidney functions are impaired. In the case of Hassen et al., a nephrectomy was performed on the giant left kidney due to the structural defect in the retroperitoneum and massive pelvic dilatation (7). In their study by Sallami et al., nephrectomy was performed in patients who did not respond to kidney-protective treatment (8). In our case, since the blood tests and clinical findings improved after the lithotripsy operation, the patient did not need additional surgery. This is a rare case in the literature because both kidneys were spared.

Although it may be difficult to identify hydronephrosis clinically, it can be diagnosed and monitored easily with imaging studies. In our patient, the known history of nephrolithiasis and the developing symptoms were guiding.

## Conclusion

Patients with nephrolithiasis frequently visit the emergency room, especially with complaints of pain. In this way,

urology and radiology follow-up can be performed, but our patient had his treatment (long-term analgesic use) at home due to fear of COVID-19 infection. In addition to the deterioration of renal functions due to the existing obstruction and uncontrolled analgesic use and abuse, the development of renal failure was inevitable. Cases of bilateral giant hydronephrosis are rarely seen in the literature. With the findings in this study, we tried to show that damage to both kidneys is reversible, and the COVID-19 pandemic has affected our health directly and indirectly.

Consent was obtained from the patient for this study.

The authors declared no conflict of interest.

## References

1. Yiee J, Wilcox D. Management of fetal hydronephrosis. *Pediatric Nephrology* 2008; 23: 347-353.
2. Kaura KS, Kumar M, Sokhal AK, Gupta AK, Purkait B, Saini D, et. al. Giant hydronephrosis: still a reality!. *Turkish Journal of Urology* 2017; 43 (3): 337.
3. Nuraj P, Hyseni N. The diagnosis of obstructive hydronephrosis with color doppler ultrasound. *Acta Informatica Medica* 2017; 25(3): 178.
4. Chi AC, Flury SC. Urology patients in the nephrology practice. *Advances in Chronic Kidney Disease* 2013; 20(5): 441-448.
5. McDougal WS, Wein AJ, Kavoussi LR, Partin AW, Peters CA. *Campbell-Walsh urology 11th edition review E-book*. Elsevier Health Sciences; 2015.
6. Golcuk Y, Ozsarac M, Eseroglu E, Yuksel MB. Giant hydronephrosis. *Western Journal of Emergency Medicine* 2014; 15 (4): 356.
7. Hassen SM, Issack FH, Mammed FO, Hassen IK. Giant hydronephrosis secondary to ureteropelvic junction obstruction, a rare occurrence, case report. *Urology Case Reports* 2021; 39: 101803.
8. Sallami S, Cherif K, Ben RS, Dagudagui N, Rochdi E, Nidhameddine K, et al. Giant hydronephrosis in adults: What is the best approach? Retrospective analysis of 24 cases. *Nephro-Urol Mon.* 2011; 3 (3): 177-181.