

## Case Report / Olgu Sunumu

# CD56 might be a useful diagnostic marker of müllerian-derived tumors: a case report of an uterine tumor resembling ovarian sex cord tumor (UTROSCT) suggesting polyphenotypic origin and review of the literature

## CD56 müllerian kökenli tümörlerin yararlı bir tanısal belirteci olabilir: Polifenotipik kökeni destekleyen ovarian seks kord tümöre benzeyen uterin tümör (UTROSCT) olgu sunumu ve literatür derlemesi

Hatice Özer<sup>1,†</sup>, Handan Aker<sup>1</sup>, Ahmet Emin Mutlu<sup>2</sup>, Ali Yanık<sup>2</sup>, Tülay Koç<sup>1</sup>, Hande Keser<sup>1</sup>

*Departments of <sup>1</sup>Pathology and <sup>2</sup>Obstetrics and Gynecology, Cumhuriyet University Faculty of Medicine, Sivas*

### Abstract

We present the clinicopathologic and immunophenotypic features of a case of uterine tumor resembling ovarian sex cord tumor. The patient age was 38 years and presented with discomfort in the lower abdomen, vaginal bleeding, and dysmenorrhea. Pelvic ultrasound and computed tomography of the lower abdomen revealed a semisolid mass extending to umbilicus. Bilateral adnexal tenderness was found. The patient underwent operation with an ovarian tumor as a preoperative diagnosis. In the intraoperative consultation, there was a suspicion of a uterine tumor resembling ovarian sex cord stromal tumor. Oophorectomy was not performed because of her age. The well-circumscribed nodular tumor was 18 cm in diameter and composed of ovarian sex cord-like areas, bundles of myoid cells. Besides some cells exhibited clear cytoplasm. There were cystic spaces and infarct type of necrosis. All tumor cells showed strong immunoreactivity for CD56. In addition, CD10, desmin, actin, inhibin, WT-1, HBM45, estrogen, and progesterone receptor positivity were present but calretinin, CD99, CD34, CD117, S100, and pan-cytokeratin were negative. We think that this tumor as well as the other tumors of the female genital tract might be arisen from pluripotent mesenchymal cells which are derived from Müllerian ducts that could be

#### <sup>†</sup> Corresponding Author:

Dr. Hatice Özer, Patoloji Anabilim Dalı, Cumhuriyet Üniversitesi Tıp Fakültesi, Sivas

Email: [haticozer@gmail.com](mailto:haticozer@gmail.com)

**Ozer et al.: Features of uterine tumor resembling ovarian sex-cord tumor** 132

This is an open-access article distributed under the terms of the Creative Commons Attribution License, which permits unrestricted use, distribution, and reproduction in any medium, provided the original author(s) and source are credited.

This article may be cited as: Ozer H, Aker H, Mutlu AE, Yanik A, Koc T, Keser H. CD56 might be a useful diagnostic marker of müllerian-derived tumors: report of an uterine tumor resembling ovarian sex cord tumor (utrosct) suggesting polyphenotypic origin and review of the literature. *Basic Clin Sci* 2013; 2: 132-141. Available from: [www.bsciences.com](http://www.bsciences.com).

differentiate into endometrial stromal, epithelial and smooth muscle. Our data support that this unusual uterine tumor is a polyphenotypic neoplasm with true sex cord differentiation.

**Keywords:** Uterine tumor, UTROSCT, immunohistochemistry, CD56, Müllerian system

## Özet

Ovarian seks kord tümöre benzeyen uterin tümör olgusunun klinikopatolojik ve immünofenotipik özelliklerini sunuyoruz. Otuz sekiz yaşında olan olgu alt karın ağrısı, vajinal kanama ve dismenore ile başvurdu. Pelvik bölgenin ultrasonografi ve bilgisayarlı tomografisinde göbeğe kadar uzanan semisolid bir kitle izlendi. Bilateral adneksal hassasiyet vardı. Olgu ovarian tümör tanısı ile ameliyata alındı. İntraoperatif konsültasyonda ovarian seks kord tümöre benzeyen uterin tümör şüphesi belirtildi. Hastanın yaşından dolayı oofektomi yapılmadı. İyi sınırlı nodüler tümörün çapı 18 cm idi ve myoid hücre demetleri içeren ovarian seks korda benzer alanlar gözlemlendi. Bunun yanında bazı hücrelerin sitoplazması berraktı. Kistik boşluklar ve infarkt tipi nekroz alanları vardı. Tüm tümör hücreleri CD56 için kuvvetli immünoreaktivite gösterdi. İlave olarak CD10, desmin aktin, inhibin, WT-1, HBM45, östrojen ve progesteron reseptör pozitifliği gözlemlendi ama kalretinin, CD99, CD34, CD117, S100 ve pansitokeratin negatif bulundu. Diğer kadın genital yol tümörleri gibi bu tümör de müllerian kanaldan köken alan pluripotent mezensimal hücrelerden köken almış olabilir. Bulgularımız bu nadir görülen ovarian tümörün gerçek seks kord farklılaşması olan polifenotipik bir neoplazm olduğunu desteklemektedir.

**Anahtar sözcükler:** Uterin tümör, UTROSCT, immünohistokimya, CD56, Müllerian sistem

## Introduction

Uterine tumors resembling ovarian sex cord-stromal tumors (UTROSCTs) were first recognized by Clement and Scully [1]. These unusual groups of stromal neoplasm exhibiting prominent sex cord-like differentiation are very rare. Their histogenesis is controversial as whether they represent a variant of endometrial stromal tumor (EST) or a separate tumor [2-11]. However, World Health Organization of tumors of the uterine corpus, UTROSCT was placed in the miscellaneous category [12]. Morphologic and immunohistochemical findings indicate that UTROSCT arise from pluripotent mesenchymal cells, which predominantly differentiate into sex cord cells [5, 6]. Besides endometrial stromal cells, smooth and skeletal muscle and epithelial or clear cell differentiation can also occur [4, 6, 13]. Here we described the clinical, histological and immunohistochemical features of a rare case of UTROSCT, discussed the diagnostic difficulties and possible neoplastic origin. Since CD56 immunoreactivity has not been systematically investigated in such tumors that may mimic sex cord-stromal tumors, it is noteworthy to mention that the diagnosis of UTROSCT can be supported by CD56.

## Case Report

A 38-year-old woman, G4P3, presented with a mass in the lower abdomen and vaginal bleeding for two months. Abdominal and pelvic examinations revealed painless, mobile, and an asymmetric mass reaching the umbilical point. Her gynecologic examination revealed an enlarged uterus, 24 weeks in size, and bilateral adnexa that were sensitive. An ultrasonography showed enlarged uterus (19x18x9.8 cm) consisting of cystic and solid parts. There were thin and thick septations in the heterogenous areas, and some fluid image. The ovaries were not visualized (Figure 1a). Contrasted spiral tomography of the lower abdomen was indicated a lobulated semisolid mass, measured 21x18x13 cm, thick-walled, with centrally intensive content that extended into the abdomen, displacing the bladder to anteriorly. Bilateral inguinal lymphadenopathy were also noted (Figure 1b). The patient underwent operation with an ovarian tumor as a preoperative diagnosis. Intraoperative consultation was a suspicion of an UTROSCT. Because of the adnexa appeared normal, the tubes and ovaries had preserved considering her age. Total abdominal hysterectomy was performed.

Grossly the uterus weighed 2135 gr, and measured 25x18x8.5 cm. On the cut surface the uterine wall showed an intramural soft nodule, 18 cm in diameter which extending from the half of the uterine cavity to the endocervical canal that stretching up to 19 cm (Figure 2). There were no connection either the endometrium or the endocervical mucosa. The tumor has a well-circumscribed contour, and tend to bulge above the surrounding myometrium. The cut surface partly cystic, necrotic and hemorrhagic with areas of yellowish to tan colored solid fleshy nodules. There were also intramural and subserous six leiomyomas measured between 0.5-4.5 cm in diameter.

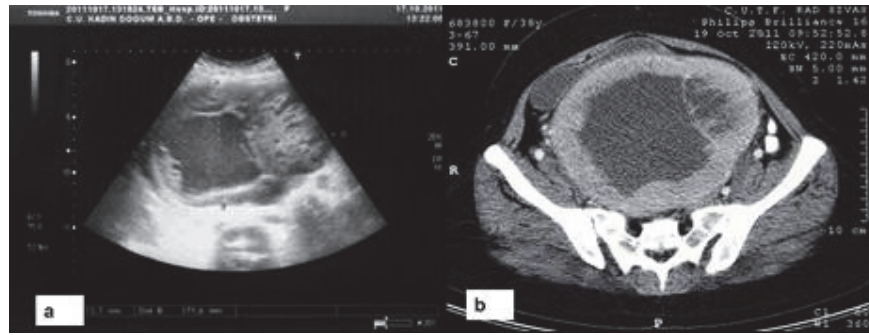
Microscopically, the tumor has noninfiltrative margins that compress the surrounding both myometrium and endocervical canal. (Figure 3a). There were cystic spaces, infarct type of necrosis. The tumor cells have uniform, small, darkly staining round or oval nuclei with granular chromatin and inconspicuous nuclei that closely resemble proliferative-phase endometrial cells. Mitotic activity is about 0-1/10HPF. These cells grow in cords, trabeculae, and occasional glandular structure, some of like Call-Exner bodies that have an appearance reminiscent of an ovarian sex cord-stromal tumor. There were also bundles of myoid cells scattered within the tumor, and focal areas of clear cells that generally located around the necrotic areas and at the periphery of the tumor (Figures 3b, c, d). Scattered nuclear pleomorphism were only seen around the necrotic and degenerated cells. Vascular pattern of the tumor is distinctive, comprising small arterioles. Perivascular edema was distinct in some areas.

Immunohistochemistry using CD10, CD56, actin, desmin, inhibin, estrogen and progesterone receptors, WT-1, HMB-45, CD99, calretinin, pan-cytokeratin, CD34, CD117, and S100 was applied on formalin fixed paraffin-embedded sections. All tumor cells showed strong immunoreactivity for CD56 (Figure 4). The results of the immunohistochemical analyses of our case were summarized in Table 1. Pathologic diagnosis was UTROSCT.

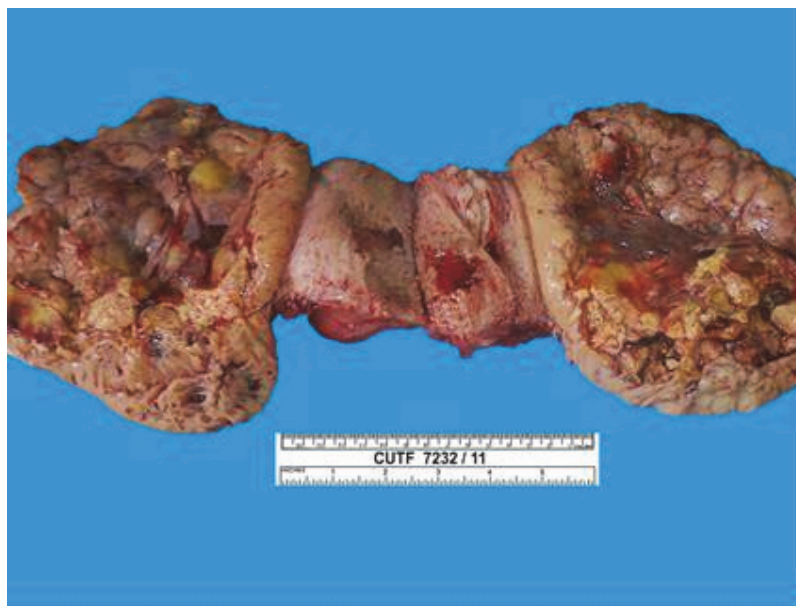### **Ozer et al.: Features of uterine tumor resembling ovarian sex-cord tumor** 134

This is an open-access article distributed under the terms of the Creative Commons Attribution License, which permits unrestricted use, distribution, and reproduction in any medium, provided the original author(s) and source are credited.

This article may be cited as: Ozer H, Aker H, Mutlu AE, Yanik A, Koc T, Keser H. CD56 might be a useful diagnostic marker of müllerian-derived tumors: report of an uterine tumor resembling ovarian sex cord tumor (utrosct) suggesting polyphenotypic origin and review of the literature. *Basic Clin Sci* 2013; 2: 132-141. Available from: [www.bsciences.com](http://www.bsciences.com).



**Figure 1.** Abdominal ultrasound (a) and computed tomography (b) showed heterogeneous but well circumscribed mass, consisting of cystic and solid parts. The relationship with the uterine cavity is not well defined, and the ovaries were not visualized.

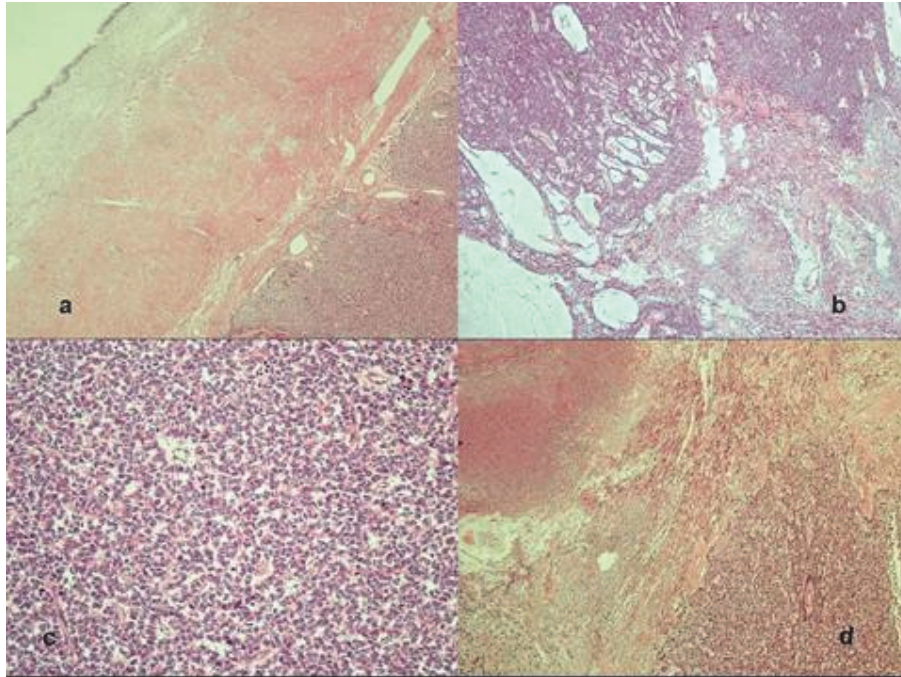


**Figure 2.** The tumor has a well-circumscribed contour, 18 cm in diameter, and tend to bulge above the surrounding myometrium. The cut surface partly cystic, necrotic and hemorrhagic with areas of yellowish to tan colored solid fleshy nodules. There were also an intramural leiomyoma.

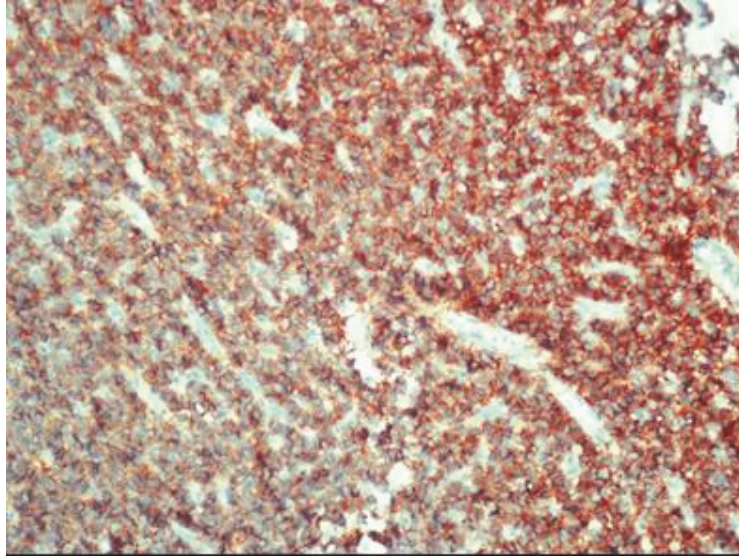
**Ozer et al.: Features of uterine tumor resembling ovarian sex-cord tumor**

This is an open-access article distributed under the terms of the Creative Common Attribution License, which permits unrestricted use, distribution, and reproduction in any medium, provided the original author(s) and source are credited.

This article may be cited as: Ozer H, Aker H, Mutlu AE, Yanik A, Koc T, Keser H. CD56 might be a useful diagnostic marker of müllerian-derived tumors: report of an uterine tumor resembling ovarian sex cord tumor (utrosct) suggesting polyphenotypic origin and review of the literature. *Basic Clin Sci* 2013; 2: 132-141. Available from: [www.bcsiences.com](http://www.bcsiences.com).



**Figure 3. (a) The tumor has noninfiltrative margins that compress the surrounding both myometrium and endocervical canal. (b) Tumoral cells grow in cords, trabeculae, and occasional glandular structure, some of like Call-Exner bodies that have an appearance reminiscent of an ovarian sex cord-stromal tumor (upper part). There were also bundles of myoid cells, and focal areas of clear cells at the lower right. There were cystic spaces at the lower left. (c) The tumor cells have uniform, small, darkly staining round or oval nuclei with granular chromatin and inconspicuous nuclei that closely resemble proliferative-phase endometrial cells. (d) Necrosis (upper left), bundles of myoid cells (center), and sex cord-like areas (lower left).**



**Figure 4.** All tumor cells showed strong membranous immunoreactivity for CD56.

**Table 1.** Findings of immunohistochemistry.

Antibody	Clone	Staining pattern
CD56	Clone: 123C3, Thermo Scientific	Diffuse positive
CD10	Clone: 56C6, Scy Tek	Focal positive (some areas)
Actin	Clone: 1A4, Scy Tek	Focal positive (some areas and myoid cells)
Desmin	Clone: D33, Dako	Focal positive (some areas and myoid cells)
Inhibin	Clone: R1, Dako	Focal positive
Estrogen receptor	Clone: SP1, Dako	Positive
Progesterone receptor	Clone: PGR636, Dako	Positive
WT1	Clone: WT-1.1, Scy Tek	Focal positive (some areas)
HMB 45	Clone: HMB45, Scy Tek	Focal positive (only myoid cells)
CD99	Clone: HO 36-1.1, Scy Tek	Negative
Calretinin	Clone: DAK-Calret 1, Dako	Negative
Pancytokeratin	Clone: AE1/AE3, Scy Tek	Negative
CD34	Clone: QBEnd/10, Leica	Negative
CD117	Clone: 104D2, Biogenex	Negative
S100	Clone: 4C4.9, Scy Tek	Negative

## Discussion

An unusual group of ESTs was first recognized as endometrial stromal tumors with prominent sex cord-stromal tumors elements by Clement and Scully in 1976. They divided into 2 types by the amount of sex cord-like components. Type I tumors, commonly referred to as endometrial stromal tumors with sex cord-like elements (ESTSCLE), epithelial-like structures that have an appearance reminiscent of an ovarian sex cord-stromal tumor areas are between 10-50%. Whereas sex cord-like elements which are predominated (>50%) in type 2 tumors referred to as UTROSCTs [1]. The behavior of the ESTSCLE is that of the corresponding stromal neoplasm, either endometrial stromal nodule or endometrial stromal sarcoma. Although the behavior of UTROSCT is benign, these tumors are generally considered tumors of low malignant potential with a small risk of local recurrence or metastasis [9, 14-16]. The treatment of choice is hysterectomy with bilateral salpingo-oophorectomy. Patients with endometrial stromal sarcomas are often hormone sensitive and it has been shown that patients retaining their ovaries have a much higher risk of recurrence [16].

World Health Organization distinguished these neoplasms from ESTs (12); however, we consider as some others these rare neoplasms to be variants of ESTs that are derived from multipotential uterine mesenchymal cells that have the capacity for differentiation along endometrial stromal, sex cord, epithelial or myoid lines [4, 6, 10, 13, 17]. Our data support that this unusual uterine tumor is a polyphenotypic neoplasm with true sex cord differentiation, from a derivative of the Müllerian tract. Macroscopically, these tumors are generally round, well-delineated masses up to 10 cm in diameter that may be submucosal, intramural or subserosal. The cut surface is tan to yellow; some have foci of cysts, necrosis, and hemorrhage and lack the characteristic whorled pattern of leiomyoma.

Well-circumscribed nodule in our case was intramural without any apparent connections to both endometrium and endocervical mucosa, fleshy with yellow to tan sectioned surface. There were also microcystic spaces with foci of necrosis and hemorrhage. In the tumor with a diameter of 18 cm, microscopically, there are sex cords resembling those found in ovarian tumors. These may appear as anastomosing trabeculae, cords, retiform areas, small nests, well-formed tubules with lumens. Structures resembling Call-Exner bodies may also be present. The stroma may be cellular or hyalinized and sometimes hypocellular. Cells with smooth muscle and rhabdoid appearance and foamy cytoplasm may be seen. Foamy histiocytes, cystic degeneration, hemorrhagia and necrosis may be present. Vascular pattern is distinctive, comprising small arterioles.

Features of the presented tumor were mixture of predominantly sex cord-like areas with smooth muscle and clear cell differentiation. There were also some hemorrhage, necrosis, and microcytic degeneration areas. The sex cord-like elements have inconstant immunophenotype. Various immunoreactivity with epithelial, myoid and hormone receptors were shown besides sex cord-stromal markers. Specifically, inhibin, calretinin, CD99, melan-A, and recently CD56 have been accepted as immunohistochemical markers of sex cord differentiation based on application of these markers to sex cord-stromal tumors of the ovary [2, 3, 5-11, 17-19]. Calretinin may be a more sensitive but less specific marker than inhibin [20, 21]. In our case, calretinin immunoreactivity was not shown,

**Ozer et al.: Features of uterine tumor resembling ovarian sex-cord tumor** 138

This is an open-access article distributed under the terms of the Creative Commons Attribution License, which permits unrestricted use, distribution, and reproduction in any medium, provided the original author(s) and source are credited.

This article may be cited as: Ozer H, Aker H, Mutlu AE, Yanik A, Koc T, Keser H. CD56 might be a useful diagnostic marker of müllerian-derived tumors: report of an uterine tumor resembling ovarian sex cord tumor (utrosct) suggesting polyphenotypic origin and review of the literature. *Basic Clin Sci* 2013; 2: 132-141. Available from: [www.bcsiences.com](http://www.bcsiences.com).

while inhibin was focal positive. Focal positivity for CD10, CD99, and WT-1 is well described in these tumors but none of these markers is also specific [3, 22, 23]. According to Irving's report, they recommended the use of two markers of sex cord differentiation (calretinin and one of the melan-A, CD99, or inhibin) [5].

A review about immunohistochemical features of the 44 cases of UTROSCT reported by Abdullazade et al. [10] shows inhibin expression in 49%, calretinin in 94%, caldesmon in 7%, desmin in 46%, AE1/AE3 in 73%, EMA in 29%, CD10 in 50%, but CD56 in 100%. Therefore, CD56 positivity should confirm a diagnosis of UTROSCT [10]. In the present study, we applied a panel of antibodies, including sex cord differentiation (inhibin, calretinin, CD99), myoid (desmin, actin), endometrial stroma (CD10) and CD56, WT1, HMB45, CD34, CD117, S100 as well as hormone receptors (estrogen and progesterone receptors). We found that the tumor was immunoreactive for inhibin, desmin, actin, CD10, WT1, HMB45, estrogen and progesterone receptor. They all showed positivity in tumoral cells and positivity in focal restricted areas of smooth muscle. Immunostaining for CD99, calretinin, CD34, CD117, pan-cytokeratin, and S100 were negative. Tumoral cells exhibited diffuse strong membranous staining with CD56. Although the limited number of the reported cases in the literature, CD56 seems to be the most sensitive marker for the diagnosis of UTROSCTs. At least, immunohistochemical staining may be useful for establishing the diagnosis in problematic cases. In our case, markers which have been identified as sex cord differentiation (inhibin, calretinin, CD99, Melan-A) showed divergent results from similar lesions reported in the literature. Our conclusion is that to perform a diagnosis of UTROSCT, CD56 immunohistochemical have to be expressed. To our knowledge, description of CD56 immunoreactivity in UTROSCT is limited to a few previous case reports [6, 9, 10, 17]. Since McCluggage et al. [17] noticed diffuse CD56 positivity in an ovarian sex cord-stromal tumor, they planned to examine a study in a large series of this group of neoplasm. They published a series of 85 cases including ovarian sex cord-stromal tumors which CD56 staining has not previously been studied. They have shown that CD56 is almost universally expressed in all the major morphological types of ovarian sex cord-stromal tumor [17].

The differential diagnosis of UTROSCT includes low-grade stromal sarcomas, highly cellular smooth muscle tumors, mixed müllerian tumor, adenosarcoma and perivascular epithelial tumors (PEComas). Although immunohistochemical markers could help in the differential diagnosis, specific morphological findings usually diagnostic in most of the cases. Especially CD56 expression in UTROSCT will be a diagnostic value. Extensive sampling of the tumor interface is extremely important. Myometrial or vascular invasion are the two most important features in the distinction between endometrial stromal nodule and endometrial stromal sarcoma. Highly cellular leiomyoma has a fascicular growth and cleft-like spaces at the periphery of the lesion, the tumor cells merge with the surrounding myometrium, and the vessels are typically thick and large in contrast to the delicate arteriolar network present in endometrial stromal tumors. Small foci of carcinoma admixed with the sarcomatous component would favor a malign mixed müllerian tumor. PEComas may show poorly defined margins, and their cut surface ranges from grey-white to tan or yellow, resemble the appearance to an endometrial stromal tumors. The tumor cells have abundant clear to eosinophilic cytoplasm that may grow in sheets, and a prominent network of small vessels. HMB45 can help to rule out PEComas [16]. Although



the origin of the sex cord-like elements remain controversial, this tumor as well as the other tumors of the female genital tract might be arisen from pluripotent mesenchymal cells which are derived from Müllerian ducts that could be differentiate into endometrial stromal, epithelial and smooth muscle. Like the cell of origin of ovarian epithelial tumors, it is widely believed that ovarian epithelial tumors arise from tissues that are embryologically derived from the Müllerian ducts. The question is “Does the emperor have no clothes?” as also asked by Louis Dubeau [24, 25]. Our morphologic and immunohistochemical findings indicate that UTROSCT arise from pluripotential uterine mesenchymal cells, which predominantly differentiate into sex cord cells.

## References

1. Clement PB, Scully RE. Uterine tumors resembling ovarian sex-cord tumors. A clinicopathologic analysis of fourteen cases. *Am J Clin Pathol.* 1976 Sep;66(3):512-25.
2. Hauptmann S, Nadjari B, Kraus J, Turnwald W, Dietel M. Uterine tumor resembling ovarian sex-cord tumor--a case report and review of the literature. *Virchows Arch.* 2001 Jul;439(1):97-101.
3. Sutak J, Lazic D, Cullimore JE. Uterine tumour resembling an ovarian sex cord tumour. *J Clin Pathol.* 2005 Aug;58(8):888-90.
4. Zámecník M, Staník M. Uterine tumor resembling ovarian sex cord tumor (UTROSCT). Report of case suggesting neoplastic origin of intratumoral myoid cells. *Cesk Patol.* 2006 Jul;42(3):145-9.
5. Irving JA, Carinelli S, Prat J. Uterine tumors resembling ovarian sex cord tumors are polyphenotypic neoplasms with true sex cord differentiation. *Mod Pathol.* 2006 Jan;19(1):17-24.
6. Hurrell DP, McCluggage WG. Uterine tumour resembling ovarian sex cord tumour is an immunohistochemically polyphenotypic neoplasm which exhibits coexpression of epithelial, myoid and sex cord markers. *J Clin Pathol.* 2007 Oct;60(10):1148-54.
7. Dede M, Gezginç K, Yenen MC, Ulubay M, Safalı M, Başer İ. Uterine tumour resembling ovarian sex cord tumour. *Eur J Gen Med* 2008; 5(2):118-20.
8. Aziz O, Giles J, Knowles S. Uterine tumours resembling ovarian sex cord tumours: a case report. *Cases J.* 2009 Jan 14;2(1):55.
9. O'Meara AC, Giger OT, Kurrer M, Schaer G. Case report: Recurrence of a uterine tumor resembling ovarian sex-cord tumor. *Gynecol Oncol.* 2009 Jul;114(1):140-2.
10. Abdullazade S, Kosemehmetoglu K, Adanir I, Kutluay L, Usubutun A. Uterine tumors resembling ovarian sex cord-stromal tumors: synchronous uterine tumors resembling ovarian sex cord-stromal tumors and ovarian sex cord tumor. *Ann Diagn Pathol.* 2010 Dec;14(6):432-7.
11. Staats PN, Garcia JJ, Dias-Santagata DC, Kuhlmann G, Stubbs H, McCluggage WG, De Nictolis M, Kommos F, Soslow RA, Iafrate AJ, Oliva E. Uterine tumors resembling ovarian sex cord tumors (UTROSCT) lack the JAZF1-JJAZ1 translocation frequently seen in endometrial stromal tumors. *Am J Surg Pathol.* 2009 Aug;33(8):1206-12.
12. Tavassoli FA, Devilee P. eds. World Health Organization. Pathology and genetics of tumours of the breast and female genital organs. Lyon: IARC Pres 2003, pp 217-57.

**Ozer et al.: Features of uterine tumor resembling ovarian sex-cord tumor** 140

This is an open-access article distributed under the terms of the Creative Commons Attribution License, which permits unrestricted use, distribution, and reproduction in any medium, provided the original author(s) and source are credited.

This article may be cited as: Ozer H, Aker H, Mutlu AE, Yanik A, Koc T, Keser H. CD56 might be a useful diagnostic marker of müllerian-derived tumors: report of an uterine tumor resembling ovarian sex cord tumor (utrosct) suggesting polyphenotypic origin and review of the literature. *Basic Clin Sci* 2013; 2: 132-141. Available from: [www.bcsiences.com](http://www.bcsiences.com).

13. Kim YH, Cho H, Kyeom-Kim H, Kim I. Uterine endometrial stromal sarcoma with rhabdoid and smooth muscle differentiation. *J Korean Med Sci.* 1996 Feb;11(1):88-93.
14. Elagoz S, Kivanc F, Aker H, Arici S, Ozer H, Guvenal T, Erden O. Endometrial stromal tumors – a report of 5 cases. *APJ* 2005; 2: 140-45.
15. Fdili Alaoui FZ, Chaara H, Bouguern H, Melhouf MA, Fatemi H, Belmlih A, Amarti A. Endometrial stromal nodule: report of a case. *Case Rep Med.* 2011;2011:260647.
16. Baker P, Oliva E. Endometrial stromal tumours of the uterus: a practical approach using conventional morphology and ancillary techniques. *J Clin Pathol.* 2007 Mar;60(3):235-43.
17. McCluggage WG, McKenna M, McBride HA. CD56 is a sensitive and diagnostically useful immunohistochemical marker of ovarian sex cord-stromal tumors. *Int J Gynecol Pathol.* 2007 Jul;26(3):322-7.
18. Völker HU, Engert S, Cramer A, Schmidt M, Kämmerer U, Müller-Hermelink HK, Gattenlöhner S. Expression of CD56 isoforms in primary and relapsed adult granulosa cell tumors of the ovary. *Diagn Pathol.* 2008 Jul 9;3:29.
19. Ohishi Y, Kaku T, Oya M, Kobayashi H, Wake N, Tsuneyoshi M. CD56 expression in ovarian granulosa cell tumors, and its diagnostic utility and pitfalls. *Gynecol Oncol.* 2007 Oct;107(1):30-8.
20. Deavers MT, Malpica A, Liu J, Broaddus R, Silva EG. Ovarian sex cord-stromal tumors: an immunohistochemical study including a comparison of calretinin and inhibin. *Mod Pathol.* 2003 Jun;16(6):584-90.
21. Cathro HP, Stoler MH. The utility of calretinin, inhibin, and WT1 immunohistochemical staining in the differential diagnosis of ovarian tumors. *Hum Pathol.* 2005 Feb;36(2):195-201.
22. Ordi J, Romagosa C, Tavassoli FA, Nogales F, Palacin A, Condom E, Torné A, Cardesa A. CD10 expression in epithelial tissues and tumors of the gynecologic tract: a useful marker in the diagnosis of mesonephric, trophoblastic, and clear cell tumors. *Am J Surg Pathol.* 2003 Feb;27(2):178-86.
23. He H, Luthringer DJ, Hui P, Lau SK, Weiss LM, Chu PG. Expression of CD56 and WT1 in ovarian stroma and ovarian stromal tumors. *Am J Surg Pathol.* 2008 Jun;32(6):884-90.
24. Dubeau L. The cell of origin of ovarian epithelial tumors and the ovarian surface epithelium dogma: does the emperor have no clothes? *Gynecol Oncol.* 1999 Mar;72(3):437-42.
25. Dubeau L. The cell of origin of ovarian epithelial tumours. *Lancet Oncol.* 2008 Dec;9(12):1191-7.

**Ozer et al.: Features of uterine tumor resembling ovarian sex-cord tumor** 141

This is an open-access article distributed under the terms of the Creative Commons Attribution License, which permits unrestricted use, distribution, and reproduction in any medium, provided the original author(s) and source are credited.

This article may be cited as: Ozer H, Aker H, Mutlu AE, Yanik A, Koc T, Keser H. CD56 might be a useful diagnostic marker of müllerian-derived tumors: report of an uterine tumor resembling ovarian sex cord tumor (utrosct) suggesting polyphenotypic origin and review of the literature. *Basic Clin Sci* 2013; 2: 132-141. Available from: [www.bsciences.com](http://www.bsciences.com).