

Case Report / Olgu Sunumu

Ultrasonography findings of biliary ascariasis as a rare cause of acalculous cholecystitis

Akalküloz kolesistitin nadir bir sebebi olan bilier askariasisin ultrasonografi bulguları

Mehmet H. Atalar, İsmail Şalk¹

Department of Radiology, Cumhuriyet University Faculty of Medicine, , TR-58140 Sivas

Abstract

Ascaris lumbricoides is the most common intestinal parasite to infect humans. The incidence of ascariasis is increasing in all part of the world because of world travel and population migration. *Ascaris lumbricoides* may cause various complications in the gastrointestinal system. Abdominal pain and tenderness with weight loss are the most common clinical presentations. The parasite can cause invagination at the intestinal segments and can enter the bile duct and cause cholangitis or biliary colic. Numerous studies have been published on biliary tract ascariasis. All these have documented ultrasonography (US) as the primary imaging modality for biliary ascariasis. In this report, we present US appearances in two surgical proven cases of gallbladder ascariasis.

Key words: Ascariasis, biliary tract, gallbladder, ultrasonography

Özet

Ascaris lumbricoides, insanları enfekte eden en sık intestinal parazittir. Askariasisin görülme sıklığı, göçler ve seyahatlere bağlı olarak dünya genelinde artmaktadır. *Ascaris lumbricoides*, gastrointestinal sistemde değişik komplikasyonlara neden olabilir. Kilo kaybı ile birlikte abdominal ağrı ve hassasiyet, en sık klinik başvuru yakınmalarıdır. Parazit barsak segmentlerinde invajinasyona, safra yollarına girerek kolanjit veya bilier kolik'e neden olabilir. Bilier sistem askariyazisinde çok sayıda çalışma yayınlanmıştır. Tüm bu çalışmalarda ultrasonografi (US), bilier sistem Askariyazisinde temel görüntüleme yöntemi olarak belirtilmiştir. Bu yazıda, cerrahi olarak kanıtlanmış safra kesesi yerleşimli iki Askariyazis olgusunda hastalığın US görünümünü sunuyoruz.

Anahtar sözcükler: Askariyazis, bilier sistem, safra kesesi, ultrasonografi

¹ Corresponding author:

Dr. İsmail Şalk, Radyoloji Anabilim Dalı, Cumhuriyet Üniversitesi Tıp Fakültesi, TR-58140 Sivas
Email: ismailsalk@gmail.com

Atalar and Salk: Biliary ascariasis

9

This is an open-access article distributed under the terms of the Creative Common Attribution License, which permits unrestricted use, distribution, and reproduction in any medium, provided the original author(s) and source are credited.

This article may be cited as: Atalar MH, Salk I. Ultrasonography findings of biliary ascariasis as a rare cause of acalculous cholecystitis. Basic Clin Sci 2014; 3: 9-14. Available from: dergipark.ulakbim.gov.tr/bcs/.

Introduction

Ascaris lumbricoides is one of the largest and most common parasites found in humans. It is distributed throughout Asia, Latin America, South America, Africa, and Europe. The incidence of ascariasis is increasing in all part of the world because of world travel and population migration. The adult worm usually resides in the jejunum and the infection is acquired by ingestion of embryonated eggs. Invasion into the gallbladder is very rare and accounts for 2.1% of hepatobiliary ascariasis. Ascariasis has higher infection rates compared to other parasite species. Adult worms can migrate through the biliary tract reaching the intra-hepatic ducts and the gallbladder, causing acute cholecystitis, cholangitis, biliary colic, obstructive jaundice, and hepatic abscesses. Ultrasound (US) of the abdomen has been advocated as a quick, safe, noninvasive, and relatively inexpensive modality for suspected biliary ascariasis and various appearances of roundworms in the biliary tract and gallbladder have been described [1–4]. In this report, the clinical manifestations, diagnostic procedures, and ultrasonographic appearance of gallbladder ascariasis in two patients are presented.

Cases

Case 1

A 58-year-old girl was admitted with complaints of colicky upper abdominal pain, vomiting of worms and fever with rigors and chills of seven days' duration. History revealed similar complaints one year back. There were no symptoms suggestive of peptic ulcer disease. There was no history of jaundice. Her physical examination revealed tenderness in the right upper quadrant, but no lump was palpable. She had moderate hepatomegaly. There was no splenomegaly and no free fluid in the abdomen. Bowel sounds were normal and per rectal examination revealed no abnormality. Rest of the systemic examination was also normal. Laboratory work-up results at presentation revealed mildly elevated liver enzymes (alkaline phosphatase [162 U/L; normal, 30–130 U/L]; aspartate aminotransferase, or AST [99 U/L; normal, 2–35 U/L]; and alanine aminotransferase, or ALT [72 U/L; normal, 0–45 U/L]). Blood hemoglobin concentration: 11 mg/dl, packed cell volume: 32.8%, and leucocyte count was $13 \times 10^9/l$ with mild eosinophilia. Serum amylase level was within normal limits. Blood culture for *Salmonella typhi* was negative. Urine analysis was normal. Her stool examination was positive for *Ascaris lumbricoides* ova.

Plain X-ray of the abdomen did not reveal any radioopaque shadow or any free gas under the right dome of diaphragm. Chest X-ray examination was also normal. US examination was performed. Bowel loops were distended; the gallbladder was enlarged with thickened walls and showed echogenic sludge within the lumen. The gallbladder also showed an echogenic, non-shadowing tubular structure with an anechoic tube inside (Figure.1). No collection was seen around the bladder. In addition, US showed multiple echogenic linear non-shadowing structures with central anechoic tube suggesting round worms along the dilated intrahepatic bile ducts.

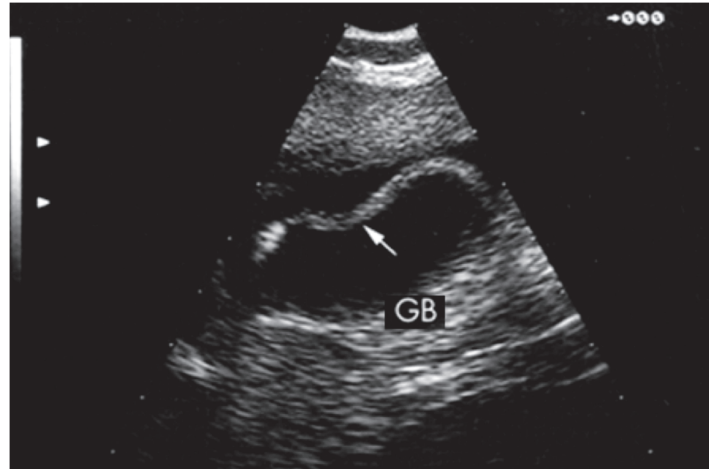


Figure 1. US of the abdomen showing *Ascaris lumbricoides* as a coiled non-shadowing echogenic structure within distended gallbladder (GB) (white arrow).

The patient was given a course of albendazole; subsequently she underwent cholecystectomy. Gallbladder contained a few membranes of worms. There were no gallstones and microscopic examination showed signs of chronic cholecystitis.

Case 2

A 16-year-old woman was admitted with an acute right upper quadrant (RUQ) colicky pain that had lasted 4 days. On physical examination, there was no jaundice or previous episode of symptoms, and vital signs were normal. There was tenderness to palpation in the RUQ. Laboratory tests were within normal limits. Real-time US examination of the abdomen was performed with 5–8 MHz convex transducer. An abdominal US showed a long and thin echogenic image with active movements within the gallbladder (Figure. 2a). No gallstones were seen and the gallbladder was normal. No collection was seen around the bladder. In addition, US showed multiple echogenic linear non-shadowing structures with central anechoic tube suggesting round worms along the dilated intrahepatic bile ducts (Figure. 2b). Based on these ultrasonographic findings, the diagnosis of ascariasis worm induced biliary colic with ascariasis cholecystitis was made. Preoperatively, the patient was given a course of albendazole. Cholecystectomy was performed and a roundworm was found within the gallbladder. There were no gallstones and microscopic examination showed signs of chronic cholecystitis.

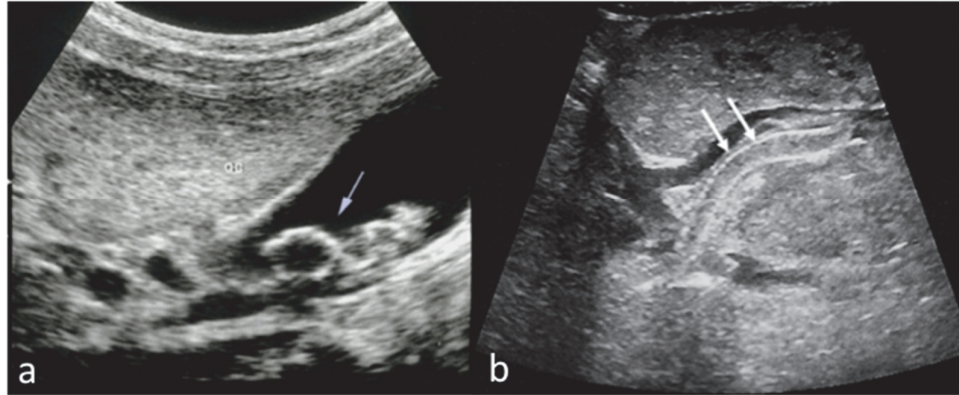


Figure 2. (a) Longitudinal US of gallbladder demonstrating *Ascaris lumbricoides* as a ribbon-like, non-shadowing echogenic structure (arrow) within the gall bladder (GB). (b) US showing markedly dilated intrahepatic bile duct. Within lumen, there are parallel echogenic lines (arrows).

Discussion

Biliary ascariasis is a known cause biliary and pancreatic system diseases in endemic areas. During the late intestinal phase of the life cycle of the parasite, one or two worms may enter the common bile duct, producing so-called acute uncomplicated biliary ascariasis. Rarely, a large number of worms may infest the biliary tree, and lead to complications such as cholangitis, granulomatous strictures, and calculi. Occasionally, penetration of the walls of the bile ducts may stimulate the formation of granulomas and abscesses in the hepatic parenchyma [4, 5].

The biliary ascariasis may be complicated or uncomplicated [2]. In uncomplicated biliary ascariasis, the clinical picture merges with that of acute acalculous cholecystitis with low-grade fever, upper abdominal colic, associated tenderness, muscle guarding in right upper quadrant with a gallbladder mass. Jaundice, hepatomegaly, and marked toxemia are usually absent. The next common presentation is of acute cholangitis with high-grade fever, right hypochondriac pain, jaundice, tender hepatomegaly raised serum bilirubin, alkaline phosphatase and ALTs [6, 7]. The cholangitis may be suppurative in some patients and the patient may present with shock.

Biliary tract ascariasis is suspected because of clinical history, physical examination, and laboratory data. A number of imaging techniques are used to investigate *Ascaris lumbricoides* infestation. Plain abdominal films are not diagnostic. Only exceptionally mature worms can be seen as tubular, soft tissue densities within the bowel gas [1, 3].

Patients with complications due to blockage of the biliary tree by *Ascaris lumbricoides* are generally diagnosed with either US or endoscopic retrograde cholangiopancreatography. US is a sensitive and specific method for detecting *Ascaris lumbricoides* in the biliary tree. On US, the worms are recognized as tube-shaped, echogenic structures within the biliary system. US offers the advantage of the ability to see the worms in real time, and as such, to recognize movement within the biliary ducts. US is also a safe and non-invasive procedure that permits the identification of the roundworm, which moves and changes position while

alive. Various appearances of roundworms in the biliary tract and gallbladder have been described.⁸ A ribbon-like, non-shadowing structure with a highly echogenic wall and a less echogenic center image at the sagittal ultrasonography of the gallbladder is strongly demonstrated as a live *Ascaris lumbricoides* in the gallbladder. Other characteristic that have been described include "spaghetti-like appearance", "impacted worm sign", "inner tube sign", "double tube sign", and "bull's eye sign" [8–10]. Acoustic shadow is generally absent, unless there were associated gallstones. The gallbladder may be normal or show signs of acute cholecystitis ultrasonographically. Dilation of the biliary tract may be evident if the worm(s) obstructs the common bile duct [10, 11]. As in our first case, in patients with cholecystitis secondary to ascariasis, US is also a useful tool to detect a thickened gallbladder wall.

False-positive ultrasonographic diagnoses may arise due to vague linear echoes in the main bile duct due to reverberations from more anterior tissue interfaces. However, these are not as well defined or as longitudinal as the stripe sign of ascariasis. In contrast to worms, the stones in the biliary tract appear as high-level echogenic structures with acoustic shadowing. While stones can also change position within bile ducts, their movement is related to changes in the posture of the patients [10, 12]

In conclusion, gallbladder ascariasis is a significant entity in endemic areas, and this disease may present as acalculous cholecystitis or empyema of the gallbladder. Although in some cases worms may migrate spontaneously back to the common bile duct. As in our cases, US seems to be an important diagnostic tool in both the diagnosis and follow-up of ascariasis of the gallbladder and biliary tree. Management of the patient can be done by establishing whether the *Ascaris lumbricoides* is alive or not. This is an advantage of ultrasonography over the other diagnostic modalities.

References

1. Shah OJ, Wani NA, Dar MA, Wani MA, Khan FA. Ascariasis-Induced Empyema of Gallbladder: Report of a Case. *Surg Today* 2002; 32: 86–8.
2. Khuroo MS. Ascariasis. *Gastroenterol Clin North Am* 1996; 25: 553–77.
3. Butts C, Henderson SO. Ascariasis. *Top Emerg Med* 2003; 25: 38–43.
4. Koumanidou C, Manoli E, Anagnostara A, Polyviou P, Vakaki M. Sonographic features of intestinal and biliary ascariasis in childhood: case report and review of the literature. *Ann Trop Paediatr* 2004; 24: 329–35.
5. Aslam M, Dore SP, Verbanck JJ, et al. Ultrasonographic diagnosis of hepatobiliary ascariasis. *J Ultrasound Med* 1993; 12: 573–6.
6. Khuroo MS, Zargar SA, Mahajan R. Hepatobiliary and Pancreatic ascariasis in India. *Lancet* 1990; 335: 1503–6.
7. Thomas PG, Ravindra KV. Amoebiasis and biliary infection. In: Blumgart LH, Fong Y, editors. *Surgery of the Liver and Biliary tract* 3rd edition. New York, Saunders W.B. Imprint-Elsevier Science; 2000, pp. 916–8.
8. Ng KK, Wong HF, Kong MS, Chiu LC, Tan CF, Wan YL. Biliary ascariasis: CT, MR cholangiopancreatography, and navigator endoscopic appearance-report of a case of acute biliary obstruction. *Abdom Imaging* 1999; 24: 470–2.
9. Cerri G, Leite GJ, Simoes JB, Correia Da Rocha DJ, et al Ultrasonographic evaluation

- of ascaris in the biliary tract. *Radiology* 1983; 146: 753-4.
10. Kamath PS, Joseph DC, Chandran R, et al. Biliary ascariasis: ultrasonography, endoscopic retrograde cholangiopancreatography, and biliary drainage. *Gastroenterology* 1986; 91: 730-2.
 11. Rodriguez EF, Gama MA, Ornstein SM, Anderson WD. Ascaris causing small bowel volvulus. *Radiographics* 2003; 23: 1291-1293.
 12. Khuroo MS, Zargar SA, Yattoo GN, et al. Sonographic findings in gallbladder ascariasis. *J Clin Ultrasound* 1992; 20: 587-91.