

**Soliter Mediyen Maksiller Santral İnsizorun Eşlik Ettiği Konjenital Nazal Piriform Aperturlu Bir Olgunun Bilgisayarlı Tomografi Bulguları**

**Computed Tomography Findings of a Case with Congenital Nasal Pyriform Aperture Stenosis Accompanied by Solitary Median Maxillary Central Incisor**

**Erkan Gökçe<sup>1</sup>, Ahmet Eyibilen<sup>2</sup>, Fatma Aktaş<sup>1</sup>, Zafer Özmen<sup>1</sup>**

<sup>1</sup>Gaziosmanpaşa University  
Faculty of Medicine,  
Department of Radiology,  
Tokat.

<sup>2</sup>Gaziosmanpaşa University  
Faculty of Medicine,  
Department of  
Otolaryngology-Head and  
Neck Surgery, Tokat.

**Yazışma Adresi:**

**Yrd. Doç. Dr. Erkan  
Gökçe**

Gaziosmanpaşa Üniversitesi  
Tıp Fakültesi,  
Rayodiagnostik Ana Bilim  
Dalı, Tokat

**Tel:** 0 5423798986

**E-mail:**

drrerkangokce@gmail.com

gopnukleertip@gmail.com

**Özet**

Konjenital nazal piriform apertur stenozu infantlarda havayolu obstrüksiyonun olağan dışı nadir bir nedenidir. Bu durum yenidoğanlarda nazal solunumu zorlaştırdığı gibi havayolu obstrüksiyonu ile yaşamı tehdit edici olabilir. Bu çalışmada doğum sonrası nefes alma ve emmede güçlüğü olan, pediatrik nazogastrik kateterin nazal pasajdan zorlanarak geçtiği, BT’inde soliter mediyen maksiller santral insizorunun eşlik ettiği konjenital nazal pyriform aperture stenosisi saptanan bir yenidoğan sunulmaktadır.

**Anahtar Kelimeler:** Bilgisayarlı tomografi, Konjenital nazal piriform apertur stenozu, Soliter mediyen maksiller santral insizor

**Abstract**

Congenital nasal pyriform aperture stenosis is a rare and an unusual cause of airway obstruction in infants. Neonates are obligate nasal breathers and nasal airway obstruction can be a life-threatening condition. In this study, it was presented an infant diagnosed with congenital nasal pyriform aperture stenosis accompanied with solitary median maxillary central incisor on CT, having difficulty in breathing and nursing after the birth and pediatric nasogastric catheter passed through the nasal passage hard.

**Key words:** Computed tomography, Congenital nasal pyriform aperture stenosis, Solitary median maxillary central incisor

## **Introduction**

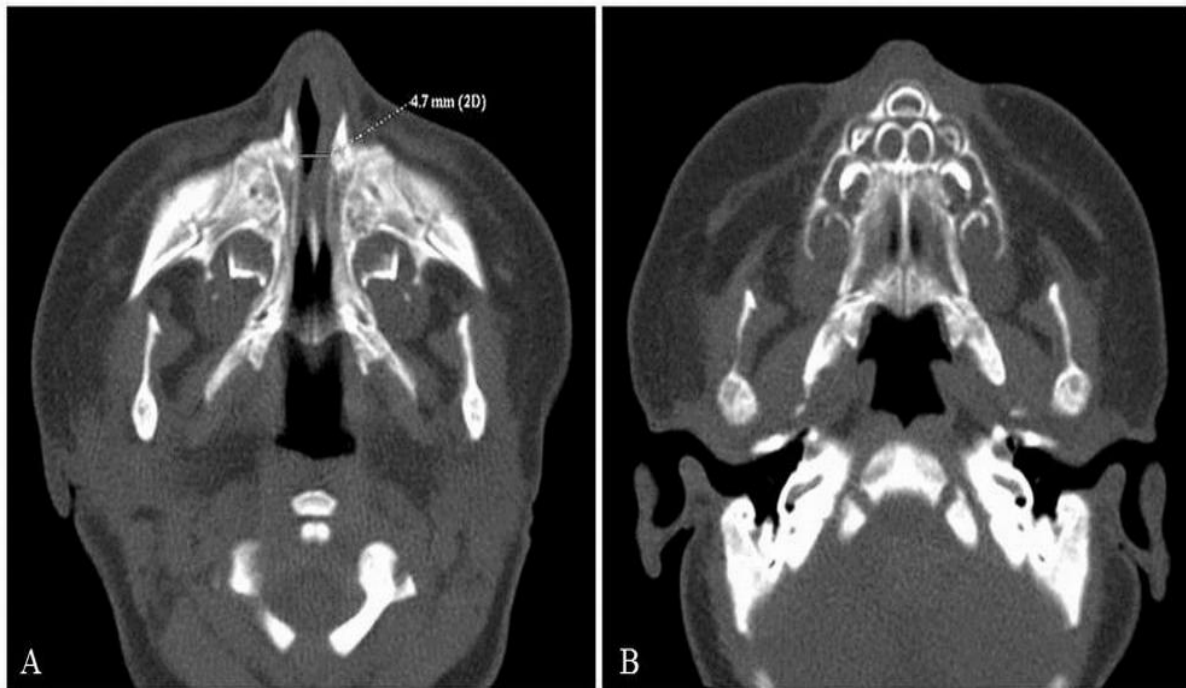
Congenital nasal pyriform aperture stenosis (CNPAS) is a rare and an unusual cause of airway obstruction in infants. Neonates are obligate nasal breathers and nasal airway obstruction can be a life-threatening condition. CNPAS is relatively new as a distinct entity (1). Its radiologic appearance was first described by Ey et al. (2) in 1988 and its clinical findings detailed by Brown et al. (3) CNPAS may be associated with solitary median maxillary central incisor; associated endocrine changes have also been described, such as growth hormone deficit, thyroid dysgenesis, hypoglycaemic episodes, and absence of the anterior pituitary with panhypopituitarism (4). We here presented an infant with CNPAS accompanied with isolated solitary median maxillary central incisor and having difficulty in breathing especially during the nursing.

## **Case Report**

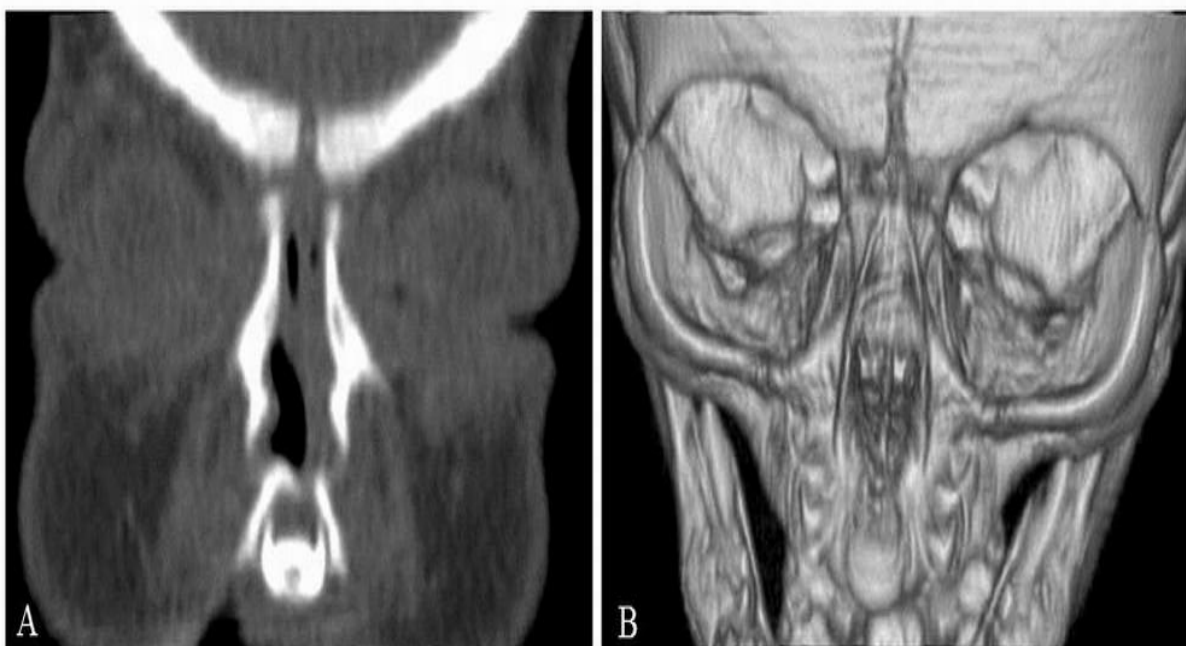One-day old baby girl born through vaginal route from a 31-year old mother had difficulty in breathing through the nose

and sucking. On ear, nose and throat examination, craniofacial, oral cavity, and oropharyngeal morphology were normal. The neck was completely normal to palpation. Pediatric nasogastric catheter could hardly be passed through the bilateral nasal passage as being harder than the left. Paranasal computed tomography (CT) scan was performed to evaluate nasal structure of the patient. A non-contrast enhanced CT scan was performed on a 8 slice multidetector CT scanner (GE LightSpeed Ultra, Milwaukee-USA) with slice thickness of 1.25 mm. CT examination revealed narrowing of the pyriform aperture (4.7 mm). Deviation pointing to the right was available in cartilage nasal septum. A significant narrowing in left nasal passage and solitary central incisor in maxillary alveolar arch were available. The hard palate was intact but hypoplastic and triangularly shaped. The posterior choanae were patent bilaterally (Figure 1 and 2). Surgical intervention was not considered for the patient for whom associated anomaly was not determined. During the 1-year follow-up of the patient, respiratory distress showed gradual decrease.

**Figure 1.** On axial plane paranasal CT image, (A) Obliteration was noticed on left nasal passage and deviation to the left on cartilage nasal septum where pyriform aperture was narrow and choanas were open. B) On the image passing through the caudal, solitary median maxillary central incisor on the maxillary alveolar arch and hard palate were noticed to be triangular shaped and mildly small.



**Figure 2.** A) On coronal plane reformatted CT image, solitary median maxillary central incisor, deviation to the left on cartilage nasal septum and obliteration in the left nasal passage were noticed. B) Solitary median maxillary central incisor and pyriform aperture stenosis were visualized on volume rendering CT image.



## Discussion

CNPAS is a rare form of neonatal nasal obstruction characterized by abnormal bony overgrowth of the nasal process of the maxilla into the nasal cavity. It originates with developmental anomalies of the midline craniofacial structures of unknown etiology (4). Types of severe nasal obstruction can result in ventilatory function impairment assuming that neonates are obligate nasal breathers; and asphyxia can be prevented through the early diagnosis (4,5). The narrowest part of nasal cavity is represented by the pyriform aperture and thus a significant increase in nasal airway resistance will cause slight variations in its caliber. Due to an infectious process of the upper airways, symptoms can appear at any time from the beginning of life until months after birth; and moreover, symptoms will vary depending upon the degree of stenosis—through the possibility of a developing life-threatening emergency. The appearing signs and symptoms of upper airway obstruction: cyclic cyanosis (which is worse with feeding and better with crying), apnoeic episodes, nasal flaring together with supraclavicular or intercostal retraction, difficulty breathing during the ingestion (4,5). These signs and symptoms can be associated with varying dysmorphic features (4). Through implementing conservative measurements to surgical intervention as a last resort, treatment will vary depending upon the severity of symptoms (4).

CNPAS diagnosis is based upon clinical evaluation that includes nasal endoscopy and CT, particularly. What is considered as diagnostic for a full-term infant is the inability to pass a 5F catheter

and a radiographically measured pyriform opening  $< 8\text{--}10$  mm (5). The differential diagnosis includes other forms of neonatal nasal obstruction, whether acquired pathologies, such as mucosal oedema secondary to rhinitis or hypertrophy of the concha, or congenital pathologies such as choanal atresia, stenosis of the nasal cavity associated with craniofacial anomalies, midnasal stenosis, or lacrimal sac mucocele (4). If holoprosencephaly is suspected by the presence of a central maxillary incisor, transcranial ultrasonography, cerebral CT or magnetic resonance imaging should also be performed (5).

Consequently, CNPAS should be considered as the differential diagnosis, although it is rarely seen in infants having difficulty in breathing especially during the nursing and CT examination should be performed in order to diagnose in anomalies such as solitary median maxillary central incisor that can accompany.

## References

1. Shikowitz MJ. Congenital nasal pyriform aperture stenosis: diagnosis and treatment. *Int J Pediatr Otorhinolaryngol.* 2003;67:635-9.
2. Ey EH, Han BK, Towbin RB, Jaun W. Bony inlet stenosis as a cause of nasal airway obstruction, *Radiology.* 1988;168:477-9.
3. Brown OE, Myer CM, Manning SC. Congenital nasal pyriform aperture stenosis. *Laryngoscope.* 1989;99:86-91.
4. Gimeno-Hernández J, Iglesias-Moreno MC, Gómez-Serrano M, Poch-Broto J. Congenital nasal

pyriform aperture stenosis and solitary maxillary central incisor: case report. *Acta Otorrinolaringol Esp.* 2010;61:455-8.

5. Sesenna E, Leporati M, Brevi B, Oretti G, Ferri A. Congenital nasal pyriform aperture stenosis: diagnosis and management. *Ital J Pediatr.* 2012;26;38:28.

