



The Effects of Magnetic Fields Created by Mobile Phones on In Vitro Embryo Development

Nihal Gurlek Celik¹, Harun Ulger², Mehtap Nisari²

¹Amasya University, Faculty of Medicine, Department of Anatomy, Amasya, Türkiye

²Erciyes University, Faculty of Medicine, Department of Anatomy, Kayseri, Türkiye

Content of this journal is licensed under a Creative Commons Attribution-NonCommercial-NonDerivatives 4.0 International License.



Abstract

Aim: The risks to public health of radiofrequency signals emitted by mobile phones, an indispensable part of our daily lives, have begun to be questioned. For this reason, the magnetic field created by a third-generation mobile phone was applied to the embryos obtained by in vitro embryo culture technique during the organogenesis period of the rat embryo and its effect on development was examined.

Material and Method: In our study, 20 adult female rats weighing between 200-300 g and 30 male Wistar albino rats weighing over 300 g were used. The developmental morphology of embryos from the control and experimental groups exposed to magnetic fields for different periods (24 hours, 48 hours) was evaluated.

Results: When the morphological score, yolk sac diameter, crown-rump length and number of somites of embryos exposed to magnetic fields for different periods were compared, the experimental groups regressed compared to the control group.

Conclusion: As a result, it was shown that developmental delays and deformities may occur in embryos depending on the duration of exposure to the magnetic field.

Keywords: 3G mobile phone, embryo development, in vitro, magnetic field, rat

INTRODUCTION

With the development of technology, many electronic equipment that we commonly use in daily life, such as mobile phones, tablets, and Wireless Fidelity (Wi-Fi) communication devices, create Electromagnetic fields (EMF) at different levels (1, 2). While the lowest frequency of these EMFs is 3-30 Hertz (Hz), 50-60 Hz, which is frequently encountered in daily life, the frequency range of mobile phones, which are the most dangerous and widely used for humans, is hundreds of Megahertz (MHz) (3). Mobile phones, a part of the electromagnetic spectrum, are the most common sources of radiofrequency fields (4). Mobile communication services are a major concern for people as they are the fastest-growing area in the telecommunications industry (5,6). It has been stated that mobile phones operate between 300 MHz and 3 GHz (Gigahertz) within the Global Mobile Communications System (GSM) (7). Mobile phones with third-generation telephone (3G) technology are known to be in the frequency range of 1900 MHz to 2200 MHz (4).

The effect of EMF on living organisms began to be investigated in 1961 (8). The biological effects of exposure to EMF have been discussed for years (9). It has been reported that individuals using mobile phones may affect the nervous system due to EMF exposure, especially in the head area (10-13). Additionally, it has been reported that there are impairments in the synaptic transmission of pyramidal neurons in the prefrontal cortex of mice exposed to radiation generated by mobile phones in intrauterine life (14).

Studies have shown that mice exposed to 900 MHz mobile phone radiation for 1 hour stimulated tooth germ cells and caused teeth to erupt before the normal time (4). Studies conducted on living organisms have reported that both in vivo and in vitro studies in the 900-1800 MHz range cause Deoxyribonucleic acid (DNA) damage (15). Another study reported differences in the kidney, liver, and eye tissues of animals exposed to second-generation (2G) or 3G mobile phone radiation (16-19).

CITATION

Gurlek Celik N, Ulger H, Nisari M. The Effects of Magnetic Fields Created by Mobile Phones on In Vitro Embryo Development. Med Records. 2024;6(3):449-55. DOI:1037990/medr.1511651

Received: 06.07.2024 **Accepted:** 27.08.2024 **Published:** 12.09.2024

Corresponding Author: Nihal Gurlek Celik, Amasya University, Faculty of Medicine, Department of Anatomy, Amasya, Türkiye

E-mail: nihalg.celik@gmail.com

This study aims to investigate the systemic effects of radiation generated by 3G mobile phones on in vitro embryo development.

MATERIAL AND METHOD

Approval for this study was obtained with the decision of Erciyes University, Experimental Animals Ethics Committee, numbered 07/07 and dated 10.10.2007. In the study, 20 adult female rats weighing between 200-300 g and 30 male Wistar albino rats weighing over 300 g were used. Embryo culture was performed according to the procedures of New (20).

Embryo Culture

Female and male rats were kept in cages in groups of five, and their water and nutritional needs were provided in the normal order of the day. 4-10 month old females weighing 200-300 g were kept in a cage overnight (between 5.00 pm and 8.00 am) with males capable of fertilisation. In the morning, vaginal smears were taken from the females, and it was checked whether there was sperm. A vaginal smear was performed on females in the morning. Females in which sperm was seen were considered 0.5 days pregnant, fed normally, and kept for 9 days. Pregnant rats were anaesthetised using diethyl ether. When it was observed that the cornea and foot reflexes were absent, it was decided that anaesthesia had been achieved. The anterior abdominal walls of the rats were disinfected with 70% alcohol. A V-shaped incision was made over the pubis towards the arches of both ribs, and the anterior abdominal wall was opened. Blood was taken from the bifurcation of the visible abdominal aorta with a sterile syringe and centrifuged at 3500 revolutions per minute for 5 minutes. Thus, the serum to create the culture medium was obtained. At the same time, the embryo sacs located in the uterine horn were cut one by one and placed in a sterile petri dish containing Hanks' salt solution. Subsequent processes were carried out in a Lamin-air flow cabinet and under a stereo microscope for a sterile environment. With the help of sterile forceps, the muscle layer and decidua layer on the uterine wall were removed. A frontal section was made in the decidua tissue and carefully removed without damaging the embryo on one side. In the second stage, the Reicherts membrane was removed from the embryonal pole and transferred to a sterile petri dish containing embryo medium (Figure 1).

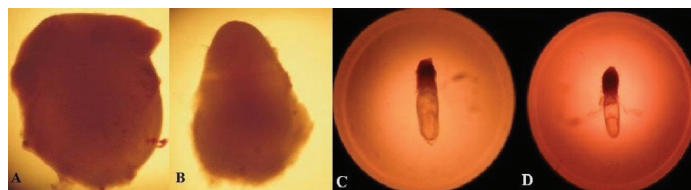


Figure 1: A. Endometrial tissue B. Decidua C. Embryo with Reicherts membrane D. Embryo with Reicherts membrane removed

Formation of Experimental Groups

Embryos obtained from pregnant rats were divided into one control and two experimental groups. Our study cultured embryos according to New's procedures (20).

Control group: Embryos in this group (n: 14) were cultured in rat serum for 48 hours without being subjected to any magnetic field.

Experimental group 1: Embryos in this group (n: 15) were exposed to a magnetic field created by a 3G mobile phone placed in an oven incubator with rollers inside and set at 37°C in the first 24 hours of the 48-hour culture period.

Experimental group 2: Embryos in this group (n: 15) were exposed to the magnetic field created by the mobile phone throughout the 48-hour culture period.

In the experimental groups, a third-generation mobile phone was placed vertically in the oven on a perforated mechanism with dimensions of 15x10 cm. The mobile phone was vibrated, the Wireless Local Area Network (WLAN) and Bluetooth settings were kept on, and an uninterrupted call was made for 2 minutes every hour. At the end of the 48-hour culture period, embryos were taken from the culture bottles and evaluated morphologically under a stereomicroscope, and the results were compared with the control group.

According to the morphological scoring system developed by Van Maele-Fabry et al. (21), respectively. The yolk sac vascularisation, allantois, flexion, heart, caudal neural tube, hindbrain, midbrain, forebrain, branchial bar, olfactory, otic and optic system, maxillary and mandibular processes, forelimbs, hindlimbs, and somites were examined. The development of 17 parameters was evaluated by giving points between 1 and 5. The yolk sac diameter, embryo crown-rump length, number of somites, and total morphological score values obtained from morphological scoring were recorded.

Statistical Analysis

Descriptive statistics were given as a unit number (n), mean \pm standard deviation. The normal distribution of data belonging to numerical variables was evaluated with the Shapiro-Wilk normality test. The variance homogeneity of the groups was assessed using the Levene test. Comparisons between groups for numerical variables were made with a one-way analysis of variance. SPSS 15.0 package program was used for statistical analysis. $p < 0.05$ was considered statistically significant.

RESULTS

As a result of our study, when the embryos grown in a culture environment for 48 hours were evaluated morphologically. The developmental disorder in the embryos kept for 48 hours in the magnetic field created by the mobile phone (Experimental Group 2) was more pronounced than the developmental disorder in the embryos kept for 24 hours (Experimental Group 1) compared to the control group.

In the experimental groups, it was determined that the embryos exposed to the magnetic field created by the mobile phone showed an increase in the average total morphological score, number of somites, yolk sac diameter and crown-rump length, depending on the duration of exposure to the magnetic field (Table 1).

Table 1. Effects of the magnetic field created by a mobile phone on in vitro embryonic rat embryo development

	N	Control group	Experimental Group 1 (Embryos exposed to magnetic field for 24 hours)	Experimental Group 2 (Embryos exposed to magnetic field for 48 hours)
Total morphological score	14	53.00±6.59	41.13±7.32***	37.26±5.92***
Number of somites	15	21.4±4.04	16.8±2.14***	15.4±1.72***
Yolk sac diameter (mm)	15	3.40±1.46	2.39±0.40**	1.88±0.36***
Embryo crown-rump length (mm)	15	2.77±1.21	2.06±0.41*	1.64±0.20***

Results show mean values±standard deviation; *P<0.05, **P<0.01, ***P<0.001 (compared to the control group)

In most of the embryos in the control group, many thin branches were seen on the main vessel on the yolk sac. While there were a few thin vessels in the yolk sac in experimental group 1, there were prominent blood islands in the yolk sac in experimental group 2 (Figure 2).

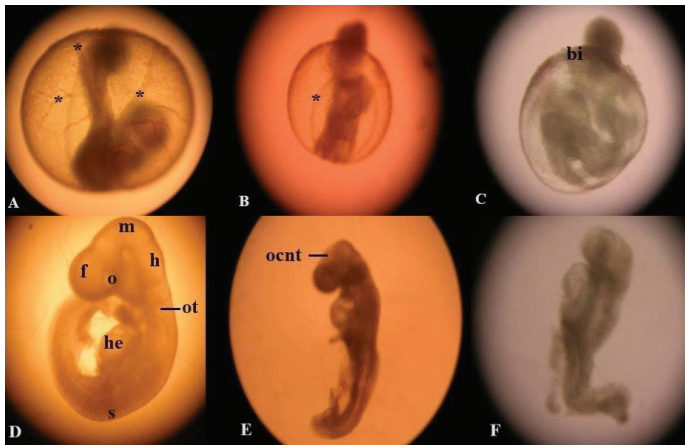


Figure 2. Embryos in the yolk sac; **A.** 11.5-day-old rat embryos growing in normal culture medium (* Blood vessels); **B.** 11.5-day-old rat embryos exposed to the EMF of a mobile phone for 24 hours (* Blood vessels); **C.** 11.5-day-old rat embryos exposed to the EMF of a mobile phone, for 48 hours (bi: blood island); **D.** 11.5-day-old rat embryos with yolk sac dissected; **E.** 11.5-day-old rat embryos growing in normal culture medium; f: forebrain, m: midbrain, h: hindbrain, o: optic vesicle, ot: otic vesicle, he: heart, s: somite **E.** 11.5-day-old rat embryos exposed to mobile phone EMF for 24 hours, ocnt: open cranial neural tube **F.** 11.5-day-old rat embryos exposed to mobile phone EMF for 48 hours (Not fully developed)

When looking at heart development, the heart was mostly three-chambered in the control group embryos, while the bulbus cordis, atrium, and ventricle were separate and distinct in experimental groups 1 and 2 (Table 2). When the forebrain development of the embryos was examined, it was seen that the most development was in

the control group (the prosencephalon of 6 embryos was united entirely). In comparison, there was a regression in experimental groups 1 and 2 (the prosencephalic fold was partially closed in 6 and 9 embryos, respectively). Caudal neural tube development was highest in the control group (there was a small opening in the posterior neuropore in 6 embryos, and the posterior neuropore was open and shaped in 8 embryos), in most of the embryos in experimental groups 1 and 2, it was observed that the neural fold was united at the level of 4-5 somites and the caudal neural tube was open (Table 3).

While optic vesicle development occurred in 12 embryos in the control group and the optic stalk was open, this was seen in 6 embryos in experimental group 1 and 2 embryos in experimental group 2. As for otic vesicle development, it was observed that the astrocyte was located dorsally in 2 embryos in the control group, and the otic vesicle was separated from the epidermis in 12 embryos. It was observed that the development of the embryos in experimental groups 1 and 2 did not reach this level. In addition, it was found that the otic vesicle was not separated from the epidermis in most experimental groups embryos (Table 4).

The highest improvement in the branchial bar and maxillary process, was observed in the control group, experimental group 1, and experimental group 2, respectively. In front limb development, all embryos in the control group had budded limbs; It was observed that the front extremities of some of the embryos in the experimental groups were budded, while some of them were curved outwards at the level of 9 to 13 somites. While the situation was the same in the development of the hind limb, the only difference was that the hind limb was curved outwards at the level of 26 to 30 somites (Table 5).

Table 2. Effects of the magnetic field generated by a mobile phone on the development of yolk sac vessels and heart of in vitro embryonic rat embryos

Groups	N	Vitellus sac vessels development				Heart development				
		(0) Yolk sac vessels or blood islands are prominent	(1) Blood islands are evident around the ectoplacental cone.	(2) A few thin vessels on the yolk sac	(3) The vascular network is prominent in the yolk sac	(4) Many thin branches on the main vessel	(2) S-shaped heart tube	(3) Bulbus cordis, atrium and ventricle separate and distinct	(4) 3 chambered heart	(5) 4 chambered heart
Control group	14	-	2	-	2	10	1	6	7	-
Experimental group 1	15	4	1	5	4	-	6	9	-	-
Experimental group 2	15	5	4	3	2	-	7	8	-	-

Table 3. Effects of the magnetic field generated by a mobile phone on the development of the forebrain and caudal neural tube of the in vitro embryonic rat embryo

Groups	N	Forebrain development					Caudal neural tube development			
		(2) U-shaped neural fold	(3) Proencephalic fold partially fused	(4) Prosencephalon fully united	(5) Telencephalic evagination view	(1) The neural layer is closed and united with the neural layer	(2) Neural folds are united at the level of 4-5 somites	(3) Posterior neuropore open but unformed	(4) A small opening in the posterior neuropore	
Control group	14	-	3	6	5	-	-	8	6	
Experimental group 1	15	3	6	4	2	2	7	6	-	
Experimental group 2	15	3	9	3	-	-	11	4	-	

Table 4. Effects of the magnetic field generated by a mobile phone on the development of yolk sac vessels and heart of in vitro embryonic rat embryos

Groups	N	Eye development				Ear development				
		(1) Eye groove	(2) Elongated optical promordium	(3) Oval shaped optical promordium	(4) The optic vesicle has formed and the optic stalk is open.	(2) Otic fossa	(3) Otic vesicle closed but not separated from epidermis	(4) Otic vesicle separated from epidermis	(5) Autocyte settled dorsally	
Control group	14	-	-	2	12	-	2	10	2	
Experimental group 1	15	1	5	3	6	-	8	7	-	
Experimental group 2	15	1	9	3	2	1	11	3	-	

Table 5. Effects of magnetic field generated by mobile phone on branchial bar, maxillary process, forelimbs and hindlimbs extremity development of in vitro embryonic rat embryos

Groups	N	Branchial bar			Maxillary processes			Forelimb development			Hindlimb development		
		(1) 1 branchial bar	(2) 2 branchial bar	(3) 3 branchial bar	(1) Rudimentary bar separated from the anterior head	(2) Maxillary process with branchial bar processes inwards	(3) A layer between the mandibular process and the forebrain	(1) At the level of 9-13th somites	(2) Forelimbs bud shaped	(3) Forelimbs are paddle-shaped	(1) At the level of 26-30th somites	(2) Hindlimbs bud shaped	(3) Hindlimbs are paddle-shaped
Control group	14	1	13	-	-	11	3	-	14	-	8	6	-
Experimental group 1	15	7	8	-	3	12	-	8	7	-	9	6	-
Experimental group 2	15	13	2	-	7	8	-	11	4	-	12	3	-

DISCUSSION

It is stated that exposure to radiation in the 900 MHz frequency range affects the central nervous system (22, 23). In animal model studies, it has been reported that the number of cells in the hippocampus region of rats exposed to EMF before birth is significantly reduced (24). Another in vitro study reported differences in blood-brain barrier permeability at 900 MHz (25,26). In our study, the morphological scoring method, which includes 17 embryonic development parameters, was used to determine the total development levels of rat embryos. When the morphological score results showing total

embryonic development were compared, it was seen that there was a significant regression in the experimental groups compared to the control group (morphological score: 61.7 ± 1.75). It was determined that the developmental disorder was more in experimental group 2 (morphological score; 44.5 ± 4.10), which was exposed to the magnetic field for a longer time (48 hours), and was relatively less in the embryos in experimental group 1 (morphological score: 57.6 ± 2.64), which was exposed to the magnetic field for a shorter time.

The formation of the vascular system is very important in embryo development and growth processes. Because

disruption of this functional system will not be able to provide the necessary oxygen and nutrients to the organism or even remove waste products (27). A study reported that vascular occlusion, changes in vascular smooth muscles, thickening of the intima layer, and inflammation in the adventitia layer occurred after radiation exposure (28). In another study, the testicles of rats exposed to mobile phone radiation (1.58 Specific Absorption Rate (SAR)) for a long time were examined with electron and light microscopy. It has been reported that the capillaries of rats dilate after exposure (29). In his histopathological study, Mercantepe et al. (30) examined the kidney tissue of rat embryos. It has been reported that embryos exposed to 6-Gray (Gy) ionizing radiation (IR) have vascular occlusion in the intercellular space. In another study, thickening was reported in the renal vessel walls of rats exposed to EMF at 900/1800 MHz, 2400 MHz, and 8Gy x-ray frequencies (31). Our study observed that the experimental groups exposed to 3G mobile phones had a few thin vessels or prominent blood islands in the yolk sac, depending on the exposure time.

Türedi et al. (32) examined the heart tissue of male baby rats in the prenatal period to which 900 MHz radiation was applied. Another study analysed the heart tissue of rats exposed to 50 Hz radiation (33). In both studies, it was reported that EMF caused apoptosis in heart tissue. In one part of their study, Adebayo et al. (34) examined mice's heart muscles and fibres by exposing them to mobile phones for certain periods. It has been reported that in mice exposed to 900 MHz radiation, there is an increase in the gaps between heart fibres and irregular heart muscle and contractions. In our study, three-chambered heart development was observed only in the embryos of the control group. Although the scores of the embryos in the experimental group were similar to each other, only the development of the heart tube, bulbus cordis, atrium, and ventricle were seen to be separate/distinct. It was observed that exposure to magnetic fields affected heart development.

When using a mobile phone, the ear and brain are affected by EMF. It has been stated that the rate of tumours such as neuroma and glioma may increase as a result of exposure to EMF. In addition, it may cause effects such as irreversible hearing problems (35) and acoustic neuroma (36). In a study, it was reported that rat embryos irradiated with a dose of 1 Gy had a lack of fusion in the nerve folds, developmental delay in the otic vesicle, olfactory systems were not sufficiently developed, and the neural tubes remained open in the caudal and cranial regions (37). Similarly, in our study, while developmental delay was observed in the otic vesicle, the presence of open but unformed posterior neuropores of the caudal neural tubes showed that there was not sufficient development.

The study of D'Silva et al. (38) reported that the radiation emitted by the 2G mobile phone causes conditions such as deterioration in the lens fibres and epithelium of the

chick embryo and the formation of cystic cells and cavities. In another study, male Wistar albino rats were exposed to radiation emitted by a 3G mobile phone for 20 days (exposure time 20 minutes a day), and their eye tissues were examined. It has been reported that such short-term exposure does not harm the eye tissue of rats (39). In addition, it has been stated that the radiation emitted by a mobile phone at a frequency of 900 MHz for four weeks causes oxidative stress in the cornea and lens tissues (16). In the study of Balcıoglu et al. (37), it was reported that there was a developmental delay in the otic vesicle of rats exposed to ionising radiation. In our study, delayed development of optical systems was detected in direct proportion to the duration of exposure to the magnetic field. We think the reason for the differences is not the duration of radiation exposure alone but may be related to the effect of the SAR value.

Limitations

Although we express the limitations of our study as sample size, duration of exposure to mobile phones, exposure conditions and the unknown effects of radiation created by the development of wireless technology in recent years on embryo development, we think this study will contribute to subsequent studies.

CONCLUSION

The embryos' development in our study's control group was better than in the experimental group. When compared, the experimental groups showed development directly proportional to the duration of radiation exposure. As far as we have found in the literature, many histopathological studies exist. Studies investigating the systemic effects of radiation generated by 3G mobile phones on embryos are quite limited. With the development of technology, more work is needed in this field.

This research was produced from Nihal Gürlek Çelik's Master's thesis, "The Effects of Magnetic Fields Created By Mobile Phones on In Vitro Embryo Development".

Financial disclosures: *This study was supported by the Erciyes University Scientific Research Projects Unit with project number TSY-08-397.*

Conflict of interest: *The authors have no conflicts of interest to declare.*

Ethical approval: *Erciyes University Experimental Animals Ethics Committee gave ethical approval (numbered 07/07 and dated 10.10.2007).*

REFERENCES

1. Margaritis LH, Manta AK, Kokkaliaris KD, et al. Drosophila oogenesis as a bio-marker responding to EMF sources. *Electromagn Biol Med.* 2014;33:165-89.
2. Singh S, Kapoor N. Health implications of electromagnetic fields, mechanisms of action, and research needs. *Adv Biol.* 2014;2014:198609.

3. Dawson BV, Robertson IG, Wilson WR, et al. Evaluation of potential health effects of 10 kHz magnetic fields: a rodent reproductive study. *Bioelectromagnetics*. 1998;19:162-71.
4. Berto FH, Al-Hijazi AY. Evaluation of 900 mhz mobile phone effects on palate and tooth germ development in the mouse embryo (histological & immunohistochemical study). *J Bagh College Dentistry*. 2012;24:39-46.
5. Gautam R, Singh KV, Nirala J, et al. Oxidative stress-mediated alterations on sperm parameters in male Wistar rats exposed to 3G mobile phone radiation. *Andrologia*. 2019;51:e13201.
6. Sienkiewicz Z. Biological effects of electromagnetic fields and radiation. *J Radiol Prot*. 1998;18:185-93.
7. CENELEC. European Committee for Electrotechnical Standardization. Product standard to demonstrate the compliance of mobile phones with the basic restrictions related to human exposure to electromagnetic fields (300 MHz–3 GHz) 2001.
8. Stasinopoulou M, Fragopoulou AF, Stamatakis A, et al. Effects of pre-and postnatal exposure to 1880-1900MHz DECT base radiation on development in the rat. *Reprod Toxicol*. 2016;65:248-62.
9. Gye MC, Park CJ. Effect of electromagnetic field exposure on the reproductive system. *Clin Exp Reprod Med*. 2012;39:1-9.
10. Frey AH. Headaches from cellular telephones: are they real and what are the implications?. *Environ Health Perspect*. 1998;106:101-3.
11. Kaplan S, Deniz OG, Onger ME, et al. Electromagnetic field and brain development. *J Chem Neuroanat*. 2016;75:52-61.
12. Altun G, Kaplan S, Deniz OG, et al. Protective effects of melatonin and omega-3 on the hippocampus and the cerebellum of adult Wistar albino rats exposed to electromagnetic fields. *J Microsc Ultrastruct*. 2017;5:230-41.
13. Deniz OG, Kaplan S, Selçuk MB, et al. Effects of short and long-term electromagnetic fields exposure on the human hippocampus. *J Microsc Ultrastruct*. 2017;5:191-7.
14. Aldad TS, Gan G, Gao XB, Taylor HS. Fetal radiofrequency radiation exposure from 800-1900 mhz-rated cellular telephones affects neurodevelopment and behavior in mice. *Sci Rep*. 2012;2:312. Erratum in: *Sci Rep*. 2013;3:1320.
15. Akdag M, Dasdag S, Canturk F, Akdag MZ. Exposure to non-ionising electromagnetic fields emitted from mobile phones induced DNA damage in human ear canal hair follicle cells. *Electromagn Biol Med*. 2018;37:66-75.
16. Balci M, Devrim E, Durak I. Effects of mobile phones on oxidant/antioxidant balance in cornea and lens of rats. *Curr Eye Res*. 2007;32:21-5.
17. Mugunthan N, Anbalagan J, Meenachi S, Shanmuga Samy A. Exposure of mice to 900-1900 MHz radiations from cell phone resulting in microscopic changes in the kidney. *Int J Cur Res Rev*. 2014;6:44-9.
18. Mugunthan N, Anbalagan J, Meenachi S, Rajanarayanan S. Structural changes observed in mice liver due to chronic exposure of 1900-2200 MHz radiations emitted from mobile phone. *Int J Anat Res*. 2019;7:6254-60.
19. D'Silva MH, Swer RT, Anbalagan J, Rajesh B. Effect of radiofrequency radiation emitted from 2G and 3G cell phone on developing liver of chick embryo-A comparative study. *J Clin Diagn Res*. 2017;11:AC05-9.
20. New DAT. Whole embryo culture and the study of mammalian embryos during organogenesis. *Biol Rev Camb Philos Soc*. 1978;53:81-122.
21. Van Maele-Fabry G, Delhaise F, Picard JJ. Morphogenesis and quantification of the development of post-implantation mouse embryos in vitro. *Toxicol In Vitro*. 1990;4:149-56.
22. Bas O, Sönmez OF, Aslan A, et al. Pyramidal cell loss in the cornuammonis of 32-day-old female rats following exposure to a 900 megahertz electromagnetic field during prenatal days 13-21. *Neuro Quantology*. 2013;11:591-9.
23. Şahin A, Aslan A, Baş O, et al. Deleterious impacts of a 900-MHz electromagnetic field on hippocampal pyramidal neurons of 8-week-old Sprague Dawley male rats. *Brain Res*. 2015;1624:232-8.
24. Bas O, Odaci E, Mollaoglu H, et al. Chronic prenatal exposure to the 900 megahertz electromagnetic field induces pyramidal cell loss in the hippocampus of newborn rats. *Toxicol Ind Health*. 2009;25:377-84.
25. Salford LG, Brun AE, Eberhardt JL, et al. Nerve cell damage in mammalian brain after exposure to microwaves from GSM mobile phones. *Environ Health Perspect*. 2003;111:881-3.
26. Nittby H, Brun A, Eberhardt J, et al. Increased blood-brain barrier permeability in mammalian brain 7 days after exposure to the radiation from a GSM-900 mobile phone. *Pathophysiology*. 2009;16:103-12.
27. Jin SW, Beis D, Mitchell T, et al. Cellular and molecular analyses of vascular tube and lumen formation in zebrafish. *Development*. 2005;132:5199-209.
28. Bouten RM, Young EF, Selwyn R, et al. Effects of radiation on endothelial barrier and vascular integrity. In *Tissue Barriers in Disease, Injury and Regeneration*; Elsevier: Amsterdam, The Netherlands, 2021;43-94.
29. Çelik S, Aridogan IA, Izol V, et al. An evaluation of the effects of long-term cell phone use on the testes via light and electron microscope analysis. *Urology*. 2012;79:346-50.
30. Mercantepe T, Topçu A, Rakıcı S, et al. The radioprotective effect of N-acetylcysteine against x-radiation-induced renal injury in rats. *Environ Sci Pollut Res Int*. 2019;26:29085-94.
31. Borzoueisileh S, Shabestani Monfared A, Ghorbani H, et al. Combined effects of radiofrequency electromagnetic fields and X-Ray in renal tissue and function. *Res Rep Urol*. 2020;29:12:527-32.
32. Türedi S, Hancı H, Topal Z, et al. The effects of prenatal exposure to a 900-MHz electromagnetic field on the 21-day-old male rat heart. *Electromagn Biol Med*. 2015;34:390-7.
33. Kiray A, Tayefi H, Kiray M, et al. The effects of exposure to electromagnetic field on rat myocardium. *Toxicol Ind Health*. 2013;29:418-25.
34. Adebayo EA, Adeyo AO, Ogundiran MA, Olabisi O. Bio-physical effects of radiofrequency electromagnetic radiation (RF-EMR) on blood parameters, spermatozoa, liver, kidney and heart of albino rats. *J King Saud Univ- Sci*.

- 2019;31:813-21.
35. Ongel K, Mergen H, Gürbüz T. Elektrik çarpmalarına yaklaşım: literatür taraması. *Dirim Tıp*. 2007;82:369-401.
36. Salahaldin AH, Bener A. Long-term and frequent cellular phone use and risk of acoustic neuroma. *Int Tinnitus J*. 2006;12:145-8.
37. Balcıoğlu E, Baran M, Nisari M, et al. Ionizing radiation effects in vitro study; using the rat whole embryo culture model. *Gevher Nesibe Journal of Medical and Health Sciences*. 2022;6:91-100.
38. D'Silva MH, Swer RT, Anbalagan J, Bhargavan R. Effect of ultrahigh frequency radiation emitted from 2G cell phone on developing lens of chick embryo: a histological study. *Advances in Anatomy*. 2014;1-9.
39. Demirel S, Doganay S, Turkoz Y, et al. Effects of third generation mobile phone-emitted electromagnetic radiation on oxidative stress parameters in eye tissue and blood of rats. *Cutan Ocul Toxicol*. 2012;31:89-94.