

Evaluation of neuroophthalmologic examination in cats and dogs: A retrospective study: 110 cases (2023)

Özlem Şengöz Şirin¹, Muhammed Yusuf Şirin¹, Ayşe Nihan Elvan²

¹Department of Surgery, Faculty of Veterinary Medicine, Burdur Mehmet Akif Ersoy University, Burdur, Türkiye

²Department of Surgery, Institute of Health Sciences, Burdur Mehmet Akif Ersoy University, Burdur, Türkiye

Key Words:

cat
dog
eye
neuro-ophthalmology

Received : 11 November 2023
Revised : 14 February 2024
Accepted : 21 February 2024
Published : 12 June 2024
Article Code : 1389467

Correspondence:

Ö. ŞENGÖZ ŞİRİN
(ozlemsirin@mehmetakif.edu.tr)

ORCID

Ö. ŞENGÖZ ŞİRİN : 0000-0002-2232-6349
MY. ŞİRİN : 0000-0002-7419-5774
AN. ELVAN : 0009-0006-2175-2721

ABSTRACT

This retrospective study includes 20 cats and 90 dogs brought to the Surgical Clinic of Burdur Mehmet Akif Ersoy University Faculty of Veterinary Medicine Animal Hospital with various diseases between January and June 2023. In addition to routine eye examinations, neuro-ophthalmological examinations (nystagmus, strabismus, pupillary light reflex, palpebral reflex, corneal reflex, menace reflex, dazzle reflex) were performed on the patients, and the results of neuro-ophthalmological and routine eye examinations were evaluated retrospectively. Of the cats examined, 55% had pathology on routine ophthalmologic examination and 45% had pathology on neuro-ophthalmologic examination. Pathology was detected in 52.22% of dogs on routine ophthalmologic examination and 22.22% on neuro-ophthalmologic examination. One dog with microphthalmia could not be examined. This study aimed to investigate the prevalence of neuroophthalmological diseases in dogs and cats. This study showed that many neuro-ophthalmological diseases are likely to be overlooked during the examination, and diagnosis may be difficult. Therefore, neuroophthalmological examinations should be added to routine ophthalmological examinations.

INTRODUCTION

Neuro-ophthalmology is a discipline that examines the complex relationship between the eye and the central nervous system. In this field, a comprehensive understanding of the afferent and efferent pathways is crucial for the localization and diagnosis of neuro-ophthalmological disorders. Abnormalities in the afferent or efferent pathways can lead to changes in vision, eye position, tear production, eye function, sensation, and pupil size, shape, or response. These changes manifest as symptoms of neuro-ophthalmological disorders (Bruyette, 2020; Holmberg, 2020).

Neuro-ophthalmic examination combines neurological examination and ophthalmic evaluation to detect eye disorders arising from neurological diseases. Evaluating the visual system from a neurological perspective is fascinating and unique because components like the retina and optic disc can be observed in a normal patient through neurological examination. Therefore, even in cases where clear neuro-ophthalmic abnormalities are absent, the underlying cause of neurological disease can be determined through a comprehensive assessment of the eyes. This is particularly important for inflammatory and infectious central nervous system diseases (Penderis, 2013; Platt and Olby, 2014).

Especially in cats and dogs; nystagmus (rotatoric, vertical, horizontal, positional), strabismus, anisocoria, pupillary light reflex, swinging flashlight test, dazzle reflex, cotton test, threat reflex, palpebral reflex, corneal reflex are used as diagnostic tests and findings in the detection of problems encountered in

neuro-ophthalmological diagnosis.

In the dazzle reflex, when a strong light is shone on the eye, a slight enlargement and shrinkage occurs in both eyes and the reaction tends to be weaker. The afferent branch is the optic nerve, while the efferent branch of this reflex is the facial nerve (Spiess, 2019). The menace response is provided by a threatening gesture to the eye of interest while the other eye is closed. The first afferent component of the threat response is the retina and therefore an intact ocular environment is required for the initial stimulation of the pathway. The response is transmitted from the retina to the visual cortex via the optic nerve (CN II). From the visual cortex there are anterior projections to the motor cortex, then to the facial nucleus, and then to the facial nerve (CN VII) (Mitchell and Oliver, 2021). The palpebral reflex is elicited by touching the skin of the lateral and medial canthus of the eye separately and observing an appropriate response after each touch. Part of this reflex occurs via the ophthalmic and maxillary branches of the V. cranial nerve (trigeminal nerve) for medial and lateral canthus stimulation, respectively. The efferent component of the reflex occurs via the VII. cranial nerve (facial nerve) (Gelatt and Plummer, 2022).

The pupillary light reflex provides optimal visual perception by accurately adjusting the pupil diameter in response to changing ambient illumination (Sun and May, 2014). When light is shone into the eye, pupil constriction occurs in both eyes, even if only one eye is exposed to light. The response in the illuminated eye is a direct response, while the response

in the other eye is indirect or voluntary (Sun and May, 2014). Axons in the optic system, which are not involved in vision, project to the pretectal nuclei at the midbrain level via the lateral ganglion nucleus instead of synapsing. Most axons of the pretectal nuclei cross to synapse on contralateral general visceral efferent (parasympathetic division) neurons of the oculomotor nerve (cranial nerve III) nuclei, which provide parasympathetic innervation to the pupil (Lorenz et al., 2010).

The corneal reflex is elicited by blinking when the corneal surface is touched with a non-damaging object. The afferent arm of this reflex is mediated by cranial nerve V (trigeminal), while the efferent arm is mediated by cranial nerve VII (Gelat and Plummer, 2022).

For a successful clinical outcome and a satisfied patient, early and accurate diagnosis of ocular disorders is essential. This is based on a comprehensive, regular, and thorough ophthalmic examination. Examining a patient with ocular disease includes obtaining a detailed medical history and conducting a complete examination of the eye and its surrounding structures. Specific diagnostic tests may be used in some cases, guided by the patient's history and examination findings (Aroch et al., 2008).

A step-by-step approach should be adopted to examine all parts of the eye systematically. This reduces the likelihood of overlooking abnormalities and provides a systematic evaluation. However, the consistency of the protocol is essential, and not every diagnostic test is necessary for every patient. The selection of appropriate tests should be based on the patient's history and examination findings (Mitchell, 2011).

Systematic evaluation of neuro-ophthalmic responses and reflexes is an essential part of ophthalmic examination (Mitchell and Oliver, 2021). In this regard, a veterinarian can easily evaluate eight of the twelve cranial nerves in any routine eye examination (Martin et al., 2018).

This study investigated the frequency of neuro-ophthalmic diseases in cats and dogs brought to the Surgical Clinic of Burdur Mehmet Akif Ersoy University Faculty of Veterinary Medicine Animal Hospital between January and June 2023.

MATERIALS and METHODS

The material for this study consisted of a total of 110 patients (90 dogs and 20 cats) brought to the Surgical Clinic of Burdur Mehmet Akif Ersoy University Faculty of Veterinary Medicine Animal Hospital between January and June 2023.

In addition to routine eye examinations, the cats and dogs included in the study underwent neuro-ophthalmological evaluation. During the general eye examination, an examination was performed using a direct ophthalmoscope in a dark environment. Data were recorded at different diopters. After the direct ophthalmoscope examination, intraocular pressure (IOP) was measured, and the IOP values of the patients were recorded. The ICare® TONOVET tonometer device (TV01; Icare Finland Oy, Helsinki, Finland) was used for IOP measurement. Following IOP measurement, Jones and Fluorescein Dye tests were performed, and the results were recorded.

In the neuro-ophthalmological examination conducted on the patients of the study, factors such as pupillary light reflex, palpebral reflex, menace reflex, corneal reflex and dazzle reflex were evaluated. Strabismus and nystagmus were also evaluated in terms of clinical findings. In the pupillary light reflex examination, a bright light source is brought close to the eye and the ipsilateral pupil constricts (direct) and the contralateral pupil is examined for constriction (indirect). With the menace reflex, the closure of the eyelids was examined by making a sudden movement with the hand to both eyes without creating airflow or noise. With the palpebral reflex, it was examined whether the patient could blink normally. For this, the skin on the medial and lateral canthus of the animal's eye was lightly touched and eyelid closure was examined. In the corneal reflex, the cornea was touched with an object that did not damage the corneal surface, and the retraction of the cornea and the closure of the eyelids were examined. In the dazzle reflex examination, the occurrence of glare or squinting in the animal's eye by directing a strong light source to the eye was considered positive.

The data obtained from these examinations were recorded with examination forms and photographs for each animal species and breed.

RESULTS

This study was conducted by examining 20 cats and 90 dogs brought to the Surgical Clinic of Burdur Mehmet Akif Ersoy University Faculty of Veterinary Medicine Animal Hospital with various diseases between January and June 2023 (Figure 1).

Figure 1. Graphical representation of the percentages of cats and dogs examined.

Of the examined dogs, 13.48% were diagnosed with eyelid pathology (8 entropion, 1 eyelid coloboma, 2 lagophthalmos, 1 neoplasm), 25.84% had conjunctival pathology (14 conjunctivitis, 7 epiphora, 2 hyperemia), 4.49% had third eyelid pathology (2 laceration, 1 protrusion, 1 eversion), 12.36% had cornea and sclera pathology (1 corneal edema, 2 corneal pigmentation, 1 corneal cicatrix, 2 corneal degeneration, 2 episcleritis, 3 corneal vascularization), 8.99% had uvea pathology (2 hyphema, 6 uveitis), and 14.61% had retina pathology (2 retinal detachment, 11 retinitis). The examination of one dog with microphthalmia could not be performed.

Of the examined cats, 5% were diagnosed with eyelid pathology (1 entropion), 15% had conjunctival pathology (1 epiphora, 2 conjunctivitis), 10% had third eyelid pathology (2 protrusion), 20% had cornea and sclera pathology (3 corneal edema, 1 corneal vascularization), 15% had uvea pathology (3 uveitis), and 20% had retina pathology (4 retinitis). (Figure 2).

Figure 2. Percentage graphical representation of eye examinations in cats and dogs.

In the neuro-ophthalmological examination performed in addition to routine eye examination, abnormalities were observed in 22.22% of the dogs. Of these abnormalities, it was noted that 66.67% had no pupillary light reflex, 5.56% had no palpebral reflex, 38.89% had no menace reflex, 27.78% had

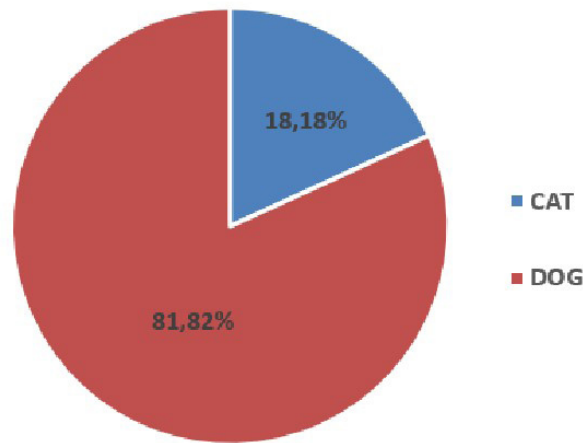


Figure 1. Graphical representation of the number of cats and dogs as a percentage

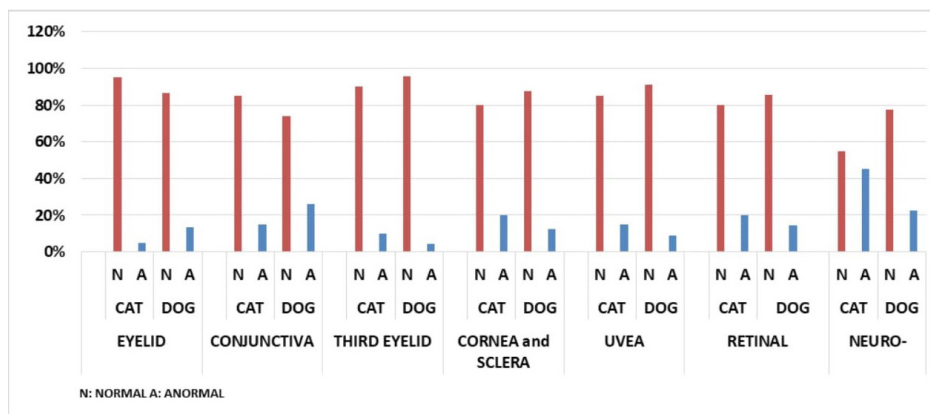


Figure 2. Graphical representation of the percentage of eye examinations performed in cats and dogs

no corneal reflex, and 72.2% had no dazzle reflex. Additionally, 5.56% of the dogs exhibited nystagmus, and 11.11% had strabismus.

In the neuro-ophthalmological examination of cats, abnormalities were observed in 45% of the cases. Among these abnormalities, 81.82% had no pupillary light reflex, 27.27% had

no palpebral reflex, 54.55% had no menace reflex, 54.55% had no corneal reflex, and 81.82% had no dazzle reflex. Additionally, 9.09% of the cats exhibited nystagmus, and 9.09% had strabismus (Figure 3).

Figure 3. Comparison of normal and abnormal values in neuro-ophthalmological examinations of cats and dogs.

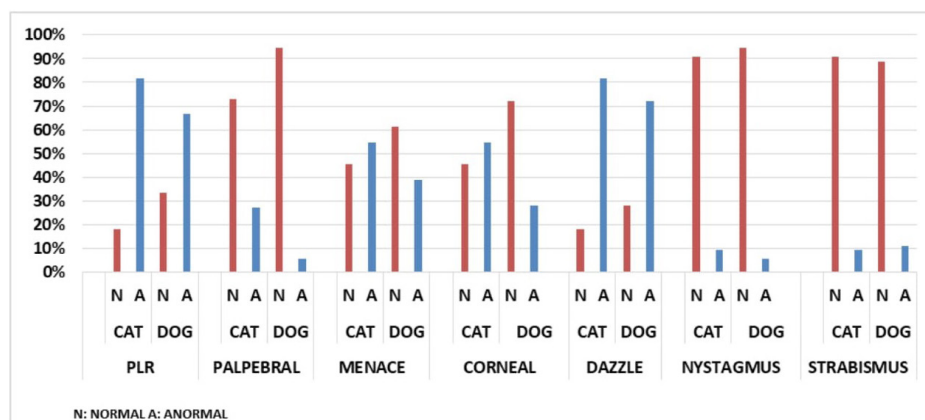


Figure 3. Comparison of normal and abnormal values of neuro-ophthalmological examinations in cats and dogs

In this study, the average IOP in cats was measured as 19.7 mmHg in the right eye and 18.95 mmHg in the left eye. In dogs, the IOP was measured as 23.07 mmHg in the right eye and 22.95 mmHg in the left eye. The IOP values obtained from the patients in this study were within the normal range.

DISCUSSION

Neuro-ophthalmologic problems are encountered more frequently, especially in cases with neurologic diseases. These cases can often go unnoticed during the examination (Brisimi et al., 2017).

Strabismus is an irregular position of the eye that can be positional (occurring when the head is turned upside down) or spontaneous (constantly present) and can be divergent or convergent (Sanders, 2016). Unilateral lesions can lead to dysfunction in the extraocular muscles, affecting the oculomotor (causing divergence), abducens (causing convergence), and trochlear nerves or nuclei. In animals with cleft pupils, trochlear dysfunction becomes evident. Additionally, such lesions can impact the vestibular system, causing positional or vestibular-related strabismus (Polizopoulou and Zavros, 2001; Ofri, 2008b). It's important to differentiate this type of strabismus from conditions such as orbital and muscle diseases, which restrict normal eye movement (Ofri, 2008b).

Positional strabismus, along with nystagmus, has been identified as the most prevalent vestibular symptom of distemper (Amude et al., 2007; Amude et al., 2010). Brisimi et al. (2017) detected nystagmus in 5 dogs with distemper in their study. Strabismus resulting from hydrocephalus typically arises from malformations of the cranial bone around the orbit and mechanical compression, rather than vestibular dysfunction (Polizopoulou and Zavros, 2001; Sanders, 2016). This condition is commonly known as the 'setting sun sign' (Sanders, 2016). Among the dogs diagnosed with idiopathic peripheral vestibular disease, four exhibited ipsilateral strabismus, with three cases being positional and one presenting as spontaneous divergent. In this scenario, spontaneous or vestibular strabismus may arise. It is important to differentiate the latter from a fixed or static strabismus caused by denervation of cranial nerves III, IV, or VI, where the eye remains deviated regardless of head position (Kent et al., 2010). Unilateral strabismus is the most common in this case (Polizopoulou and Zavros, 2001). Positional strabismus, accompanied by nystagmus, observed in cases of ischemic encephalopathy, might be associated with the engagement of the vestibular thalamic area and its afferent connections to the brainstem vestibular nuclei (Garosi et al., 2006; Hillock et al., 2006). Likewise, the secondary impacts of brain tumors, such as edema and hemorrhage compressing the midbrain/brainstem, can lead to cranial nerve deficits and, consequently, result in strabismus (Sanders, 2016). Divergent strabismus is frequently linked with syringomyelia and Chiari-like malformations, though it remains uncertain whether this association stems from oculomotor nerve/muscle paralysis or globe misalignment (Rusbridge, 2013). Intriguingly, a dog diagnosed with presumed post-vaccinal polyradiculoneuritis exhibited a recognized syndrome of bilateral divergent strabismus (Schrauwen and Van Ham, 1995; Gehringa and Eggarsb, 2001; Quiroz Rothe et al., 2005). Its pathogenesis may be linked to

muscle atrophy, similar to what is observed in Guillain-Barré syndrome in humans. In the latter case, symmetrical paralysis of cranial nerve V has been documented to result in complete ophthalmoparesis or limitations in eye movements attributed to cranial nerve V deficits (Gurwood and Drake, 2006). Dogs experiencing neural involvement of the trigeminal nerves in polyradiculoganglioneuritis may present clinical signs such as unilateral atrophy, bilateral paralysis of masticatory muscles, and Horner syndrome (Panciera et al., 2002). In this study, strabismus was found in 11.11% of dogs and 9.09% of cats (1 of these patients had cheri-like malformation, while the other patients had complaints of otitis, fip and trauma).

Nystagmus can manifest as either spontaneous/resting or positional. In cases of vestibular disease, it may present as horizontal, vertical, or rotatory, with the character of nystagmus being either jerky or pendular, determined by the speed of the eye oscillations (Muñana, 2004). "Abnormal nystagmus needs to be differentiated from physiological nystagmus, which arises due to the vestibulo-ocular reflex during head movements (Ofri, 2008b). Lesions impacting the vestibular system, affecting the brainstem nuclei (such as the medial longitudinal fasciculus) or neurons of cranial nerves (CNs III, IV, VI) that innervate extraocular muscles, resulting in the absence of normal vestibular nystagmus (Ofri, 2008b; de Lahunta, 2009). In idiopathic peripheral vestibular syndrome (IPVS), the most common form of nystagmus is horizontal, but sometimes rotatory nystagmus may be observed (Polizopoulou et al., 2006; Ofri, 2008b). The existence of nystagmus, particularly positional, is linked to thalamic/midbrain infarction, indicating the involvement of the vestibular thalamic area and its afferent connections with the brainstem vestibular nuclei (Garosi et al., 2006). In instances of meningiomas, impairment in the diencephalic region, specifically the cerebellum-pontine angle, can result in vestibular symptoms, given that the thalamus functions as a relay station for afferent vestibular inputs to the cortex (Motta et al., 2012). Moreover, meningiomas situated at the cerebellum-pontine angle are frequently linked to clinical symptoms of paradoxical vestibular syndrome (Adamo et al., 2004). In cats, one with vestibular disease of unknown origin and another with head trauma displayed horizontal nystagmus, whereas a cat with FIP encephalitis manifested positional nystagmus. Granulomas linked to FIP can occasionally impede cerebrospinal fluid drainage, leading to secondary hydrocephalus (Sherding, 2006). In this study, nystagmus was observed in 5.56% of dogs and 9.09% of cats.

The normal intraocular pressure in a healthy animal is 15-25 mmHg (Şaroğlu, 2013). In this study, the average intraocular pressure in cats was measured as 19.7 mmHg in the right eye and 18.95 mmHg in the left eye. In dogs, the intraocular pressure was measured as 23.07 mmHg in the right eye and 22.95 mmHg in the left eye.

In a previous study, 35.05% of cats examined ophthalmologically and 35.92% of dogs examined had diagnosed eye pathologies (Şengöz Şirin et al., 2023). In this study, eye pathologies were diagnosed as follows: 13.48% of examined dogs had eyelid pathology (8 entropion, 1 eyelid coloboma, 2 lagophthalmos, 1 neoplasm), 25.84% had conjunctival pathology (14

conjunctivitis, 7 epiphora, 2 hyperemia), 4.49% had third eyelid pathology (2 laceration, 1 protrusion, 1 eversion), 12.36% had cornea and sclera pathology (1 corneal edema, 2 corneal pigmentation, 1 corneal scar, 2 corneal degeneration, 2 episcleritis, 3 corneal vascularization), 8.99% had uveal pathology (2 hyphema, 6 uveitis), and 14.61% had retinal pathology (2 retinal detachment, 11 retinitis). One dog with microphthalmia was unable to undergo an examination.

In the case of examined cats, 5% had eyelid pathology (1 entropion), 15% had conjunctival pathology (1 epiphora, 2 conjunctivitis), 10% had third eyelid pathology (2 protrusion), 20% had cornea and sclera pathology (3 corneal edema, 1 corneal vascularization), 15% had uveal pathology (3 uveitis), and 20% had retinal pathology (4 retinitis).

CONCLUSION

In conclusion, in this study, a total of 110 cat and dog cases presented to our clinic were subjected to neuro-ophthalmological examination in addition to routine eye examinations. These cases were retrospectively evaluated and reported. The neuro-ophthalmological examination is not routinely included among the commonly used eye examinations. However, many central nervous system diseases and systemic diseases manifest as ophthalmic dysfunction. During the examination, the likelihood of overlooking many neuro-ophthalmological diseases and experiencing difficulties in diagnosis is high. Therefore, in addition to a routine eye examination, the neuro-ophthalmological examination should also be added.

DECLARATIONS

Ethics Approval

This study does not present any ethical concerns.

Conflict of Interest

The authors declared that there is no conflict of interest.

Consent for Publication

No applicable.

Author contribution

Idea, concept and design: ÖŞŞ, MYŞ, ANE

Data collection and analysis: ÖŞŞ, MYŞ, ANE

Drafting of the manuscript: ÖŞŞ, MYŞ, ANE

Critical review: ÖŞŞ

Data Availability

The author has provided the required data availability statement, and if applicable, included functional and accurate linksto said data therein.

Acknowledgements

No applicable.

REFERENCES

Adamo, P.F., Forrest, L., Dubielzig, R. (2004). Canine and feline meningiomas: diagnosis, treatment, and prognosis. *Compendium: Continuing Education For Veterinarians*, 26, 951.

Amude, A.M., Alfieri, A.A., Alfieri, A.F. (2007). Clinico-pathological findings in dogs with distemper encephalomyelitis presented without characteristic signs of the disease. *Research in Veterinary Science*, 82, 416–422.

Amude, A.M., Alfieri, A.F., Alfieri, A.A. (2010). Clinical courses and neurological signs of canine distemper virus infection in dogs. *Current research, technology and education topics in applied microbiology and microbial biotechnology*, Sao Paulo, 723-7328.

Aroch, I., Ofri, R., Sutton, G.A. (2008). Ocular manifestations of systemic diseases. In: Maggs, D.J., Miller, P.E., Ofri, R., *Slatter's fundamentals of veterinary ophthalmology* (pp.390-428). Elsevier.

Brisimi, N. M., Liatis, T. K., Komnenou, A., Charalambidou, G., Soubasis, N., Polizopoulou, Z. S. (2017). Neuro-ophthalmological abnormalities in neurological diseases of dogs and cats: a retrospective study of 114 cases (2010-2015). *Journal of the Hellenic Veterinary Medical Society*, 68(3), 433-444. doi: 10.12681/jhvms.15538.

de Lahunta, G. (2009). Chapter 7: Lower Motor Neuron: General Visceral Efferent System. In: *Veterinary neuroanatomy and clinical neurology*, (3rd ed., pp.168-191). ELSEVIER Saunders, St. Louis, Missouri.

Garosi, L., McConnell, J.F., Platt, S.R., Barone, G., Baron, J.C., de Lahunta, A., Schatzberg, S.J. (2006). Clinical and Topographic Magnetic Resonance Characteristics of Suspected Brain Infarction in 40 Dogs, *Journal of Veterinary Internal Medicine*, 20, 11–321.

Gehringa, R., Eggarsb, B. (2001), Suspected post-vaccinal acute polyradiculoneuritis in a puppy, *Journal of the South African Veterinary Association*, 72(2), 96.

Gelatt, K.N., Plummer, C.E. (2022). Chapter 18: Neuro-Ophthalmology. *Essentials of Veterinary Ophthalmology* (4th ed., pp.793-783), USA: Wiley Blackwell.

Gurwood, A.S., Drake, J. (2006) Guillain-Barré syndrome, *Optometry*, 77, 540-546.

Hillock, S.M., Dewey, C.W., Stefanacci, J.D., Fondacaro, J.V. (2006). Vascular encephalopathies in dogs: incidence, risk factors, pathophysiology, and clinical signs, *Compendium on continuing education for the practicing veterinarian*. North American Edition, 28(3), 196-207.

Holmberg, B.J. (2020). Neuroophthalmology. In: Bruyette, D.S. (Ed.). *Clinical Small Animal Internal Medicine* (1st ed., pp. 823-829). John Wiley & Sons.

Kent, M., Platt, S.R., Schatzberg, S.J. (2010). The neurology of balance: Function and dysfunction of the vestibular system in dogs and cats, *The Veterinary Journal*, 185, 278-258.

Lorenz, M.D., Coates, J., Kent, M. (2010). Blindness, Anisocoria and Abnormal Eye Movements. *Handbook of Veterinary Neurology* (5th ed., pp.330-345). USA: Elsevier Health Sciences.

- Martin, C.L., Pickett, J.P., Spiess, B.M. (2018). Neuro-Ophthalmic Disorders. In: Ophthalmic Disease in Veterinary Medicine (pp. 91- 119). CRC Press.
- Mitchell, N., Oliver, J. (2021). The eyelids, nictitans and lacrimal system. In: Feline Ophthalmology The manual (pp. 61-88). Spain: Grupo Asis Biomedica SL.
- Mitchell, N. (2011). Approach to ocular examination in small animals. In Practice, 33(4), 146-154.
- Mitchell, N., Oliver, J. (2021). Chapter 12: Neuro-ophthalmology. Feline Ophthalmology The manual (p.194-208). Spain: Grupo Asis Biomedica SL.
- Motta, L., Mandara, M.T., Skerritt, G.C. (2012) Canine and feline intracranial meningiomas: An update review, The Veterinary Journal, 192, 153-165.
- Muñana, K.R. (2004) Chapter 10: Head tilt and nystagmus. In: Platt, S., Olby, N. (Ed.). BSAVA Manual of Canine and Feline Neurology (3rd ed., pp.155-171). BSAVA.
- Ofri, R. (2008). Chapter 16: Neuro-ophthalmology. In: Maggs, D.J., Miller, P.E., Ofri, R. (Ed.). Slatter's Fundamentals of Veterinary Ophthalmology (4th ed., pp.318-351). ELSEVIER Saunders.
- Pancier, R.J., Ritchey, J.W., Baker, J.E., Digregoriot, M. (2002). Trigeminal and Polyradiculoneuritis in a Dog Presenting with Masticatory Muscle Atrophy and Horner's Syndrome, Vet Pathol, 39, 146-149.
- Penderis, J. (2013). Disorders of eyes and vision. In: Platt SR, Olby NJ. (Eds.), BSAVA Manual of Canine and Feline Neurology (pp. 167-194), BSAVA Library.
- Platt, S.R., Olby, N.J. (2014). BSAVA manual of canine and feline neurology. British Small Animal Veterinary Association (4th ed.), BSAVA Library.
- Polizopoulou, Z., Zavros, N. (2001). Neuro-ophthalmological examination in dog and cat. Journal of the Hellenic Veterinary Medical Society, 52(2), 347-354.
- Polizopoulou, Z.S., Danourdis, A.M., Koutinas, A.F. (2006) The vestibular syndrome in dogs and cats. Journal of the Hellenic Veterinary Medical Society, 57(1), 63-68.
- Quiroz Rothe, E., Ginel, P.J., Pérez, J., Lucena, R., Rivero, J.L.L. (2005). European Journal of General Practice, 15(2), 155-160.
- Rusbridge, C. (2013). Chiari-like malformation and syringomyelia. European Journal of General Practice, 23(3), 70-88.
- Sanders, S.G. (2016). Chapter 11: Disorders of Hearing and Balance. In: Dewey, C.W., da Costa, R.C. (Eds.), Practical Guide to Canine and Feline Neurology (3rd ed., pp.277-297). Wiley Blackwell.
- Şaroğlu, M. (2013). Sistemik Göz Muayenesi. Veteriner Oftalmoloji- Kedi ve Köpek Göz Hastalıkları. İstanbul: Nobel Tıp Kitapevleri.
- Schrauwen, E., Van Ham, L. (1995). Postvaccinal acute polyradiculoneuritis in a young dog. Progress in Veterinary Neurology, 6, 68-70.
- Şengöz Şirin, Ö., Çetin, M. N., Neyse, B. (2023). Evaluation of eye diseases in cats and dogs: a retrospective study: 200 cases. Veterinary Journal of Mehmet Akif Ersoy University, 8(1), 44-49.
- Sherding, R.G. (2006). Feline Infectious Peritonitis (Feline Coronavirus). In: Birchard, S.J., Sherding, R.G. (Eds.). Saunders Manual of Small Animal Practice (3rd ed., pp. 132-143). Elsevier Saunders.
- Spiess, B.M. (2019). Chapter 4: Neuro-Ophthalmic Disorders. Ophthalmic Disease in Veterinary Medicine (2nd ed., pp.91-119), USA: CRC Press.
- Sun, W., May, P.J. (2014). Central pupillary light reflex circuits in the cat: I. The olivary pretectal nucleus. Journal of Comparative Neurology, 522(18), 3960-3977.