



Radiographic Imaging and Osteometric Analysis Os Penis in Red Fox (*Vulpes vulpes*)

Yeşim ASLAN KANMAZ^{1*} Saime Betül BAYGELDİ¹

Department of Anatomy, Faculty of Veterinary Medicine, University of Fırat, Elazığ, Türkiye

Received: 30.07.2024

Accepted: 12.12.2024

Published: 31.12.2024

How to cite: Aslan Kanmaz, Y. & Baygeldi, S.B. (2024). Radiographic imaging and osteometric analysis os penis in red fox (*Vulpes vulpes*). *J. Anatolian Env. and Anim. Sciences*, 9(4), 687-690. <https://doi.org/10.35229/jaes.1524650>

Atıf yapmak için: Aslan Kanmaz, Y. & Baygeldi, S.B. (2024). Kızıl tilki (*Vulpes vulpes*) os penisinin radyografik görüntülenmesi ve osteometrik analizi. *Anadolu Çev. ve Hay. Dergisi*, 9(4), 687-690. <https://doi.org/10.35229/jaes.1524650>

*ID: <https://orcid.org/0000-0002-2401-1500>
ID: <https://orcid.org/0000-0002-4403-8663>

*Corresponding author's:
Yeşim ASLAN KANMAZ
Department of Anatomy, Faculty of Veterinary
Medicine, University of Fırat, Elazığ, Türkiye
✉: yesim.aslan@firat.edu.tr

Abstract: The aim of this study was to determine the macroscopic features of the os penis of the Red Fox (*Vulpes vulpes*), as well as radiographic images and morphometric measurements using a digital electronic caliper. In this study, 4 adult male red fox os penises, which were previously brought dead from nature by students and whose skeletons were exhibited in our anatomy museum, were used. Macroscopic and morphometric measurements were taken and anatomical structures were analysed by radiographic imaging. Os penis is thicker at the proximal end and tapers towards the distal end, terminating in a cartilaginous tip. Sulcus urethralis is found on the ventral side. Os penis of the Red Fox measured as, length of the os penis 56.70mm, Distal diameter 2.96mm, Proximal diameter 3.85mm, length of the sulcus urethralis 35.13mm, width of sulcus urethralis 2.95mm, length of the fibrous cartilaginous tissue 5.70, width of the fibrous cartilaginous tissue 1.77mm. As a result, it has been observed that the os penis of the red fox, which is a part of wildlife, is similar to the other members of the team, the dogs, and radiographic images have been combined with new techniques and a literary contribution has been made. Wild animal anatomy has been supported by more detailed examination of these species. It is thought that the data obtained in the study can be used in future morphometric, zoo-archaeological, and taxonomic studies.

Keywords: Osteometric analysis, os penis, radiographic imaging, red fox

Kızıl Tilki (*Vulpes vulpes*) Os Penisinin Radyografik Görüntülenmesi ve Osteometrik Analizi

Öz: Bu çalışmanın amacı, Kızıl Tilki (*Vulpes vulpes*) os penisinin makroskobik özelliklerinin yanı sıra dijital elektronik kumpas kullanılarak radyografik görüntülerini ve morfometrik ölçümlerini belirlemektir. Bu çalışmada, daha önce öğrenciler tarafından doğadan ölü olarak getirilen ve iskeletleri anatomi müzümüzde sergilenen 4 yetişkin erkek kızıl tilki os penisini kullanıldı. Morfometrik ölçümler alındı ve anatomik yapılar radyografik görüntüleme ile analiz edildi. Os penisin proksimal uca daha kalın olduğu ve distal uca doğru incelerek kıkırdaklı bir uca sonlandığı görüldü. Kızıl tilki'nin os penisinin ventral tarafında sulcus urethralis mevcuttu. Os penis uzunluğu 56,70 mm, distal çapı 2,96 mm, proksimal çapı 3,85 mm, sulcus urethralis uzunluğu 35,13 mm, sulcus urethralis genişliği 2,95 mm, lifli kıkırdak dokusunun uzunluğu 5,70 mm, lifli kıkırdak dokusunun genişliği 1,77 mm olarak ölçüldü. Sonuç olarak, yaban hayatının bir parçası olan kızıl tilkinin os penisinin, canidae ailesinin evcil üyeleri olan köpeklere benzediği gözlemlenmiş ve radyografik görüntüler yeni tekniklerle birleştirilerek literatürel bir katkı sağlanmıştır. Çalışmada elde edilen verilerin gelecekteki morfometrik, zoo-ärkeolojik ve taksonomik çalışmalarda kullanılabileceği düşünülmektedir.

*Sorumlu yazar:
Yeşim ASLAN KANMAZ
Fırat Üniversitesi Veteriner Fakültesi
Anatomi Anabilim Dalı, Elazığ, Türkiye
✉: yesim.aslan@firat.edu.tr

Anahtar kelimeler: Osteometrik analiz, os penis, radyografik görüntüleme, red fox.

INTRODUCTION

The Red Fox (*Vulpes vulpes*) was the most geographically spread species of the Carnivores and represents as one of the most abundant carnivore in Egypt.

It was taxonomy under Kingdom: Animalia, Phylum: Chordata, Class: Mammalia, Order: Carnivora, Family: Canidae, Tribe: Vulpini (Porobic, 2017). The extremely adaptable and most numerous representative of the *Vulpes* genus is the red fox (*Vulpes vulpes*). It is present in the

steppe biomes and mixed forests of Eurasia within the temperate climate zone (Lloyd, 1980; Porobic, 2017). The red fox has adapted to life in different types of habitats and climates and can be seen in urban and suburban areas, which has led to partial changes in behavior and in its manner and type of nutrition (Gloor et al., 2001; Porobic, 2017). *Vulpes vulpes* belongs to the order of Carnivora; however, unlike dogs and cats, it is actually an undomesticated canid, between a large cat and a small dog in size (Gloor et al., 2001). However, as the largest species of the genus *Vulpes*, its body size ranges between 3 and 14 kg (Nowak, 1999). The os penis is a bony structure located in the corpus cavernosum penis. It is located in the distal part of the penis. It is shaped like a corrugated probe and its opening faces ventrally and the urethra runs in this opening. This groove is called the sulcus urethralis. In the German Shepherd and Turkish Shepherd Dogs, the sulcus urethralis is more closed and flat at the proximal end, while it widens and becomes shallower towards the distal end and disappears completely in the distal 1/3. The dorsoventral diameter is thicker than the laterolateral diameter. The distal part of the bone ends in a hyaline, fibrous, or fibrocartilaginous structure (Getty, 1975; Evans and De Lahunta, 2012).

The radiographic diagnosis method still maintains its gold standard value in the diagnosis of diseases in veterinary medicine. It is the most preferred diagnostic method due to its affordable cost and easy applicability in the diagnosis of diseases. It is understood by studies that radiography is frequently used especially in bone-related problems (Şen & Bumin, 2015; Okkesim et al., 2017; Arslan & Altındağ, 2023;; Koç, 2023). However, a good-quality radiograph is needed for a good evaluation. For this purpose, the desired region should be taken in the appropriate position, at the appropriate dose and the radiographic anatomy of the region should be well-known in order to evaluate the radiograph.

This study was carried out to determine the anatomical features of the os penis in the red fox.. It is expected to contribute to the literature by knowing the radiographic anatomy for the radiographic examination method, which is an important method especially in disease diagnoses today, and by detailing the anatomical structures in wild animal species.

MATERIAL AND METHOD

In this study 4 adult male red fox os penises, which were previously brought dead from nature by students (with the permission of the General Directorate of Nature Conservation and National Parks of the Ministry of Agriculture and Forestry with the number E-21264211-288.04-14713474) and whose skeletons were exhibited in our anatomy museum, were used. The dead animals were

firstly subjected to maceration procedures by removing the skin and muscles, which are routine dissection procedures, and then made ready for craniometric measurements. Digital callipers were used for craniometric measurements (Figure 1). The surfaces of the penis bone were examined for macroanatomical observations. *Nomina Anatomica Veterinaria* (2017) was used in the spelling of anatomic terminology.

For morphometric measurement points, the greatest length of the os penis and the diameter of the proximal/distal part, the length and width of the fibrocartilaginous part, the length and width of the sulcus urethralis were calculated with digital callipers.

A radiography device (Varian Medical Systeme X-RAY PRODUCTS, RAD-14) in Firat University Animal Hospital was used for radiographic images. Radiographic images of the penis were taken. The images were transferred to the computer and the necessary anatomical parts were marked on the image.

RESULTS

The os penis of the Red Fox is thicker at the proximal end and tapers towards the distal end, terminating in a cartilaginous tip. There are three margins, one dorsal and two ventrolateral to the sulcus urethralis. The dorsal edge forms a crista on the median of the bone, extending from proximal to distal. The crista becomes shallow at the distal 1/3 of the bone and disappears completely at the cartilaginous end. Sulcus urethralis is found on the ventral side. Sulcus urethralis is wider in the proximal side but it shows a shallower course towards the distal side. The distal end shows a concavity towards the ventral side. This part, which is composed of cartilage, is developed and spoon-like. In the distal part of the bone, a fibrous cartilaginous tissue with a length of 5.70mm mm and a thickness of 1.77 mm was detected.

The os penis of the Red Fox measured as, length of the os penis 56.70mm, Distal diameter 2.96mm, Proximal diameter 3.85mm, length of the sulcus urethralis 35.13mm, width of sulcus urethralis 2.95mm, length of the fibrous cartilaginous tissue 5.70, width of the fibrous cartilaginous tissue 1.77mm (Table 1).

Table 1: Findings measured on the os penis by classical morphometry (mm).

Parameters	Morphometric easurement (Average of 4 red foxes)
Length of the os penis (LOP)	56.70mm
Distal diameter os penis (DDOP)	2.96mm
Proximal diameter os penis (PDOP)	3.85mm
length of the sulcus urethralis (LSU)	35.13mm
width of sulcus urethralis (WSU)	2.95mm
Length of the fibrous cartilaginous tissue (LFCT)	5.70mm
Width of the fibrous cartilaginous tissue (WFCT)	1.77mm




Figure 1. View of the os penis measured with a digital caliper. Blue Arrow: fibrous cartilaginous tissue, Length of the os penis (LOP), Length of the sulcus urethralis (LSU), Width of sulcus urethralis (WSU), Length of the fibrous cartilaginous tissue (LFCT), Width of the fibrous cartilaginous tissue (WFCT).

Os penis of the red fox was visualized by radiographic imaging. Dorsoventral and laterolateral position images were taken and transferred to the computer. Morphometric measurement points were also marked on the radiographic images (Figure 1, Figure 2 and Figure 3).

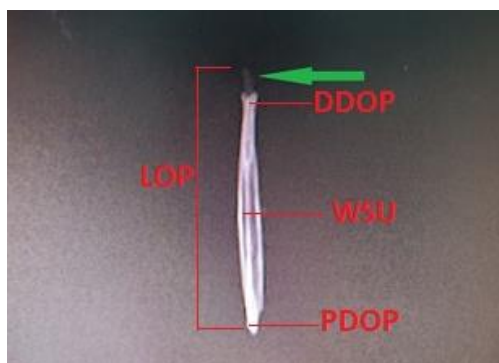


Figure 2. Radiographic Imaging of os penis in the red fox. Dorsoventral view (Green arrow: fibrous cartilaginous tissue, Length of the os penis (LOP), Distal diameter os penis (DDOP), Proximal diameter os penis (PDOP), width of sulcus urethralis (WSU)).

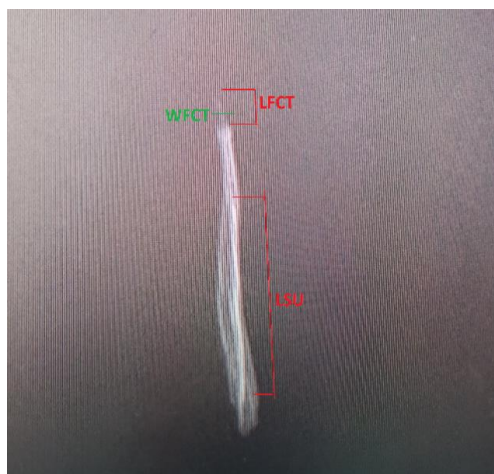


Figure 3. Radiographic Imaging of os penis in the red fox. Laterolateral view (Length of sulcus urethralis (LSU), Length of the fibrous cartilaginous tissue (LFCT), Width of the fibrous cartilaginous tissue (WFCT)).

DISCUSSION AND CONCLUSION

The fox os penis is thicker proximally and distally it has a structure resembling a corrugated probe with a sulcus urethralis on the ventral side, which gradually tapers towards the end (Gultiken et al., 2004). With this shape, it shows exactly the characteristics reported for the dog in classical books (Getty, 1975; Nickel et al., 1986; Evans, 2012). Although Yılmaz et al. (1993) reported that the sulcus urethralis terminated at distal of the os penis and the crista on the dorsal margin terminated at distal, this ratio was found to be for both formations in the fox. The dorsoventral diameter was found to be greater than the laterolateral diameter throughout the length of the bone as reported by Evans (2012).

In the study of Canady (2013), it was stated that a cartilaginous structure was not observed on the distal tip of os penis belonging to the fox. The absence of cartilaginous structure might be attributed to the fact that the materials were brought from a museum. In our study, cartilaginous structure was found to be present. According to the study of Gultiken et al. (2004), it was determined that the proximal part of the os penis of the fox is bone and the distal part is cartilage. Our study was similar to this study and cartilaginous structure was found in the distal part.

Canady (2013) measured with the digital calliper as the length of the os penis 47.01-63.41 mm, the dorsoventral thickness 2.64-4.60 mm, the length of the sulcus urethralis 31.02-46.41 mm, the width of sulcus urethralis 1.70-3.59 mm, in red fox. In the study by Halıgür & Özkadif (2019) os penis was measured from 3D reconstruction images, length of it 65.32-67.53 mm, width of it 5.71-6.25 mm, and dorsoventral thickness 3.48-3.74 mm. The sulcus urethralis was measured from 3D reconstruction images, length of 2.97-3.37 mm, width of 43.86-45.59 mm. Our study is similar to these studies measured as the Length of the os penis is 56.70mm, Distal diameter of 2.96mm, Proximal diameter of 3.85mm, length of the sulcus urethralis 35.13mm, width of the sulcus urethralis 2.95mm, Length of the fibrous cartilaginous tissue 5.70mm.

Schwery et al. (2011) and Canady (2013) showed that a lower variability in the length of the penis bone and a greater variability in its thickness can play an important role in increasing the strength of the bone and preventing its possible fracture during copulation. Some data on the length of the penis in several species of Canidae were shown by Burt (1960), Lariviere & Ferguson (2002) and Dixson et al. (2004). When we consider the data in our study, it was observed that the results were similar to other studies and were similar to the canidae species.

As a result, it has been observed that the os penis of the red fox, which is a part of wildlife, is similar to the

other members of the team, the dogs, and radiographic images have been combined with new techniques and a literary contribution has been made. Wild animal anatomy has been supported by more detailed examination of these species. It is thought that the data obtained in the study can be used in future morphometric, zoo-archaeological, and taxonomic studies.

Declaration of Conflicting Interests

The author(s) declared no potential conflicts of interest with respect to the research, authorship, and/or publication of this article.

Data Availability statement: The data that support the findings of this study are available from the corresponding author upon reasonable request

REFERENCES

- Arslan, Ö.F. & Altındağ, A. (2023).** *Temporomandibular eklem anatomisi bozuklukları ve görüntüleme yöntemleri, 1st (ed.)* 117-144p, Sağlık & Bilim, Odontoloji-İv. Efe Akademi Yayınları., İstanbul, Türkiye
- Burt, W.H. (1960).** Bacula of north american mammals. university of michigan miscellaneous publications of the museum of zoology, *113*, 1-75.
- Canady, A. (2013).** Variability of the baculum in the red fox (*Vulpes vulpes*) from Slovakia. *Zoology and Ecology*, *23*, 165-170.
- Dixon, A.F. & Anderson, M. (2004).** Sexual behavior, reproductive physiology and sperm competition in male mammals. *Physiology and Behavior*, *83*, 361-371.
- Evans, H.E. & De Lahunta, A. (2012).** In *Miller's Anatomy of the Dog*, M. E. Miller (Ed.), Saunders, Philadelphia, PA.
- Getty, R. (1975).** *Sisson and Grossman's the Anatomy of the Domestic Animals'*. Fifth Ed. Evans, H. E., & Christensen, G. C. (Eds.), 457p.
- Gloor, S., Bontadina, F., Heggin, D., Deplazes, P. & Breitenmoser, U. (2001).** The rise of urban fox populations in Switzerland. *Mammalian Biology*, *66*, 155-164.
- Gultiken, M.E., Yıldız, D. & Bolat, D. (2004).** The anatomy of os penis in red fox (*Vulpes vulpes*). *Ankara Üniversitesi Veteriner Fakültesi Dergisi*, *51*, 71-73.
- Halgür, A. & Özkadif, S. (2019).** Male genital organs in the red fox (*Vulpes vulpes*); Macroanatomic and three-dimensional reconstruction aspect. *Mehmet Akif Ersoy University Journal of Health Sciences Institute*, *7*(2), 89-98.
- Koç, Ş. (2023).** *Kliniğimize*. Master's thesis, Aydın Adnan Menderes Üniversitesi, Sağlık Bilimleri Enstitüsü. Aydın, Türkiye, 66s.
- Lariviere S. & Ferguson S. H. (2002).** On the evolution of the mammalian baculum: vaginal friction, prolonged intromission or induced ovulation. *Mammal Review*, *32*, 283-294.
- Lloyd, H.G. (1980).** Habitat requirements of the red fox. In *The red fox: symposium on behaviour and ecology* (pp. 7-25). Dordrecht: Springer Netherlands.
- Nickel, R., Schummer, A., Seiferle, E., Frewein, J., Wilkens, H., Wille, K.H. & Stokoe, W.M. (1986).** The anatomy of the domestic animals. Volume 1. The locomotor system of the domestic mammals.
- Nomina Anatomica Veterinaria. (2017).** International Committee on Veterinary Gross Anatomical Nomenclature: General Assembly of the World Association of Veterinary Anatomists. 6th edition, Gent.
- Nowak, R.M. (1999).** *Walker's Mammals of the World* (Vol. 1). JHU press.
- Okkesim, A., Yılmaz, B. & Yılmaz, S. (2017).** Maksillofasiyal travmalarda ilk müdahale ve radyografik görüntüleme. *ADO Klinik Bilimler Dergisi*, *8*(1), 1553-1562.
- Porobic, J.M. (2017).** *Geometric-morphometric analyses of golden jackal (Canis aureus) and red fox (Vulpes vulpes) skulls from the territory of Serbia: biogeographical aspects of morphological variability*. Doctoral dissertation, University of Belgrade. Belgrade, Serbia, 214p.
- Schwery, O., Köhnemann, B.A., Michler, F.U. & Brinkmann, W. (2011).** Morphometrical characterisation of a raccoon (*Procyon lotor* L.) population from Müritz National Park (Germany) by means of the Os baculum. *Beiträge zur Jagd- und Wildforschung*, *36*, 605-617.
- Şen, Y. & Bumin, A. (2015).** Sığır Ayaklarında radyolojik anatomi. *Türkiye Klinikleri Veterinary Sciences-Surgery-Special Topics*, *1*(1), 8-12.
- Yılmaz, O., Yıldız, H., Bahadır, A., Yılmaz, B. & Serbest, A. (1993).** Türk çoban ve Alman kurt köpeklerinin os penis'i üzerinde karşılaştırmalı bir araştırma. *Uludağ Üniversitesi Veteriner Fakültesi Dergisi*, *12*(2), 62-67.