



Morphometric Investigation of Sexual Dimorphism and Homotypic Variations of Ossicula Auditus in Morkaraman Sheep

Funda AKSUNGER KARAAVCI^{1,a,*}, Ali KOCYİĞİT^{2,b}

¹Department of Anatomy, Faculty of Veterinary Medicine, Bingol University, Bingol, Türkiye.

²Laboratory and Veterinary Health Vocational School, Harran University, Sanliurfa, Türkiye.

^aORCID: 0000-0001-8311-1723

^bORCID: 0000-0002-9354-7480

Received: 10.08.2024

Accepted: 31.10.2024

How to cite this article: Aksunger Karaavci F, Kocyigit A. (2024). Morphometric Investigation of Sexual Dimorphism and Homotypic Variations of Ossicula Auditus in Morkaraman Sheep. Harran Üniversitesi Veteriner Fakültesi Dergisi, 13(2): 118-122.

DOI:10.31196/huvfd.1530720.

***Correspondence:** Funda Aksunger Karaavci
Department of Anatomy, Faculty of Veterinary Medicine, Bingol University, Bingol, Türkiye.
e-mail: fakaraavci@bingol.edu.tr

Available on-line at:

<https://dergipark.org.tr/tr/pub/huvfd>

Abstract: In this study, it was aimed to determine the morphometric characteristics of the bones forming the ossicula auditus of Morkaraman sheep and to reveal the differences between sexes and sides. For this purpose, 24 (12 females/12 males) craniums of Morkaraman sheep were used in the study. After the craniums were macerated, the ossicula auditus in the cavum tympani were dissected out and morphometric data were determined by taking linear measurements. Sexually dimorphic structures and homotypic variations of the obtained morphometric data were statistically calculated. It was observed that the bones forming the ossicula auditus were malleus, incus and stapes, respectively; when the morphometric data obtained were analyzed, it was determined that there were statistically dimorphic differences between sexes in the parameters of malleus length, width of the caput mallei and length of the manubrium mallei ($P<0.001$), Length of the caput mallei ($P<0.01$) in the left malleus ossicle, length of the crus breve ($P<0.001$) in the right incus ossicle, Length of the crus longum and length of the corpus incudis ($P<0.01$), length of the crus breve and width of the corpus incudis ($P<0.001$) in the left incus ossicle. Homotypic variation was detected in the length of the caput mallei ($P<0.01$), length of the malleus and length of the manubrium mallei ($P<0.001$) parameters in malleus in male sheep, and width of the corpus incudis ($P<0.001$) parameter in incus in female sheep. At the same time, no symmetrical difference was found in other parameters ($P>0.05$). In the correlation analysis of the morphometric parameters of the ossicles, weak, moderate and strong correlation was observed in the positive direction, while only weak correlation was observed in the negative direction. As a result, it is thought to contribute to taxonomic and experimental studies by determining the morphometric parameters of the ossicula auditus bones of Morkaraman sheep.

Keywords: Dimorphism, Homotypic variation, Morphometry, Ossicula auditus.

Morkaraman Koyunlarında Ossicula Auditus'un Eşeyssel Dimorfizminin ve Homotipik Varyasyonlarının Morfometrik Olarak İncelenmesi

Özet: Bu çalışmada, Morkaraman koyunlarında ossicula auditus'u oluşturan kemiklerin morfometrik özelliklerinin belirlenmesi, cinsiyetler ve yönler arasındaki farklılıkların ortaya konulması amaçlanmıştır. Bu amaçla çalışmada 24 adet (12 dişi/12 erkek) Morkaraman koyunu kafatası kullanıldı. Cranium'lar maserasyona tabi tutulduktan sonra cavum tympani'deki ossicula auditus'lar diseke edildi ve doğrusal ölçümler alınarak morfometrik veriler belirlendi. Elde edilen morfometrik verilerin cinsiyete göre dimorfik yapıları ve homotipik varyasyonları istatistiksel olarak hesaplanmıştır. Ossicula auditus'u oluşturan kemiklerin sırasıyla malleus, incus ve stapes olduğu görülmüş, elde edilen morfometrik veriler analiz edildiğinde sol malleus kemikçisinde, caput mallei uzunluğu ($P<0.01$) ile malleus uzunluğu, caput mallei genişliği ve manubrium mallei uzunluğu ($P<0.001$) parametrelerinde cinsiyetler arasında istatistiksel olarak dimorfik farklılıklar olduğu tespit edildi Sağ incus kemikçisinde crus breve uzunluğu, LSC ($P<0.001$), sol incus kemikçisinde ise crus longum uzunluğu ve corpus incudis uzunluğu ($P<0.01$), crus breve uzunluğu ve corpus incudis ($P<0.001$) parametrelerinde cinsiyetler arasında istatistiksel olarak dimorfik farklılıklar olduğu belirlendi. Erkek koyunlarda malleusta caput mallei uzunluğu ($P<0.01$), malleus uzunluğu ve manubrium mallei uzunluğu ($P<0.001$), dişi koyunlarda ise incusta corpus incudis uzunluğu ($P<0.001$) parametrelerinde homotipik varyasyon tespit edilirken, diğer parametrelerde simetrik farklılık bulunmadı ($P>0.05$). Kemikçiklerin morfometrik parametrelerinin korelasyon analizinde pozitif yönde zayıf, orta ve güçlü korelasyon gözlenirken, negatif yönde sadece zayıf korelasyon gözlenmiştir. Sonuç olarak, Morkaraman koyunlarının ossicula auditus kemiklerinin morfometrik parametrelerinin belirlenmesinin taksonomik ve deneysel çalışmalara katkı sağlayacağı düşünülmektedir.

Anahtar Kelimeler: Dimorfizm, Homotipik varyasyon, Morfometri, Ossicula auditus.

Introduction

In Turkey, which is geographically divided into seven regions, many sheep breeds with different morphological and physiological characteristics can adapt to the region due to climate and geographical differences. Morkaraman sheep is a fat-tailed indigenous breed that constitutes 20% of the sheep population in Turkey. Its breeding is carried out in Turkey's North Eastern and South Eastern Anatolia regions, mostly in Eastern Anatolia (Akmaz et al., 2021; Eyduran et al., 2008).

Apart from phenotypic characteristics, the skeletal system is often used in taxonomic classification. The most frequently used part of the skeletal system is the cranium bones (Kaymakçı, 2010; Soysal et al., 2003; Yaprak et al., 2023). Discrimination based on cranium morphology is difficult due to the many intraspecific polymorphisms and intraspecific diversity seen among sheep breeds (Bärmann et al., 2013). Therefore, craniometric or geometric morphometric methods are preferred (Bernal, 2007). Morphology and morphometry reflect the contribution of phenotype and genotype in the development of species (Wehausen and Ramey, 2000).

Ossicula auditus; located dorsal to the cavum tympani in the pars petrosa of the os temporale. Between the membrane tympani and the fenestra vestibuli (in the middle ear) are located the malleus, incus, and stapes, respectively. In young animals, there may also be a separate ossicle called os lenticulare between the incus and stapes. This ossicle fuses with the incus at a later age to form the processus (proc.) lenticulare. Ossicula auditus transmits sound vibrations in the membrana tympani from the auris media to the auris interna (König and Liebich, 2022). At the same time, the bones that make up the ossicula auditus are separated from each other by the m. tensor tympani and m. stapedius muscles, balancing the high vocal pressure (Reece, 2012).

Since the sheep ear model is close to the human ear model, it is preferred in experimental audiological studies and hearing aid trials (Cordero et al., 2011; Péus et al., 2020). In our study research, it was aimed to reveal the homotypic variations and sexual dimorphism of the ossicula audits of Morkaraman sheep by morphometric analysis.

Materials and Methods

The total number of samples was calculated as 10 for each pairwise comparison and 20 in total, with an effect size of 1.4, type 1 error of 0.05 and power of 80%. A total of 24 (12 female/12 male) Morkaraman sheep heads were used, considering the bone loss that may occur during the removal of the ossicula auditus. The materials used were selected in such a way that there was no statistical difference between the sexes in terms of body weight. All materials were found to be adult during dental examination.

After maceration of the fresh craniums, pars petrosa ossis temporalis and pars tympanica ossis temporalis were separated from the head for dissection of the ossicula auditus. The ossicula auditus located in the cavum tympani was dissected through the meatus acusticus externus. The

ossicula auditus were visualized with a stereo-microscope (Nikon- SMZ-2T) and the measurements given in Table 1 and Figure 1 were taken to reveal the differences between the sexes and between the right and left ossicles. The measurement points are shown in Figure 1 (Demiraslan et al., 2015; Gürbüz et al., 2019; Kurtul et al., 2003).

Table 1. Measurement points of ossicula auditus.

Ossicula auditus	Measurement Parameters
Malleus	Malleus length (LM)
	Width of the caput mallei (WHM)
	Length of caput mallei (LHM)
Incus	Length of the manubrium mallei (LhM)
	Incus length (LI)
	Crus breve length (LSC)
	Crus longum length (LLC)
	Corpus incus length (HBI)
Stapes	Corpus incus width (WBI)
	Stapes length (LS)
	Caput stapedis width (WHS)
	Basis stapedis width (WBS)
	Crus rostrale length (LRC)
	Crus caudale length (LCC)
	Foramen intercrurale width (WIF)
Foramen intercrurale length (LIF)	

Statistical analysis: The conformity of the measurement data obtained from the bones to normal distribution was evaluated by the Shapiro-Wilk test and Histogram graph, homogeneity of variances was assessed by Levene's test, and linearity was evaluated by scatter plot. Differences between measurement levels were analyzed using One-Way Analysis of Variance, and the relationships between variables were analyzed using Pearson product-moment and Spearman rank correlation coefficients. Correlation coefficients were evaluated as 0-0.19 no relationship, 0.20-0.39 weak, 0.40-0.69 moderate, 0.70-0.89 strong and 0.90-1.00 very strong relationship (Alpar, 2018). Analyses were performed using the Jamovi v2.3 package program. The significance level was determined as $P < 0.05$.

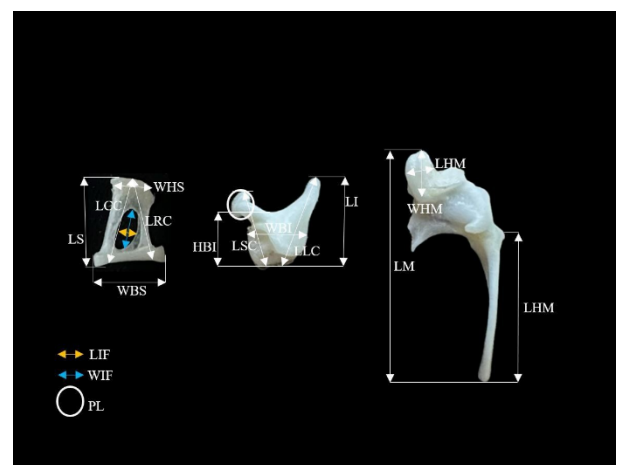


Figure 1. Measurements of the auditory ossicles. Abbreviations-see text (Table 1)

Results

It was observed that the bones forming the ossicula auditus in Morkaraman sheep were malleus, incus and stapes respectively and the os lenticulare formed the proc. lenticulare on the crus longum of the incus (Figure 1).

The morphometric data of malleus, incus and stapes and statistical analysis of these data in terms of gender and direction are given in Tables 2, 3, and 4. In the malleus measurement parameters (Table 2), there were statistically significant differences between the sexes for the left malleus

ossicle, LH, WHM and LhM at $P < 0.001$ and LHM at $P < 0.01$, whereas there was no dimorphic difference between the sexes for the right malleus ossicle ($P > 0.05$). When Table 3 was examined, it was determined that there was a significant difference between the sexes only in LSC $P < 0.001$ in the right incus ossicle. Other parameters did not show statistically dimorphic variation ($P > 0.05$). In the left incus ossicle, LLC and HBI were significantly different at $P < 0.01$, LSC and WBI were significantly different at $P < 0.001$. In the stapes ossicle, there was no statistically dimorphic difference between genders ($P > 0.05$) (Table 4).

Table 2. Descriptive statistics of malleus bone measurements (mm).

Incus		Parameters ($\bar{X} \pm S_{\bar{X}}$)			
Gender	Ear	LH (n=42)	WHM (n=44)	LHM (n=46)	LhM (n=43)
Male	Right	10.01±0.16 ^a	3.51±0.06 ^b	2.27±0.08 ^a	6.93±0.23 ^a
	Left	9.09±0.20 ^b	3.38±0.08 ^b	2.02±0.07 ^b	5.99±0.13 ^b
Female	Right	10.42±0.10 ^a	3.64±0.06 ^{ab}	2.38±0.03 ^a	6.95±0.13 ^a
	Left	10.30±0.19 ^a	3.87±0.10 ^a	2.20±0.04 ^a	6.94±0.25 ^a
Total		3.60±0.05	9.95±0.12	2.97±0.03	2.21±0.03
P value		<0.01	<0.001	<0.001	<0.01

X: Arithmetic mean; SX: Standard error; ab: Statistical difference within the same column; n: Sample size.

Table 3. Descriptive statistics of incus bone measurements (mm).

Incus		Measurements ($\bar{X} \pm S_{\bar{X}}$)				
Gender	Ear	LI (n=44)	LLC (n=44)	LSC (n=44)	HBI (n=44)	WBI (n=44)
Male	Right	3.39±0.08 ^b	3.51±0.06 ^b	2.83±0.05 ^b	2.15±0.06 ^b	2.52±0.05 ^b
	Left	3.50±0.13 ^{ab}	3.38±0.08 ^b	2.80±0.03 ^b	2.18±0.03 ^b	2.42±0.04 ^b
Female	Right	3.66±0.06 ^{ab}	3.64±0.06 ^{ab}	3.05±0.04 ^a	2.30±0.04 ^{ab}	2.55±0.04 ^b
	Left	3.80±0.05 ^a	3.87±0.10 ^a	3.15±0.05 ^a	2.49±0.11 ^a	2.76±0.04 ^a
Total		3.60±0.05	3.61±0.05	2.97±0.03	2.29±0.04	2.57±0.03
P value		<0.01	<0.01	<0.001	<0.01	<0.001

X: Arithmetic mean; SX: Standard error; ab: Statistical difference within the same column; n: Sample size.

Table 4. Descriptive statistics of stapes bone measurements (mm).

Stapes		Measurements ($\bar{X} \pm S_{\bar{X}}$) (n=40)						
Gender	Ear	LS	LLC	LRC	WHS	WBS	LIF	WIF
Male	Right	3.46±0.12	3.78±0.10	3.82±0.13	1.91±0.06	3.38±0.07	1.43±0.08	0.92±0.07
	Left	3.40±0.04	3.73±0.06	3.73±0.09	1.83±0.07	3.42±0.09	1.46±0.06	1.03±0.06
Female	Right	3.11±0.32	3.75±0.10	3.66±0.16	1.86±0.07	3.36±0.04	1.56±0.11	0.97±0.11
	Left	3.38±0.08	3.73±0.09	3.70±0.10	1.86±0.06	3.38±0.05	1.54±0.08	1.05±0.05
Total		3.34±0.09	3.75±0.04	3.73±0.06	1.87±0.03	3.38±0.03	1.50±0.04	0.99±0.04
P value		0.524	0.969	0.795	0.836	0.959	0.650	0.636

X: Arithmetic mean; SX: Standard error; ab: Statistical difference within the same column; n: Sample size.

Examining homotypic variations of male and female animals, it was determined that the malleus ossicle of male sheep had significantly different LHM ($P < 0.01$), LH, and Lhm ($P < 0.001$) values (Table 2). In the incus ossicle, it was determined that there was a statistically significant difference in the WBI parameter only in females with a value of $P < 0.001$, while the other parameters did not show

homotypic variation ($P > 0.05$). Male animals' incus ossicles showed no homotypic variance in any of the parameters that were looked at ($P < 0.05$) (Table 3). It was determined that the stapes ossicle did not show statistically homotypic variation in all parameters in male and female animals ($P > 0.05$) (Table 4).

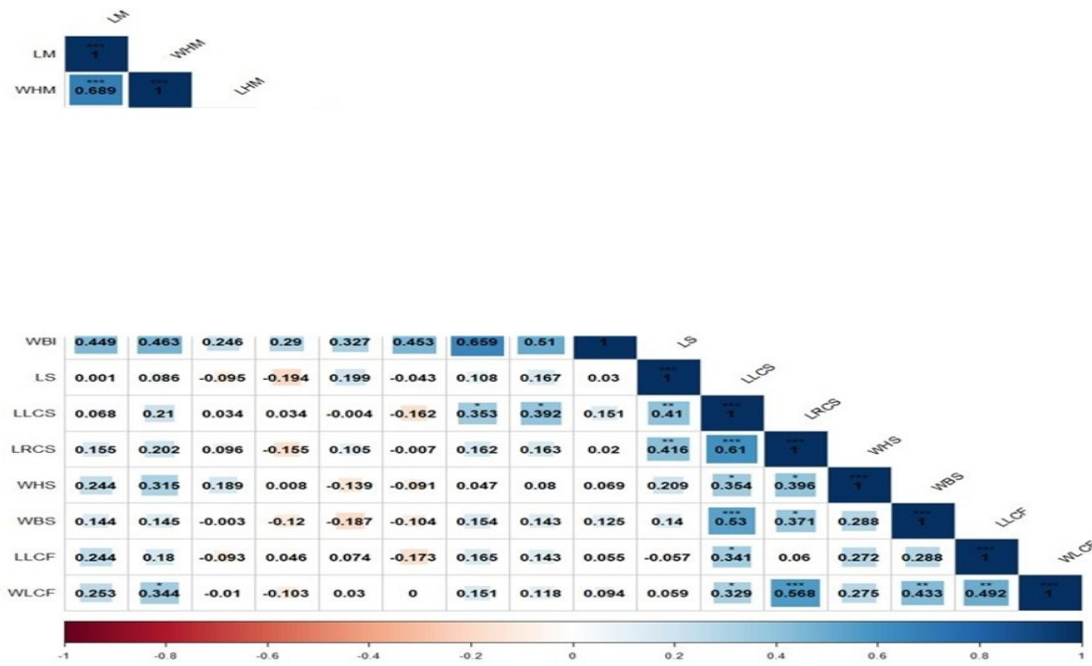


Figure 2. Correlation analysis of morphometric parameters.

The correlation analysis of the morphometric parameters of the malleus, incus and stapes forming the ossicula auditus is shown in Figure 2. The results of the correlation study showed that the ossicular parameters had weak, moderate, and strong positive relationships with one another, but only weak negative correlations.

Discussion and Conclusion

Bone morphology and morphometry have an important place in taxonomic classification and zooarchaeological studies, especially in species with high intraspecific polymorphism such as sheep (Demiraslan et al., 2024; Demircioğlu et al., 2021). In recent years, there have been morphological and morphometric studies on ossicula auditus in different animal species (Besoluk et al., 2019; Dalga & Aslan, 2019; Demiraslan et al., 2015; Gürbüz et al., 2019; Gürbüz and Demiraslan, 2023; Hadžimerović et al., 2023; Kurtul et al., 2003; Martonos et al., 2021; Stoyanov, 2020). In this study, morphometric analysis of the ossicula auditus of Morkaraman sheep was performed and homotypic variations and sexual dimorphism were investigated.

In experimental ear studies, sheep ear model has been reported as the closest animal model to humans. In particular, it was determined that the anatomical and histological structures of the sheep middle ear were significantly similar to the human ear (Cordero et al., 2011; Lavinsky et al., 1999; Seibel et al., 2006). In this study, it was observed that the ossicula auditus of Morkaraman sheep were located as malleus, incus, and stapes, respectively from outside to inside in accordance with the literature, and os lenticulare was located on incus as proc. lenticulare (Demiraslan et al., 2015; Eyduran et al., 2008; Gürbüz et al., 2019; König and Liebich, 2009; Péus et al., 2020).

The left malleus (LH, WHM and Lhm, LHM), right incus (LSC), and left incus (LLC, HBI, LSC, WBI) bones showed sexual

dimorphism in the statistical comparison of the ossicula auditus between genders. No statistically significant difference was observed between genders in the other parameters. Gürbüz et al. (2016), reported that there was a statistical difference between the incus length and corpus incudis in Malakan horses between genders. In Merkep (*Equus Asinus*) (Demiraslan et al., 2015), it was reported that the morphometric parameters of the bones forming the ossicula auditus did not show statistical dimorphism between genders.

When the homotypic variations of the bones forming the ossicula auditus were examined in the study, statistical variations were observed in the LHM, LH and Lhm parameters of the malleus ossicle of male sheep, in the WBI parameter of the female incus ossicle, while no inter-directional variation was observed in any parameter of the stapes bone. In studies conducted on different animals, male Hemşin sheep (Dalga and Aslan, 2019), Malakan horses (Gürbüz et al., 2016), and wolves (*Canis lupus*) (Gürbüz et al., 2019), it has been reported that there is no homotypic variation between ossicula auditus bones. However, it was reported that there was statistically homotypic variation between the ossicula auditus bones in the parameters of incus length, crus breve length, stapes length, basis stapedis width, and crus anterior length in merkep (*Equus asinus*) (Demiraslan et al., 2015).

In this study, the morphometric parameters of ossicula auditus of Morkaraman sheep were determined and the differences of ossicles between sexes and directions were determined. The ossicles showing differences in gender and direction were analyzed one by one and the differences and similarities were revealed. In addition, correlation analysis of the data was performed and positive and negative correlations between the data were determined. It is thought that these data will be useful in the taxonomy of species and experimental studies.

Conflict of Interest

The authors stated that they did not have any real, potential, or perceived conflict of interest.

Ethical Approval

This study is not subject to ethical permission in accordance with Article 8 (k) of the "Regulation on Working Procedures and Principles of Animal Experiments Ethics Committees". Approval document was received from Bingöl University HADYEK with E-85680299-020-169617 dated 08.08.2024.

Funding

This study was supported by Bingöl University Scientific Research Projects Unit (Project No: BAP-VF.2024.001).

Similarity Rate

We declare that the similarity rate of the article is %5 as stated in the report uploaded to the system.

Author Contributions

Motivation / Concept: FAK

Design: FAK, AK

Control/Supervision: FAK

Data Collection and/or Processing: FAK, AK

Analysis and / or Interpretation: FAK, AK

Literature Review: FAK, AK

Writing the Article: FAK, AK

Critical Review: FAK, AK

References

- Alpar R, 2018: Spor, sağlık ve eğitim bilimlerinden örneklerle uygulamalı istatistik ve geçerlik-güvenirlik [Applied statistics and validity-reliability with examples from sports, health and educational sciences]. Ankara: Detay Yayıncılık.
- Akmaz A, İnal Ş, Garip M, 2021: Zootekni – II, Küçükbaş ve Kanatlı Hayvan Yetiştiriciliği. Atlas Akademi, Konya.
- Bärmann EV, Wronski T, Lerp H, Azanaza B, Börner S, Erpenbeck D, Rössner GE, Wörheide, G, 2013: Morphometric and Genetic Framework for Gazella. *Zool J Linn Soc*, 169, 673-696.
- Bernal V, 2007: Size and shape analysis of human molars: Comparing traditional and geometric morphometric techniques". *HOMO-J. Com Hum Biol*, 58, 279–296.
- Besuluk K, Dayan MO, Eken E, Turgut N, Aydogdu S, 2019: Macroanatomic structure and morphometric analysis of middle ear in ostrich (*Struthio camelus*). *Arch Vet Sci Med*, 2(2): 8-16.
- Cordero A, del mar Medina M, Alonso A, Labatu T, 2011: Stapedectomy in sheep: An animal model for surgical training. *Otol Neurotol*, 32(5), 742–747.
- Dalga S, Aslan K, 2019: A macroanatomic and morphometric study on ossicula auditus in male Hemshin sheep. *Ataturk Univ Vet Bilim Derg*, 14(2), 114–118.

- Demiraslan Y, Gürbüz İ, Aslan K, 2015: A Macroanatomic and Morphometric Study on Auditory ossicles in Donkey (*Equus Asinus*). *İstanbul Üniv Vet Fak Derg*, 41(2), 151-154.
- Demiraslan Y, Demircioğlu İ, Güzel BC, 2024: Geometric analysis of mandible using semilandmark in Hamdani and Awassi sheep. *Ankara Üniv Vet Fak Derg*, 71(1), 1-21. <https://doi.org/10.33988/auvfd.1099535>
- Demircioğlu İ, Demiraslan Y, Gürbüz İ, Dayan MO, 2021: Geometric morphometric analysis of skull and mandible in Awassi ewe and ram. *Kafkas Üniv Vet Fak Derg*, 27(1), 43-49.
- Eyduran E, Karakus K, Keskin S, Cengiz F, 2008: Determination of factors influencing birth weight using regression tree (RT) method. *J Appl Anim Res*, 34(2), 109-112.
- Gürbüz İ, Aykut M, Dayan MO, Aslan K, 2016: Malakan atlarında ossicula auditus' un morfometrik analizi. *Eurasian J Vet Sci*, 32(4), 204-207.
- Gürbüz İ, Demiraslan Y, Dayan MO, 2019: Morphometric and macroanatomic examination of auditory ossicles in male wolves (*Canis lupus*). *Folia Morphol*, 78(3), 600–605.
- Gürbüz İ, Demiraslan Y, 2023: Geometric Morphometric Investigation of Incus in Horse (*Equus ferus caballus*) and Donkey (*Equus Asinus*). *BSJ Agri*, 6(1), 26–31.
- Hadžiomerović N, Gundemir O, Tandir F, Advic R, Katica M, 2023: Geometric and Morphometric Analysis of the Auditory Ossicles in the Red Fox (*Vulpes vulpes*). *Animals*, 13, 1230.
- Kaymakçı M, 2010: İleri Koyun Yetiştiriciliği. İzmir: Meta Basım Matbaacılık.
- König HE, Liebich HG, 2007: Veterinary Anatomy of Domestic Mammals: Textbook and Color Atlas. 3rd ed., Schattauer Co, Stuttgart.
- Kurtul I, Cevik A, Bozkurt E, Dursun N, 2003: A detailed subgross morphometric study on the auditory ossicles of the New Zealand rabbit. *Anat Histol Embryol*, 32(4), 249-252.
- Lavinsky L, Goycoolea M, Ganança MM, Zwetsch Y, 1999: Surgical Treatment of Vertigo by Utriculostomy: an Experimental Study in Sheep. *Acta Oto-Laryngologica*, 119(5), 522–527.
- Martonos CO, Gudea A, Damian A, Lăcătuș R, Purdoi R, Cocan D, Stan FG, 2021: Morphological and morphometrical aspects of the auditory ossicles in goat (*Capra hircus*). *Anat Histol Embryol*, 50(1), 184–191.
- Péus D, Dobrev I, Pffner F, Sim HJ, 2020: Comparison of sheep and human middle-ear ossicles: Anatomy and inertial properties. *J Comp Physiol*, 206, 683–700.
- Reece WO, 2012: Functional anatomy and physiology of domestic animals. Translate editors: Çöteliöğlu Ü, Özcan M. Evcil hayvanların fonksiyonel anatomisi ve fizyolojisi. Ankara: Nobel Akademik Yayıncılık, Ankara.
- Seibel VAA, Lavinsky L, De Oliveira JAP, 2006: Morphometric study of the external and middle ear anatomy in sheep: a possible model for ear experiments. *Clin Anat*, 19(6), 503-509.
- Soysal Mİ, Özkan E, Gürcan E, 2003: The status of native farm animal genetic diversity in Turkey and in the World. *Trakia J Sci*, 1, 1-12.
- Stoyanov S, 2020: Cranial variability and differentiation among golden jackals (*Canis aureus*) in Europe, Asia minor and Africa. *ZooKey*, 917, 141–164.
- Wehausen JD, Ramey RR, 2000: Cranial morphometric and evolutionary relationships in the northern range of *Ovis canadensis*. *J Mammal*, 81, 145-161.
- Yaprak A, Özgel Ö, Demiraslan Y, 2023: Geometric Morphometric Analysis of Skull in Honamlı, Hair, Kilis and Saanen Goat Using Dorsal Landmarks. *Kocatepe Vet J*, 16(1), 86-92.