



GRANULOCYTIC SARCOMA PRESENTING AS BILATERAL BREAST MASSES IN A YOUNG GIRL. CASE REPORT.

Bilateral memede kitle ile gelen genç bir bayanda görülen granülositik sarkoma. Olgu sunumu.

Palash Kumar Mandal¹, Souvik Chatterjee², Dipanwita Nag³, Manish Osta³

Departments of Pathology¹ and General Surgery², North Bengal Medical College, Darjeeling, Department of Pathology³, Medical College & Hospital, Kolkata, INDIA

Cer San D (J Surg Arts), 2013;6(2):67-69.

ABSTRACT

Granulocytic sarcoma in both breasts as the initial presentation of acute leukemia is rare. Fine needle aspiration cytology (FNAC) was initially reported as bilateral lobular carcinoma and she was undergone lumpectomy for both lumps. Biopsy was reported as poorly differentiated malignant neoplasm, favoring lobular carcinoma of both breasts. On routine work up the peripheral blood showed more than 20% of blasts, which was confirmed by bone marrow examination. Immunohistochemistry of breast biopsy was positive for anti- myeloperoxidase (MPO) but negative for Cytokeratin, CD3, CD20 and S100. We present a case of bilateral granulocytic sarcoma of breast in an 18 year old girl mimicking carcinoma of breast.

Keywords: Bilateral, breast mass, myeloid sarcoma, immunohistochemistry.

ÖZET

Akut lösemi kliniği şeklinde her iki memede birlikte granülositik sarkom görülmesi oldukça nadir bir durumdur. İğne biyopsisi ile başlangıçta lobuler karsinoma tanısı konulan ve bilateral lumpektomi yapılan hastada yapılan histopatolojik değerlendirme sonucunda öncelikle lobuler karsinomayı düşündüren kötü diferansiye tümör tanısı konuldu. Yapılan periferik kan sayımında %20' den fazla blast hücre hakimiyetinin olması nedeniyle kemik iliği biyopsisi yapıldı. Yapılan immünhistokimyasal çalışmalar sonucunda anti- myeloperoxidase (MPO) pozitif, Cytokeratin, CD3, CD20 ve S100 negatif olarak saptandı. Burada 18 yaşında bir genç kızın her iki memesinde meme kanserini taklit eden bir granülositik sarkom vakası sunuldu.

Anahtar kelimeler: Bilateral, memede kitle, miyeloid sarkom, immünhistokimya.

INTRODUCTION

Bilateral breast masses as the initial presentation of granulocytic sarcoma, in a young girl are a rare entity (1). A granulocytic sarcoma may precede or occur concurrently, or even after an acute myeloid leukemia (AML), myelodysplastic syndrome (MDS) or myeloproliferative disorder (MPD) (2,3). A high index of suspicion along with a correct panel of immunohistochemistry (IHC) is necessary for proper diagnosis and management of such cases (4).

CASE

An 18 year old female patient presented with recurrent bilateral breast masses following bilateral lumpectomy 2 months back. The masses had initially appeared 4 months before the surgery. Both the lumps were excised at a peripheral institute following a diagnosis of lobular carcinoma of breast on FNAC (Figure 1B). Biopsy was reported as poorly differentiated malignant neoplasm favoring lobular carcinoma. Clinical examination showed bilateral breast

masses of about 3.5cm in diameter each near the scar marks (Figure 1A). Both the masses were non-tender, without any discharge. The slides were reviewed. The sections showed tumor cells composed of round to polygonal cells showing mild pleomorphism, high nucleo-cytoplasmic ratio, coarse chromatin, inconspicuous nuclei and scanty cytoplasm (Figure 2A). There was no glandular differentiation, cell nests or necrosis. 'Indian file' pattern was noted focally in the tumor (Figure 2B). A diagnosis of poorly differentiated malignant neoplasm was made, differential diagnoses were; 1) Lobular carcinoma, 2) Non Hodgkin lymphoma, 3) Rhabdomyosarcoma 4)

Synovial sarcoma. On routine examination at our institute, the total blood count was $19,200/\text{cm}^3$ with 8% blasts. The bone marrow aspiration showed 60% blasts with 1-2 nucleoli and occasional Auer's rods (Fig 1C). Further hematological workup proved it to be a case of acute myeloid leukemia (ALL-M2). Cytochemistry showed strong positivity of Myeloperoxidase (MPO) in the blasts (Fig 1D). Immunohistochemistry (IHC) of the breast biopsy showed strong positivity with MPO (Fig 2C) while cytokeratin (CK), leucocyte common antigen (CD45), CD3, CD 20, Desmin, S100, and BCl2 were negative (Fig 2D).

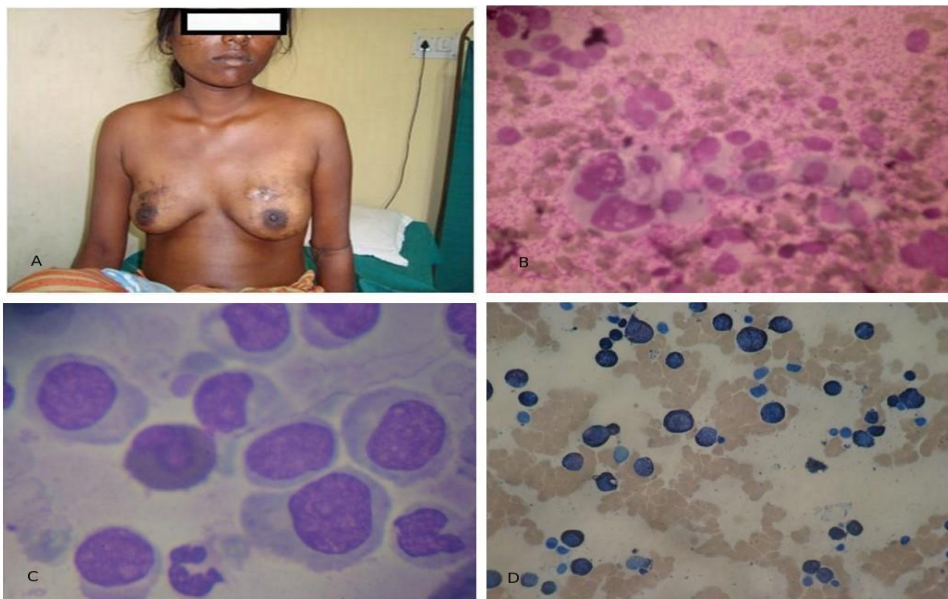


Figure 1: A) The patient, B) FNAC smears, L-G, X400, C) Bone marrow, Leishman, X1000, D) Bone marrow, MPO, X400.

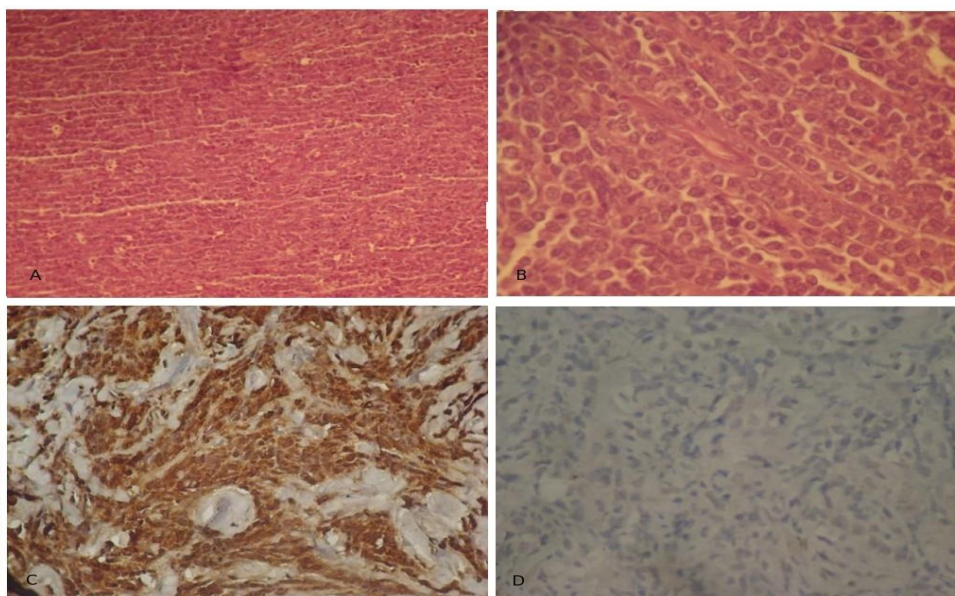


Figure 2: A) Sheets of poorly differentiated cells, H&E, X100, B) Indian file arrangement of cells, H & E, X400, C) IHC, MPO, X400, D) IHC, Cytokeratin, X200.

DISCUSSION

Granulocytic sarcoma is a neoplasm of immature granulocytes, monocytes or both involving any extramedullary site. The most common sites of involvement are bone (skull, paranasal sinuses, sternum, ribs), lymph nodes and skin, (6,7,8). Usually it occurs in patients with acute myeloid leukemia (AML), MDS or MPDs with a age range of 31-73 years (average age of 52 years)(4). In this case the patient was only 18 years old. It has been noticed that breast appears to be a site of resistant leukemia even with proper treatment; hence early detection becomes all the more important (9,10). In our case the patient had undiagnosed acute leukemia, which was only diagnosed after bilateral lumpectomy. It could be due to her lower total blood count and low peripheral blasts, which went undetected initially. Myeloid sarcoma may be confused histologically with lobular carcinoma, Non Hodgkin lymphoma, rhabdomyosarcoma, Ewing's sarcoma, melanoma etc (11,12). In this case, primary diagnosis was lobular carcinoma while on review a diagnosis of poorly differentiated malignant neoplasm was made. Granulocytic sarcoma of breast was only suspected after a thorough peripheral blood smear examination revealed the presence of blasts. IHC of the breast tissue clinched the diagnosis.

In conclusion, immunohistochemistry should be done in any neoplasm of breast where morphological diagnosis does not match the clinical picture. We want to emphasize the role of proper examination of peripheral blood, in absence of which the diagnosis was initially missed in this patient and she was injudiciously subjected to surgery.

REFERENCES

1. D'costa GF, Hastak MS, Patil YV. Granulocytic Sarcoma of breast: an aleukemic presentation. *Indian J Med Sci.* 2007;61(3):152-5.
2. Muhammad Rizwan, Md.Monirul Islam, Zia ur Rehman. Granulocytic Sarcoma of the Male Breast in Acute Myeloblastic Leukemia with Concurrent Deletion of 5q and Trisomy 8. *Case Reports in Hematology.* Volume 2012, Article ID 194312, doi:10.1155/2012/194312.
3. Joo M, Lee HK, Kang YK, Kim JH. Granulocytic Sarcoma of breast preceding acute myelogenous leukemia: a case report: *J Korean Med Sci.* 2000; 15:457-9.
4. Valbuena JR, Admirand JH, Gualco G, Medeiros LJ. Myeloid sarcoma involving breast. *Arch Pathol Lab Med.* 2005; 129(1):32-38.
5. Vela-Chávez TA, Arrecillas-Zamora MD, Quintero-Cuadra LY, and Fend F. Granulocytic sarcoma of the breast without development of bone marrow involvement: a case report. *Diagn Pathol.* 2009;4:2.
6. Paydas S, Zorludemir S, Ergin M. Granulocytic sarcoma: 32 cases and review of the literature. *Leuk Lymphoma* 2006;47(12):2527-41.

7. Raja V, Bryant B, Bessman DJ, Alperin JB. Granulocytic sarcoma presentation with nodal and skin involvement. *J Clin Oncol.* 2004;22(10):2026-7.

8. Shea B, Reddy V, Abbit P, Benda R, Douglas V and Wingard J. Granulocytic Sarcoma (Chloroma) of the breast: A diagnostic dilemma and review of literature. *Breast J.* 2004;10:48-53.

9. Cunningham IA clinical review of breast involvement in acute leukemia. *Leuk Lymphoma* 2006;47(12):2517-26.

10. Ngu IW, Sinclair EC, Greeway S, Greenberg ML. Unusual presentation of granulocytic sarcoma in the breast: A case report and review of literature. *Diag Cytopathol.* 2001; 24(1):53-7.

11. Quintas-Cardama A, Fraga M, Antual J, Forteza J: Primary extramedullary myeloid tumour of breast: a case report and review of literature. *Ann Hematol.* 2003;82(7):431-4.

12. Jelic Puskaric B, Ostojic-Kolonic S, Planinc-Peraica A, Obad-Kovacevic D, Kardum-Skelin I, Jaksic B. Myeloid sarcoma involving the breast. *Coll Antropol.* 2010;34(2):641-4.