

An overview of Extralevator Abdominoperineal Excision (ELAPE) for low rectal cancer

DİSTALDEKİ REKTAL KANSERLER İÇİN EKSTRALEVATOR ABDOMİNERİNEAL REZEKSİYON (ELAPE) TEDAVİSİ.

Bipradas Roy, Prem Varghese Thambi, Manas Kumar Roy, Sudeep Banerjee
XXXXXXX

Corresponding address: Dr. Bipradas Roy, roybipra@gmail.com

J Surg Arts (Cer San D), 2017(2):34-36.

ABSTRACT

APE for low rectal cancer is associated with high rate of tumor perforation, CRM involvement. It is well established that bowel perforation and CRM involvement are strong predictors of local recurrence and survival in rectal cancer. Extralevator Abdominoperineal Excision (ELAPE) avoids dissecting the mesorectum off the levator ani muscle and divides the levators laterally at their point of insertion to the pelvic bony-ligamentous ring. ELAPE is associated with slightly higher local complication in compare to conventional APE. A recent multicentre analysis has reported the use of ELAPE in reducing the CRM involvement and perforation rate.

Here in, ELAPE has been discussed in view of the literature.

Key words: Conventional APE, tumor perforation, local control, increased survival.

ÖZET

Abdominoperineal rezeksiyonlar (APR) sırasında tümör perforasyonu riski ve colorektal mezozonun (KRM) kirlenmesi ihtimali yüksektir. Tümörün perforasyonu ve KRM tutulumu ameliyat sonrası erken nüksün önemli bir habercisidir. Ekstrelevator APR yapılması ile KRM'nun diseksiyonu yapılmayacağı için, klasik yaklaşımda görülene göre daha az lokal nüks olduğu bilinmektedir. Konuyla ilgili olarak son zamanlarda ELAPE'nin nüksü azalttığına dair yayınlar artmaktadır.

Burada, konu literatür verileri ışığında tartışılmıştır.

Anahtar kelimeler: Klasik APR, tümör perforasyonu, lokal kontrol, artmış sağkalım.

INTRODUCTION

Since the description of total mesorectal excision (TME) by Heald et al in 1982, local control of rectal cancer and patient survival has been improved remarkably (1). Despite this, a high rate of bowel perforation, circumferential resection margin (CRM) involvement and local recurrence after abdominoperineal Excision (APE) for low rectal cancer has been reported constantly (2). Hypothetically, a wider excision would reduce these events and hence the risk of local recurrence. Anatomically mesorectum is conical in shape and the CRM is close to the bowel wall at the pelvic floor level. When performing a conventional APR, the resected specimen usually

narrows at the lower border of the mesorectum at the level just above the levator muscle where lesions are most commonly located. At this point, the CRM is often close to the rectal muscle tube. It is well established that bowel perforation and CRM involvement are strong predictors of local recurrence and survival in rectal cancer (3). Holm et al, surgeons from Stockholm have described a more radical approach to APE surgery, which closely mirrors the original Mile's operation (4).

In extralevator abdominoperineal excision (ELAPE) or cylindrical APE, the principles involve avoiding dissecting the mesorectum off the levator ani muscle and dividing the levators laterally at their point

of insertion to the pelvic bony-ligamentous ring, thus reducing the chance of breaking into tumour and

waisting of the specimen (Figure 1).

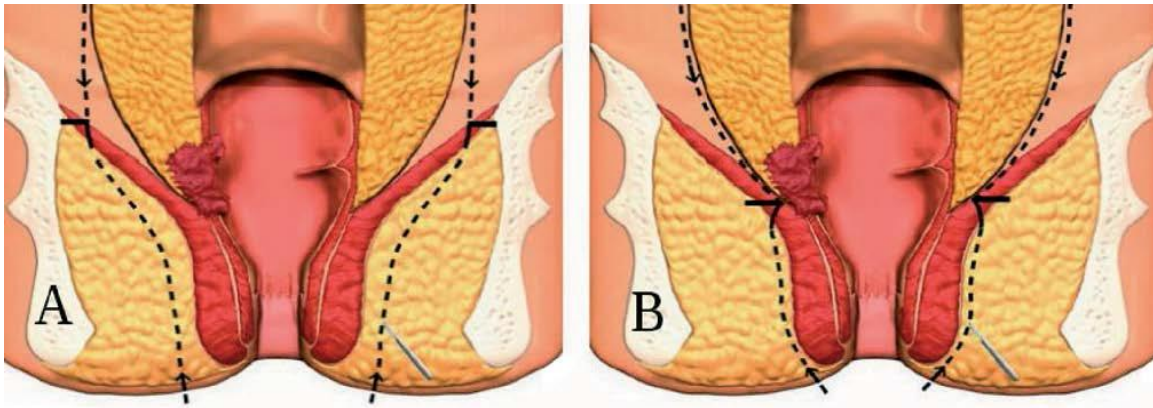


Figure 1: A) ELAPE, B) APE (Dotted lines indicate line of dissection. Horizontal lines mark where the abdominal dissection and the perineal dissection meet). (Taken from: Holm T, Ljung A, Hagmark T, et al. Extended abdominoperineal resection with gluteus maximus flap reconstruction of the pelvic floor for rectal cancer. *Br J Surg.* 2007).

Surgical technique;

The abdominal portion of the operation is performed as a conventional TME just outside the mesorectal fascia. It is essential that the dissection is not continued till the pelvic floor to prevent coning of specimen. It is to be stopped at the upper border of the coccyx posteriorly and just below the level of the seminal vesicles or cervix anteriorly. Antero-laterally the abdominal dissection is stopped just below the inferior hypogastric plexus. A medium sized swab should be placed behind the rectum to act as a guide for the perineal part of the operation.

After colostomy formation, the abdomen is closed, the patient is rotated into the jack-knife position, with the legs apart to allow the surgeon or assistant to stand between the legs. The anus is closed with a purse-string suture and an incision made close to the anus and extended to the coccyx (tear-drop shaped incision).

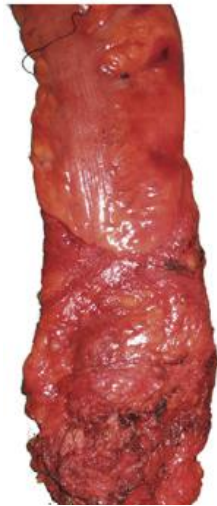The incision is deepened and dissection is continued just outside the subcutaneous portion of the external anal sphincter till we touch the inferior aspect of the levators to reach their origin on the pelvic sidewall. This is performed throughout the entire circumference of the inferior aspect of the pelvic floor. During this step, it is not recommended to take extra ischio-rectal pad of fat because it can lead to wide perineal defect. The pelvis is then entered by disarticulation of the coccyx with division of the pre-sacral fascia and then the swab placed behind the rectum should now be visible. It is possible to preserve the coccyx, but disarticulating it provides more room in which to deliver the specimen safely.

The levators are then divided at their lateral most aspect, to maximise the cuff of tissue taken. Following division of the levator ani the rectum is carefully delivered out from the pelvic cavity through the perineal wound. Once delivered it can be moved

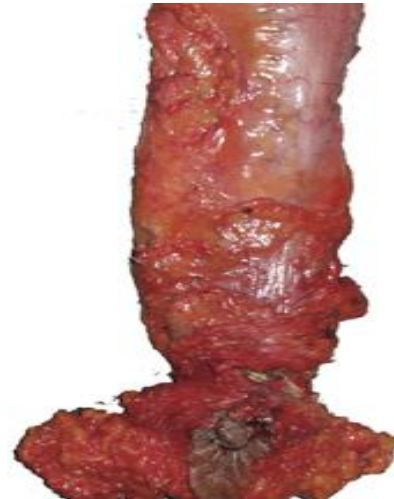laterally or inferiorly to give excellent views of the plane between the rectum and the prostate or vagina. If the tumour is invading anteriorly, the dissection is extended to take a portion of the posterior vaginal wall or back of the prostate. The final stage of the dissection is division of the anterior muscles of the pelvic floor.

The final part of the operation is to close the perineal wound. There is controversy regarding the best method for doing so. Some units prefer to use a muscle flap, particularly when the perineum has been irradiated. Other alternatives include primary closure or closure with a biological collagen mesh. But the cost of biological mesh is quite high. Other indigenous method, may be applicable for our country is to pack the perineal gap with Gelfoam sponge (absorbable gelatine) and then place a prolene mesh over it; so that small bowel cannot come into the direct contact with the prolene mesh.

It is possible to perform ELAPE in lithotomy position also but prone jack-knife position is preferred always. The lithotomy position may result in poor visualisation of the anatomy of the region which may contribute to the increased risk of perforation of the specimen and a positive resection margin. With the patient in the prone position, these hazards may be easier to avoid. Any bleeding from the prostatic bed or vaginal wall is easy to control in prone position. Perhaps the prone dissection may reduce the incidence of sexual dysfunction which is known to be higher after APE in the lithotomy position compared with low anterior resection (LAR) which may be partly related to the difficulty in visualizing the nerves in the lithotomy position. The prone position improves visualisation of the operative field and allows clear demonstration of the surgical anatomy for teaching (5).



A. Cylindrical (ELAPE) specimen



B. Conventional APE specimen

Figure 2: ELAPE and APE.

Potential complications:

Perineal wound healing is a real concern after APE surgery. Primary wound closure in irradiated perineum is associated with a 35% rate of major wound complications; double that of the non-irradiated perineum (6). The use of muscle flaps (gluteus maximus, rectus abdominis or gracilis) may help to reduce this complication. ELAPE may itself also be a risk-factor for increased perineal wound complications. In a multicentre study, it was demonstrated that ELAPE was associated with a significantly greater rate of perineal wound breakdown and herniation, despite comparable rates of the use of radiotherapy with patients having a ‘conventional’ APE (7).

DISCUSSION

A recent meta-analysis of 5 European randomized clinical trials on rectal cancer revealed that the APE procedure is a significant predictor for non radical resections and increased risk of local recurrence with decreased cancer specific survival. Whenever possible, a more radical operation should be considered for low rectal cancer. There has been increasing awareness of the need to improve the outcome of APE for low rectal cancer. A recent multicentre analysis has reported the use of ELAPE. It has reported significant reduction in the rate of margin involvement and a reduced perforation rate when compared with the ‘standard’ technique (8).

REFERENCES

1. Heald RJ, Husband EM, Ryall RD. The mesorectum in rectal cancer surgery-the clue to pelvic recurrence? *Br J Surg.* 1982;69:613-16.
2. Wibe A, Syse A, Andersen E, Tretli S, Myrvold HE, Søreide O. Oncological outcomes after total mesorectal excision for cure for cancer of the lower rectum: anterior vs. abdominoperineal resection. *Dis Colon Rectum* 2004;47:48-58.
3. Nagtegaal ID, van de Velde CJH, Marijnen CAM, van Krieken JHJM, Quirke P. Low rectal cancer: a call for a change of approach in abdominoperineal resection. *J Clin Oncol* 2005;23:9257-64.
4. Holm T, Ljung A, Ha’ggmark T, Jurell G, Lagergren J. Extended abdominoperineal resection with gluteus maximus flap reconstruction of the pelvic floor for rectal cancer. *Br J Surg* 2007;94: 232-8.
5. Mahadavan L, Veeramootoo D, Daniels I. Early results of porcine collagen membrane (Permacol) in pelvic floor reconstruction following prone cylindrical PAE. *Eur J Surg Oncol* 2008;34:1165
6. West NP, Anderin C, Smith KJ, Holm T, Quirke P. Multicentre experience with extralevator abdominoperineal excision for low rectal cancer. *The British journal of surgery* 2010;97(4):588-99.
7. West N, Anderin C, Smith K, Holm T, Quirke P. Multicentre experience with extralevator abdominoperineal excision for low rectal cancer. *Br J Surg* 2010;97:588-99.
8. Bebenek M. Abdominosacral amputation of the rectum for low rectal cancers: ten years of experience. *Annals Surg Oncol* 2009;16(8): 2211-7.