

## KORONER VE BİLATERAL KAROTİS ARTER HASTALIĞI VE RENAL FONKSİYON BOZUKLUĞU OLAN BİR HASTAYA YAKLAŞIM

### MANAGEMENT OF A PATIENT WITH CORONARY AND BILATERAL CAROTID ARTERY DISEASE, AND RENAL DYSFUNCTION

İlker KİRİŞ\*, İlker TEKİN\*\*, Berit Gökçe CEYLAN\*\*\*, Hüseyin OKUTAN\*

\* Süleyman Demirel Üniversitesi Tıp Fakültesi, Kalp ve Damar Cerrahisi Anabilim Dalı, Isparta.

\*\* Evliya Çelebi Devlet Hastanesi, Kalp ve Damar Cerrahisi, Kütahya

\*\*\* Süleyman Demirel Üniversitesi Tıp Fakültesi, Anesteziyoloji ve Reanimasyon Anabilim Dalı, Isparta.

#### Abstract

Optimal surgical management of the patients with coronary and bilateral severe carotid artery disease is difficult and controversial. Presence of renal dysfunction in these patients makes the treatment even more challenging. We performed combined right carotid endarterectomy and off-pump coronary artery bypass grafting in a patient who had concomitant coronary artery disease, chronic renal failure, severe (60%) stenosis in the right internal carotid artery and total occlusion in the left internal carotid artery. There was neither neurological complication nor haemodialysis requirement in the perioperative period. Combined carotid endarterectomy and coronary artery bypass grafting may be considered in the patients who have concomitant coronary artery disease that requiring myocardial revascularization, severe stenosis in the carotid artery and total occlusion in the contralateral carotid artery. We also think that beating heart off-pump coronary artery bypass grafting may be suitable for myocardial revascularization in the presence of preoperative renal dysfunction in these patients (Pam Med J 2008;2(2):91-94).

**Key words:** artery stenosis, coronary artery bypass surgery, renal dysfunction

#### Özet

Koroner ve bilateral ciddi karotis arter hastalığı olan hastalara ideal cerrahi yaklaşım zor ve tartışmalıdır. Bu hastalarda renal disfonksiyon varlığı tedaviyi daha da zorlaştırmaktadır. Sol internal karotis arterde total tıkanıklık ve sağ internal karotis arterde ciddi (% 60) darlık, kronik renal yetmezlik ve eşlik eden koroner arter hastalığı olan bir hastaya eş zamanlı sağ karotis endarterektomi ve 'off-pump' koroner arter baypas greftleme (KABG) operasyonu yaptık. Perioperatif dönemde nörolojik komplikasyon ya da hemodiyaliz gereksinimi olmadı. Miyokardiyal revaskularizasyon gerektiren koroner arter hastalığı ve eşlik eden karotis arterde ciddi darlık ve kontrateral karotis arterde total tıkanıklık olan hastalarda eşzamanlı karotis endarterektomi ve koroner arter baypas greftleme operasyonu yapılması düşünülebilir. Ayrıca, bu hastalarda preoperatif renal disfonksiyon olması durumunda miyokardiyal revaskularizasyon için atan kalpte 'off-pump' koroner arter baypas greftleme yapılmasının uygun olabileceğini düşünmekteyiz (Pam Tıp Derg 2009;2(2):91-94).

**Anahtar kelimeler:** Karotis arter darlığı, koroner arter baypas cerrahisi, renal disfonksiyon

#### Introduction

Considerable debate exists regarding the optimal treatment of the patients with concomitant coronary and carotid artery disease [1]. The incidence of coexisting coronary and carotid artery disease varies between 2% and 14% and approximately 8% of patients undergoing coronary artery bypass surgery (CABG) have a significant stenosis in an extracranial carotid artery [2]. However, bilateral severe carotid artery stenosis is rarely seen in this group of patients. Most studies have identified that patients requiring coronary artery revascularization who have concomitant bilateral asymptomatic or symptomatic carotid disease

are the most challenging group to manage [3]. Presence of renal dysfunction makes treatment of these patients even more challenging. Preoperative renal dysfunction is an important risk factor which is associated with significantly increased perioperative and long term mortality rates after carotid endarterectomy [4,5].

Herein we present management of a patient with coronary artery disease, chronic renal failure, and severe (60%) stenosis in the right internal carotid artery and total occlusion in the contralateral internal carotid artery.

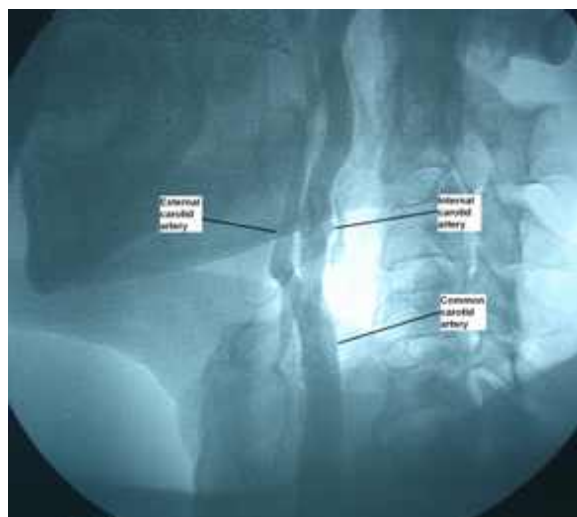
İlker KİRİŞ

Süleyman Demirel Üniversitesi Tıp Fakültesi, Kalp ve Damar Cerrahisi Anabilim Dalı, Isparta.  
e-posta: kirisilker@yahoo.com

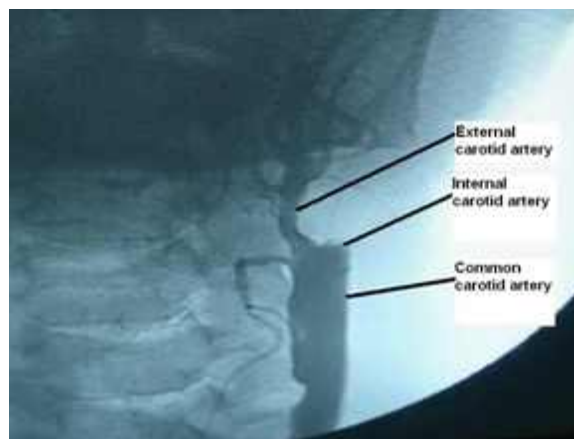
### Case Report

A 68-year-old male with chest pain was admitted to our clinic. He had symptoms of stable angina pectoris, and a history of transient ischemic attack that occurred two years ago. Results of the physical examination were normal with the exception of bilateral carotid bruits. Electrocardiography revealed negative T waves, depressed ST segments and Q waves in D1 and aVL leads. Serum level of creatine was 1.44 mg/dl and blood urea nitrogen was 46 mg/dl. Due to increased serum level of creatine, clearance of creatine was calculated and it was found 35.5 ml/min. Chronic renal failure was diagnosed by a consultation report from nephrology department.

Duplex Doppler Sonography of the bilateral carotid arteries was done due to the carotid bruits that were obtained during physical examination, and it revealed severe stenosis in the right internal carotid artery and total occlusion in the left internal carotid artery. Simultaneous carotid and coronary angiography were done by using a minimal dose of contrast agent to avoid potential toxic effects to kidneys. Coronary arteriography showed 99% stenosis in the left anterior descending (LAD) coronary artery and total occlusion in the right coronary artery. Additionally, 50% stenosis were seen in the left subclavian artery in the frame that is displaying left internal thoracic artery (LITA). Carotid arteriography showed 60% stenosis in the right internal carotid artery and total occlusion in the left internal carotid artery (Figure 1a and 1b).

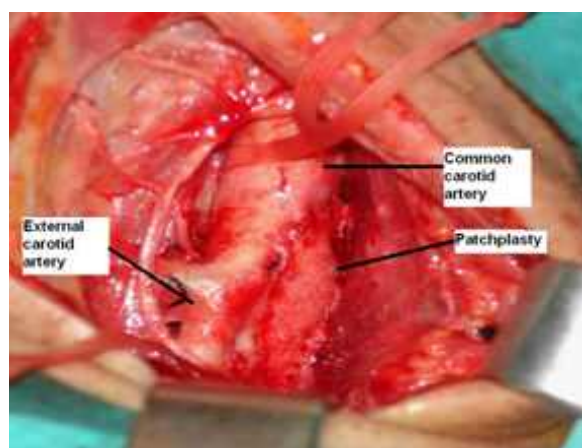


**Figure 1a.** Carotid angiogram showing 60 % stenosis in the right internal carotid artery



**Figure 1b.** Carotid angiogram showing total occlusion in the left internal carotid artery

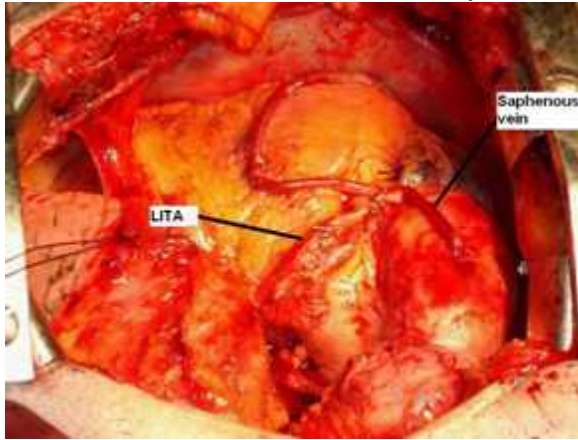
Simultaneous beating heart off-pump coronary artery bypass grafting (CABG) and right carotid endarterectomy were decided. Firstly, carotid endarterectomy was done. Following exposure of common, external and internal carotid arteries, 5000 U heparin was given and vascular clamps were placed. A longitudinal arteriotomy was initiated on the distal common carotid artery and extended into the internal carotid artery. A carotid artery shunt (Vascushunt<sup>®</sup>, Edwards Lifesciences Corp., California, USA) was used, and the distal and the proximal ends were inserted into the internal carotid artery and common carotid artery, respectively. A carotid endarterectomy was performed in the common and internal carotid artery, and the shunt was removed. Arteriotomy was closed with a patch (Acuseal cardiovascular patch<sup>®</sup>, 5 x 7 cm, Gore-Tex Inc, Arizona, USA), (Figure 2).



**Figure 2.** Intraoperative view of completed endarterectomy and patch plasty in the right internal carotid artery

Incision was covered with gauze swabs for closing after protamin administration. A median sternotomy was done, and LITA and a saphenous vein were harvested as a graft.

Heparin was given and an activated clotting time between 300 and 350 sec was established. It was decided to use LITA as a free graft due to 50% stenosis in the left subclavian artery. Proximal end of the LITA was cut and anastomosed to the saphenous vein in an end-to-side fashion. A side clamp was placed to ascending aorta and proximal anastomosis of saphenous vein to ascending aorta was done. With the aid of a cardiac stabilizer system (Octopus® 3 tissue stabilizer, Medtronic Inc, Mineapolis, USA), firstly LITA-LAD anastomosis and then saphenous vein-right coronary artery posterior descending branch anastomosis were done respectively (Figure 3). Protamin was given, drains were placed, and sternotomy and neck incision was closed simultaneously.



**Figure 3.** Intraoperative view of completed coronary artery bypass

The patient neither had neurological event nor required haemodialysis in the perioperative period. He was discharged on the postoperative seventh day in a good health condition.

### Discussion

Coexistence of carotid and coronary artery disease represents a critical clinical scenario because revascularization operations are associated with increased cardiac and cerebrovascular complication rates in these patients. Most of these patients have unilateral carotid artery stenosis and only a small number of them have bilateral symptomatic or severe carotid artery stenosis. The risk of stroke in CABG patients with bilateral hemodynamically significant carotid artery stenosis could be considerably higher [3] and treatment of these patients is challenging. Our patient had coronary artery disease that requires CABG, and bilateral hemodynamically significant carotid artery stenosis.

Simultaneous carotid and cardiac surgery has been considered more frequently in recent years as the preferred approach compared to staged

operations in the patients who have bilateral severe carotid artery stenosis and coronary artery disease that requires CABG [6]. Yapıcı et al. [7] reported that, combined interventions of carotid endarterectomy and CABG could be performed with an acceptable morbidity and mortality when severe carotid stenosis is associated with advanced, symptomatic coronary artery disease. The advantages of the simultaneous approach include decreased exposure to anesthetic drugs, shorter hospital stay, and cost savings [8]. Furthermore, combined carotid endarterectomy and CABG are the preferred approach in patients with symptomatic carotid stenosis and high-grade asymptomatic disease, especially those with bilateral high-grade lesions [9]. Consistent with this suggestion, we also preferred combined approach in our patient.

The risk of cerebral ischemia exists during the period of clamping internal carotid artery in carotid endarterectomy operations in the patients with severe carotid stenosis and contralateral carotid artery occlusion. Pulli et al [10] found that during carotid endarterectomy operations, the incidence of both somatosensory evoked potentials reduction and shunt insertion in the patients with contralateral carotid occlusion was significantly higher than in the patients without contralateral occlusion. Thus, we inserted a carotid shunt to achieve a safer cerebral perfusion in our patient.

In open heart surgery, extracorporeal perfusion has undesirable effects on renal functions. Renal blood flow and glomerular filtration rate decrease, and tubular damage may develop. Antunes et al [11] reported that a mild elevation of the preoperative creatinine level (1.3 – 2.0 mg/dl) increased significantly the probability of perioperative mortality, low cardiac output, haemodilysis requirement and prolonged hospital stay in the patients who underwent isolated CABG under cardiopulmonary bypass. The preoperative creatinine level was increased (1.44 mg/dl) and chronic renal failure was diagnosed in our patient. Thus, we preferred beating heart off-pump CABG for myocardial revascularization in our patient.

In conclusion, in the patients with coronary artery disease requiring CABG, and severe stenosis in one carotid artery and total occlusion in contralateral carotid artery, combined carotid endarterectomy and CABG may be considered. We also think that in the event of coexistent preoperative renal dysfunction, beating heart off-pump CABG may be the ideal approach for myocardial revascularization.

## References

1. Nwakanma L, Poonyagariyagorn HK, Bello R, Khoynezhad A, Smego D, Plestis KA. Early and late results of combined carotid endarterectomy and coronary artery bypass versus isolated coronary artery disease. *Interact Cardiovasc Thorac Surg* 2006;5:159-65.
2. Huh J, Wall MJ Jr, Soltero E. Treatment of combined coronary and carotid artery disease. *Curr Opin Cardiol* 2003;18:447-53.
3. Dylewski M, Canver CC, Chanda J, Darling RC, Shah DM. Coronary artery bypass combined with bilateral carotid endarterectomy. *Ann Thorac Surg* 2001;71:777-82.
4. Ayerdi J, Sampson LN, Deshmukh N, Farid A, Gupta SK. Carotid endarterectomy in patients with renal insufficiency: Should selection criteria be different in patients with renal insufficiency? *Vasc Surg* 2001;35:429-35.
5. Debing E, Van den Brande P. Chronic renal insufficiency and risk of early mortality in patients undergoing carotid endarterectomy. *Ann Vasc Surg* 2006;20:609-13.
6. Donatelli F, Pelenghi S, Pocar M, Moneta A, Grossi A. Combined carotid and cardiac procedures: improved results and surgical approach. *Cardiovasc Surg* 1998;6:506-10.
7. Yapıcı F, Gürer O, Enç Y, Çınar B, Güney M, et al. Combined surgery for coronary and carotid artery disease: management and results. *Turkish J Thorac Cardiovasc Surg* 2002;10:229-34.
8. Chiappini B, Dell' Amore A, Di Marco L, Di Bartolomeo R, Marinelli G. Simultaneous carotid and coronary arteries disease: staged or combined surgical approach? *J Card Surg* 2005;20:234-40.
9. Farooq MM, Reil TD, Gelabert HA, et al. Combined carotid endarterectomy and coronary bypass: a decade experience at UCLA. *Cardiovasc Surg* 2001;9:339-44.
10. Pulli R, Dorigo W, Barbanti E, et al. Carotid endarterectomy with contralateral carotid artery occlusion: is this a higher risk subgroup? *Eur J Vasc Endovasc Surg* 2002;24:63-8.
11. Antunes PE, Prieto D, Ferrao de Oliveira J, Antunes MJ. Renal dysfunction after myocardial revascularization. *Eur J Cardithorac Surg* 2004;25:597-604.