

## Repair of ruptured valsalva aneurysm through right atrium

### Sağ atriyal yaklaşımla tamir edilen rüptüre valsalva anevrizma

Adnan Taner Kurdal, Tolga Onur Badak, İhsan İşkesen, Mustafa Cerrahoğlu, Hayrettin Şirin

Celal Bayar Üniversitesi Tıp Fakültesi, Kalp ve Damar Cerrahisi AD, Manisa

#### Abstract

Rupture of sinus valsalva aneurysm is a very rare cardiac pathology. Thirty years old female patient presented with symptoms of congestive heart failure. She became symptomatic after the rupture of sinus valsalva aneurysm originating from right coronary sinus. Aneurysm sac was resected and the defect was repaired with patch through the right atrium. The treatment of ruptured sinus valsalva aneurysm is surgery. Aortotomy is usually needed for surgical exposure but in selected cases where the aneurysm is ruptured to the right atrium, isolated right atrial exposure can be performed. In case of loose atrial tissue, it is important to use healthy tissues during patch closure.

*Pam Med J 2011;4(1):31-3*

**Key words:** Sinus valsalva aneurysm, aorta, right atrium

#### Özet

Sinüs valsalva anevrizması rüptürü, nadir rastlanılan bir kardiyak patolojidir. Konjestif kalp yetmezliği bulgularıyla başvuran 30 yaşında bayan hasta sinüs valsalva anevrizması rüptürü tanısı ile ameliyat edilmiştir. Sağ koroner sinüs kaynaklı valsalva anevrizması rüptür sonrası semptomatik hale gelmişti. Anevrizma kesesi rezektü edilerek buradaki defekt sağ atriyumdan yama ile onarıldı. Sinüs valsalva anevrizması rüptürünün tedavisi cerrahidir. Cerrahi yaklaşımda aortotomi sıklıkla gerekmele birlikte sağ atriyuma rüptüre olmuş seçilmiş vakalarda, izole sağ atriyal yaklaşımla kapatılabilir. Atriyum duvarının gevşek olduğu vakalarda yama ile tamir sırasında sütürlerin sağlam dokulardan geçilmesine dikkat edilmelidir.

*Pam Tıp Derg 2011;4(1):31-3*

**Anahtar sözcükler:** Sinüs valsalva anevrizması, aorta, sağ atriyum

#### Introduction

Sinus valsalva aneurysm (SVA) is a rare cardiac pathology. It may be acquired or congenital. SVA is a tube like, thin walled lesion extending from the aorta to the cardiac chambers. The lesion is caused by separation of the aortic media from the valvular ring. It is usually seen on the right coronary sinus and usually ruptures to the right side of the heart and causes to important hemodynamic problems. It has poor prognosis if not treated properly [1,2]. We presented isolated right atrial approach for right atrial rupture of SVA.

#### Case

A 30 year old female patient presented with the complaints of tachycardia and swelling of the both feet for the last 6 months. Physical examination showed bilateral pretibial edema and hepatomegaly. A continuous 4/6 systolo-dastolic murmur at the left sternal border was heard and the patient was graded NYHA Class-II. Hematologic and biochemical laboratory tests were all in normal range. ECG showed negative T waves in inferior and anterior derivations and RBBB. Chest X-ray showed an increase of cardiothoracic index and pulmonary vascularization. Transthoracic

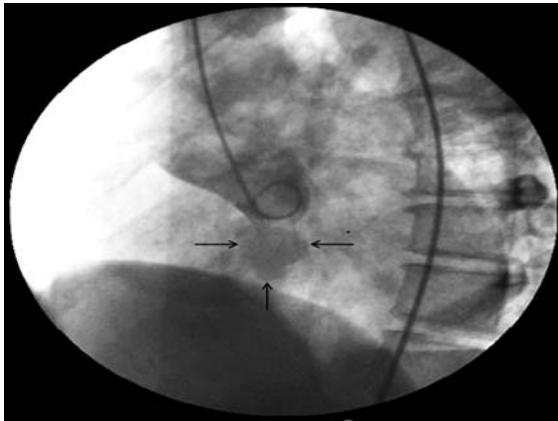
Adnan Taner KURDAL

Yazışma Adresi: Celal Bayar Üniversitesi Tıp Fakültesi, Kalp ve Damar Cerrahisi AD, Manisa  
e-mail: doktoratk@hotmail.com

Geliş tarihi : 17.10.2010

Kabul tarihi: 08.12.2010

echocardiography (TTE) was performed and a 2 cm cavitory mass originating from right coronary sinus of the aorta and extending to the right atrium through the roof of the right atrium was seen. Rupture of SVA was considered and aortography was performed. Aortography showed the passage of contrast material from the sinus valsalva aneurysm through a defect to the right atrium. Typical aortographic sign of wind sock was seen (Figure 1). The patient was operated electively.

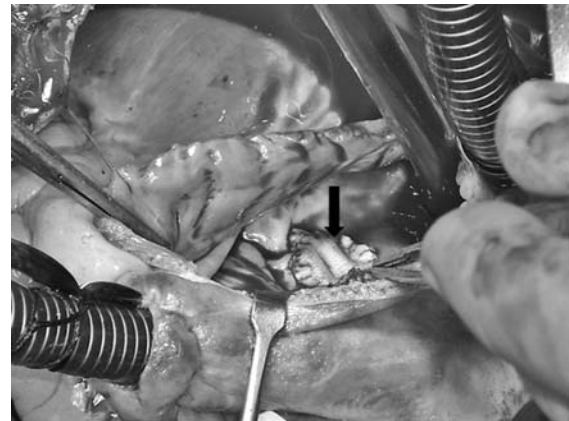


**Figure 1** . Angiographic view of congenital SVA extending from right coronary sinus to right atrium. Arrows indicate the aneurismal sac.

After sternotomy, standard cardiopulmonary bypass and moderate hypothermia with bicaval venous cannulation was performed. After cross clamping, antegrade blood cardioplegia was given for myocardial protection. Right atriotomy was performed with an oblique incision starting from 2 cm under the superior vena cava cannula under cardioplegic arrest. Smooth and thin walled aneurysm sac attached to the right atrial roof was seen (Figure 2). Aneurysm sac was resected. Tissue around the sac appeared to be very loose. After removing the sac, 0.5x0.5 cm defect was repaired with a 1x1 cm Dacron patch (Figure 3). Sutures were carefully assessed to avoid any injury to the aortic valve. Atriotomy was closed primarily. Cardiopulmonary bypass was terminated without any complication. In the postoperative period fast recovery of the patient was observed. The patient was discharged on postoperative day 7. Three months after surgery TTE follow up was performed and no defective sign except right atrial dilatation was seen. The patient was graded as NYHA Class-I.



**Figure 2** . Resection of ruptured aneurysm sac after right atriotomy. Thin arrows indicates (→) deformed right atrium wall, wide arrow indicates (⇨) SVA sac.



**Figure 3** . Repair of ruptured SVA with Dacron patch. Arrow indicates the Dacron patch.

### Discussion

SVA is a rare cardiac lesion and it has a percentage of 0.14-1.5% in all congenital heart diseases. In 76 % of the SVA cases etiology is congenital and arises from right coronary sinus most of the time [1-3]. Our case was accepted as a silent congenital aneurysm that becomes symptomatic after rupture.

Underlying reason of congenital SVA is the thinning of the aortic wall near aortic sinuses. The reason of this thinning is loss of normal elastic and muscular layers of the aortic wall. This structural abnormality is related to developmental disorder of distal bulber septum and the theory is supported by the frequent occurrence of VSD along with SVA (30-60 %) [4]. On the other hand high incidence of SVA at the right coronary sinus can be explained by

the wide areal occupation. These weak tissues become aneurysmatic in time due to high aortic pressure and the aneurysm sac tend to open to the heart chambers with lower pressure (right atrium and ventricle) [2]. These aneurysm generally occurred with ventricular septal defect (VSD) or other cardiac abnormalities [4]. In our case right coronary sinus valsalva aneurysm was present and there was no accompanying VSD.

In 25% of the cases direct aortic fistulisation may develop without sac formation [2]. In our patient typical wind sock sign was radiologically demonstrated.

Rupture of SVA develops acutely in 40% of the cases usually into the right ventricle and right atrium (totally 90%) [1,2]. Etiology of acute rupture is usually spontaneous, exercise related, traumatic or cardiac catheterization related [1]. Clinical presentation of SVAR varies depending on the size and location of the fistula. Symptoms usually appear in 4th decade after the rupture of the SVA. Because of the rupture of the aneurysm into venous structures it causes a sudden increase in venous flow and pressure. Then, aortic diastolic pressure drops dramatically. Rupture of the sac to an intracardiac region causes sudden emergence of congestive heart failure symptoms. If the aneurysm sac ruptures near A-V node or its branches, RBBB (like our patient) or total heart block symptoms may be seen [5].

Almost all of the patients who are not treated, the outcome is death. Whenever aneurysm development or rupture is discovered, the treatment is necessary [1,2,5]. Although there has been limited literature on percutaneous closure of ruptured SVA, surgery is the mainstay of therapy [1,2,5,6]. There are 3 types of surgical approach: surgical repair with aortotomy, through the related heart chambers and through the related heart chambers with aortotomy. Aortotomy is usually needed for surgical exposure but in selected cases where the aneurysm is ruptured to the right atrium, isolated right atrial exposure can be performed [2]. We selected isolated right atrial exposure in our case, because the defect was very small (0.5x0.5cm) and very close to the right coronary sinus.

There is some controversy about whether direct suture technique or patching is the best approach to close the SVAR [2]. In our case the atrial tissue around the defect was very loose. We performed the closure with a bigger patch,

in order to use healthy right atrial tissues. We carefully assessed the sutures close to the right coronary sinus and A-V node to avoid aortic valve insufficiency and atrio-ventricular block.

In conclusion, isolated right atrial approach can be used in SVAR operations in selected cases. In the presentation of loose atrial tissue, it is important to use healthy atrial tissues during patch closure.

## References

1. Moustafa S, Mookadam F, Cooper L et al. Sinus of Valsalva aneurysms-47 years of a single center experience and systematic overview of published reports. *Am J Cardiol* 2007;15;99:1159-1164.
2. Wang ZJ, Zou CW, Li DC et al. Surgical repair of sinus of Valsalva aneurysm in Asian patients. *Ann Thorac Surg.* 2007;84:156-160.
3. Takach T, Reul G, Duncan J et al. Sinus of Valsalva aneurysm or fistula: management and outcome. *Ann Thorac Surg.* 1999;68:1573-1577.
4. Sakakibara S and Konno S: Congenital aneurysm of the sinus of Valsalva, associated with ventricular septal defect. *Am Heart J* 1968;75:596-601.
5. Kırallı K, Dağlar B, Güler M et al: Ruptüre Olmuş Konjenital Sinüs Valsalva Anevrizmalarının Cerrahi Tedavisi. *GKDC Derg.* 1997; 5:248-255.
6. Mehta NK, Mishra N, Kerkar P. Percutaneous closure of ruptured sinus of valsalva aneurysm and atrial septal defect. *J Invasive Cardiol* 2010;22:82-85.