

Epithelioid trophoblastic tumor of the uterus

Uterusta nadir görülen epithelioid trofoblastik tümör

Ümit Çabuş, İlyas Turan, Erkan Alataş

Pamukkale Üniversitesi, Kadın Hastalıkları ve Doğum ABD, Denizli

Abstract

Epithelioid trophoblastic tumor (ETT) is an uncommon form of trophoblastic disease, mostly affecting reproductive age women. The histological appearance of ETT is similar to low-grade squamous cell carcinomas. In this paper, we described a woman with ETT suffering from secondary amenorrhea. Albeit at low possibility, ETT should be considered in the differential diagnosis in a patient who presented with secondary amenorrhea.

Pam Med J 2017;10(3):282-285

Keywords: Uterine Neoplasms, Trophoblastic Neoplasms, Epithelioid Trophoblastic Tumor.

Özet

Epithelioid trofoblastik tümör (ETT), genellikle üreme çağındaki kadınları etkileyen ve trofoblastik hastalıklar arasında çok nadir olarak görülen bir hastalıktır. ETT nin histolojik görünümü düşük dereceli skuamöz hücreli kanserlere benzerdir. Biz bu olgu sunumunda sekonder amenore şikayeti ile başvuran ETT tanılı bir kadın hastayı sunmayı amaçladık. Düşük ihtimal de olsa, ETT sekonder amenore ile başvuran bir hastada ayırıcı tanıda düşünülmelidir.

Pam Tıp Derg 2017;10(3):282-285

Anahtar sözcükler: Uterin kanserler, Trofoblastik hastalıklar, Epithelioid Trofoblastik Tümör.

Introduction

Epithelioid trophoblastic tumor (ETT) is an uncommon form of trophoblastic disease, mostly affecting reproductive age women [1]. The tumor is composed of intermediate trophoblast cells [2]. The histological appearance of ETT is similar to low-grade squamous cell carcinomas, which distinguishes it from placental-site trophoblastic tumor and choriocarcinoma [1,2-9]. Metastases (25%) and death (10%) have been observed even though the patients with ETT usually have a favorable outcome [3]. In this paper, we described a woman with ETT suffering from secondary amenorrhea with negative serum beta-human Chorionic Gonadotropin (β -hCG) value.

Case presentation

A 29-year-old woman, gravida 4, para 3, abortion 1, was referred to our clinic due to secondary amenorrhea for 10 months. Her past medical history revealed that she had given a birth 10 months ago. Also, she had stopped breastfeeding for 5 months. Combined abdominal and transvaginal ultrasonography

revealed a liquid collection in endometrial cavity at another health center before referring to our clinic. Also, she had undergone a cervical dilatation due to stenosis at the same clinic mentioned above. She did not respond to treatments with medroxyprogesterone acetate 10mg/day, estradiol hemihydrate 2mg/day, and combined oral contraceptive including estradiol hemihydrate 2mg + norethisterone acetate 1 mg for secondary amenorrhea. Then, she applied to our gynecology clinic. No pathological findings were found on her general physical examination. Laboratory investigations including blood count, biochemistry and urine analysis were within the normal ranges. Negative serum beta-human Chorionic Gonadotropin (β -hCG) level was determined during laboratory evaluation. We also observed a liquid collection in endometrial cavity with 35x50x75mm sized uterus by combined abdominal and transvaginal ultrasonography. The rest of uterus, recto-uterine pouch, bilateral tubes and ovaries, and other intra-abdominal organs appeared normal, except increased periuterine vascularization. Subsequently, hysteroscopy was performed. The patient was diagnosed as having moderate

Ümit Çabuş

Yazışma Adresi: Pamukkale Üniversitesi, Kadın Hastalıkları ve Doğum ABD, Denizli
e-mail: umitcabus@gmail.com

Gönderilme tarihi: 08.11.2016

Kabul tarihi: 03.04.2017

uterine synechiae by hysteroscopy, which revealed short and narrow uterine cavity with left cornual obstruction. All intrauterine adhesions were incised and some tissue sample for endometrial biopsy was taken throughout bipolar hysteroscopic resection. The postoperative course was uneventful. All tissue specimens were subjected to standard macroscopic and histological examinations. A tumoral proliferation showing the nodular development in hyalinised, fibrotic stroma was observed in histopathological examination (Figure 1). The tumor cells contained huge, pleomorphic hyperchromatic nuclei and large eosinophilic cytoplasm with indistinct cell borders. Thick-walled, hyaline vascular structures, lymphocytic infiltration and dystrophic calcifications were determined in the surrounding tissue. The numbers of mitoses per 10 standard high power fields on the microscope were 4 in the trophoblastic tumor. Also, immunohistochemical examination revealed positive staining of the tumor cells with pancytokeratin, inhibin, placental alkaline phosphates (PLAP), epithelial membrane antigen (EMA), and human chorionic gonadotropin (hCG), except human placental lactogen (HPL) (Figure 3-4). Proliferative index assessed by Ki-67 expression was around 10% (Figure 2). The pathologic diagnosis was reported as epithelioid trophoblastic tumor. Serum CA125, CA15-3 and CA19-9 levels were within the reference range in post-operative duration. Computed tomography (CT) scans of the whole abdomen, chest and pelvis were normal during follow-up. The patient was undergone the control hysteroscopy. An endometrial biopsy was simultaneously performed. The new pathologic diagnosis

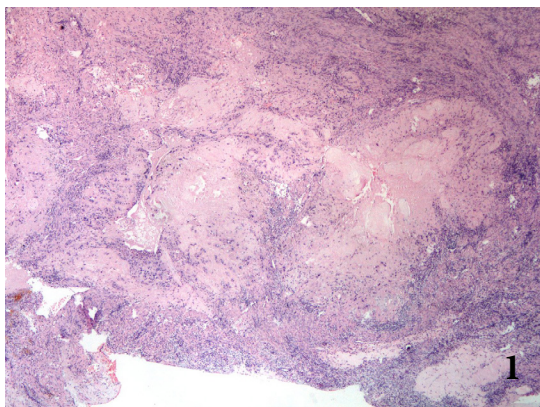


Figure 1. Nests of trophoblastic cells are surrounded by extensive necrosis and a hyaline like matrix (H&E; x40)

was defined as endocervical and myometrial tissues. A trophoblast cell population was not observed in present material. The patient was given detailed information about the current disease and treatment options. The patient did not want to have children again and preferred a radical therapy; therefore total abdominal hysterectomy was performed on the patient. Uterus and intra-abdominal washing fluid was sent to laboratory for pathological and cytological examination, respectively. The intra-abdominal fluid cytology was benign. Moreover, there was not found any residual tumor in the uterus despite of extensive sampling.

Discussion

There are few reports in the literature regarding ETT, since it was firstly described [4]. The terminology of Epithelioid Trophoblastic Tumor was listed in the latest classification of uterine corpus tumors [5]. ETT is an uncommon disorder, affecting women at reproductive age following spontaneous abortions, full-term deliveries, and hydatidiform moles [3]. Abnormal vaginal bleeding is the most common clinical symptom of ETT. During the laboratory evaluation, vaguely elevated serum β -hCG levels can be observed. It is usually located in the lower uterine segment or cervix. Also, ETT may be determined at uterine corpus, small bowel, the tonsils and the lungs [6,7-8]. ETT, especially located in lower uterine segment, can be confused with invasive squamous cell carcinoma, because it has epithelioid appearance [9]. ETT is composed of highly atypical mononucleate trophoblastic cells and syncytiotrophoblasts vaguely reminiscent of epithelioid.

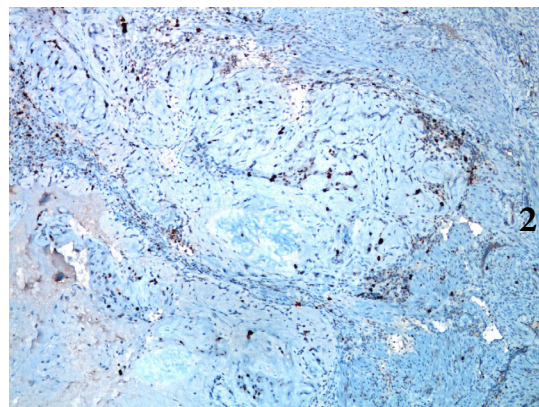


Figure 2. Ki-67 staining in tumor cells (Ki-67, x100).

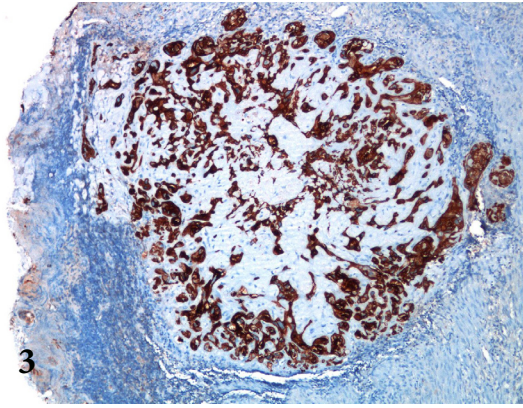


Figure 3.The tumor cells are diffusely positive for cytokeratin. (Cytokeratin, x 100)

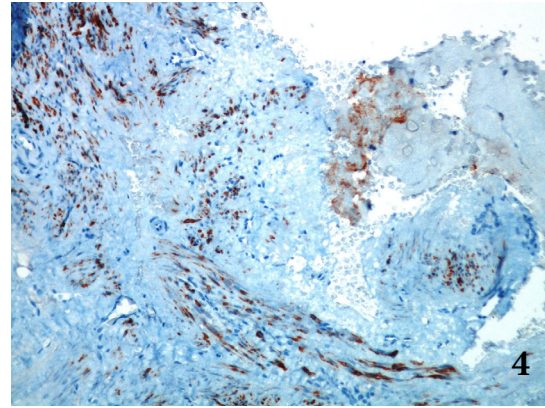


Figure 4. The tumor cells are positive for Inhibin (Inhibin, x100)

The tumor cells with eosinophilic or clear cytoplasm are characteristically arranged in nests or cords, and show nodular proliferation. A prominent necrosis can be observed in the center of tumor. Dimorphic pattern seen in choriocarcinoma is not observed in ETT. Ki-67 labeling index of ETT is significantly lower compared with choriocarcinoma. Also, decidualized stromal cells differentiating squamous cell carcinoma may be a helpful diagnostic clue.

ETT is a rare and newly defined disease. Our case was at reproductive age woman and she gave full-term delivery, previously. These data complied with general ETT diagnostic criteria, except secondary amenorrhea and negative serum β -hCG level. Although slightly higher β -hCG level can be observed in ETT cases; there was not any elevation in our patient. It may be a reason that she was in the early-stage of the disease. An additional explanation may be that there were not metastatic lesions [10].

This outcome proposes that β -hCG level may not be predictive during the early-stage of ETT. Hysteroscopy with adhesiolysis and pathological samples may be useful in early diagnosis and treatment of ETT. Based on these results, it can be said that the ETT has a wide range of symptoms and diagnosis of the disease is difficult. Albeit at low possibility, ETT should be considered in the differential diagnosis in a patient who presented with secondary amenorrhea.

Çıkar İlişkisi:Yazarlar çıkar ilişkisi olmadığını beyan eder.

References

1. Shih IM, Kurman RJ. Epithelioid trophoblastic tumor. A neoplasm distinct from choriocarcinoma and placental site trophoblastic tumor simulating carcinoma. *Am J Surg Pathol* 1998;22:1393-1403.
2. Cheung AN. Pathology of gestational trophoblastic diseases. *Best Pract Res Clin Obstet Gynaecol* 2003;17:849-868.
3. Shih IM, Kurman RJ. The pathology of intermediate trophoblastic tumors and tumor-like lesions. *Int J Gynecol Pathol* 2001;20:31-47.
4. Mazur MT. Metastatic gestational choriocarcinoma. Unusual pathologic variant following therapy. *Cancer* 1989;63:1370-1377.
5. Tavassoli FA, Devilee P. WHO: Pathology and genetics of tumours of the breast and female genital organs. Lyon: IARC Press 2003;252.
6. Ahn HY, Hoseok I, Lee CH, " et all ". Pulmonary mass diagnosed as extrauterine epithelioid trophoblastic tumor. *Thorac Cardiovasc Surg* 2013;61:97-100.
7. Scott EM, Smith AL, Desouki MM, Olawaiye AB. Epithelioid trophoblastic tumor: a case report and review of the literature. *Case Rep Obstet Gynecol* 2012;2012:862472 doi: 10.1155/2012/862472
8. Yun JS, Kim GE, Na KJ, Song SY. Combined epithelioid trophoblastic tumor and contralateral synchronous adenocarcinoma of the lungs in a 69-year-old man. *Thorac Cardiovasc Surg* 2012;60:22-44
9. Jordan S, Randall LM, Karamurzin Y, et all. Differentiating squamous cell carcinoma of the cervix and epithelioid trophoblastic tumor *Int J Gynecol Cancer* 2011;21:918-22
10. Liu Q, Shi QL, Zhang JM, et all. Epithelioid trophoblastic tumor of the uterus: a report of. *Chin Med J (Engl)* 2007;120:729-30